

# Successful Treatment of Hailey-Hailey Disease with Systemic Cyclosporine: Case Report

## Sistemik Siklosporin ile Başarılı Bir Şekilde Tedavi Edilen Bir Hailey-Hailey Hastalığı Olgusu

Gökhan ŞAHİN,<sup>a</sup>  
Nilgün ŞENTÜRK,<sup>b</sup>  
Seda KOÇ ŞAHİN<sup>c</sup>

<sup>a</sup>Clinic of Dermatology,  
Samsun Training and Research Hospital,  
Departments of  
<sup>b</sup>Dermatology,  
<sup>c</sup>Pathology,  
Ondokuz Mayıs University  
Faculty of Medicine,  
Samsun

Geliş Tarihi/Received: 23.11.2016  
Kabul Tarihi/Accepted: 28.07.2017

Yazışma Adresi/Correspondence:  
Nilgün ŞENTÜRK  
Ondokuz Mayıs University  
Faculty of Medicine,  
Department of Dermatology, Samsun,  
TURKEY/TÜRKİYE  
senturk.nilgun@gmail.com

**ABSTRACT** Hailey-Hailey disease (HHD) is a rare disease that affects the adhesion of epidermal keratinocytes. It is characterized by erosions and crustations primarily in intertriginous areas. Treatment options include topical antibiotics, antifungals, corticosteroids, dapsone, photo chemotherapy, systemic retinoids, cyclosporine, methotrexate and photodynamic therapy. Here we report a 56 years old female with refractory HHD that is successfully treated with cyclosporine. The patient had been treated with topical steroids, antifungals, antimicrobials and topical calcineurin inhibitors with limited success. Systemic treatment with methotrexate (15 mg weekly) and acitretin (25 mg daily) were also unsuccessful. Cyclosporine was started 2.5 mg/kg/day and resulted in almost complete clearance of lesions after a month. The dose of cyclosporine was reduced gradually and stopped at the end of sixth months. Topical antibiotics and topical tacrolimus were used for minor recurrences. Short course of cyclosporine can be an alternative for refractory HHD.

**Keywords:** Cyclosporine; pemphigus, benign familial; therapeutics

**ÖZET** Hailey-Hailey hastalığı (HHD) epidermal keratinositlerin adezyonunu etkileyen nadir görülen bir hastalıktır. Özellikle intertriginöz bölgelerde erozyon ve kurutlanmalarla karakterizedir. Tedavi seçenekleri topikal antibiyotikler, antifungaller, kortikosteroidler, dapson, fotokemoterapi, sistemik retinodler, siklosporin, metotreksat ve fotodinamik tedavi şeklindedir. Burada, dirençli HHD olan ve siklosporin ile başarılı bir şekilde tedavi edilen 56 yaşında bir kadın hasta sunulmaktadır. Hasta topikal steroidler, antifungal ajanlar, antibiyotikler ve topikal kalsinörin inhibitörleri ile tedavi edilmiş ama çok başarılı sonuçlar alınamamıştır. Metotreksat (15 mg/hafta) ve asitretin (25 mg/gün) tedavileri de başarılı sonuç vermemiştir. 2.5 mg/kg/gün dozda başlanan siklosporin tedavisi bir ay sonunda tam iyileşme sağlamıştır. Siklosporin dozu kademeli olarak azaltılmış ve 6 ayın sonunda kesilmiştir. Tedavinin kesilmesinden sonra ortaya çıkan küçük alevlenmeler topikal takrolimus ve topikal antibiyotikler ile kontrol altına alınmıştır. Dirençli HHD da kısa süreli siklosporin tedavisi, yüksek dozlarda ve uzun süre kullanımda toksik etkileri olabileceği için, remisyonun indüklenmesi amacıyla alternatif bir tedavi olabilir.

**Anahtar Kelimeler:** Siklosporin; pemfigus, selim ailesel; terapötikler

**B**enign familial chronic pemphigus (HHD) is a rare autosomal dominant genodermatosis characterized by development of recurrent blisters, erosions and crustations in the intertriginous areas; especially the axilla and groin. Mutations in the ATP2C1 gene which encodes a Ca<sup>2+</sup>ATPase, hSPCA1, that is located on the Golgi membrane of keratinocytes are thought to be the underlying pathology.<sup>1</sup> ATP2C1 mutations cause depletion of Ca<sup>2+</sup> in Golgi lumen which may impair processing of junctional proteins and cell to cell junctions in the stratum spinosum, which leads to epidermal acantholysis causing clinically painful, blistering lesions in high-friction areas of the body.<sup>2</sup>

Treatment alternatives include topical antibiotics, antifungals, corticosteroids and calcineurin inhibitors. In resistant cases systemic agents such as dapsone, psoralen ultraviolet A (PUVA), retinoids, cyclosporine, methotrexate and photodynamic therapy may be helpful.

## CASE REPORT

A 56-year-old female patient referred to our clinic with painful erythematous erosions in groins, axilla and infra-mammary area (Figure 1). Similar complaints have persisted for 20 years with varying severity. In the biopsy taken from the patient, acantholysis and a bulla characterized by suprabasal cleavage were seen in the epidermis. The loss of spinous processes in keratinocytes extending into the bulla has been noted. Mixed type inflammatory cell infiltration with mononuclear lymphocytes dominance accompanied by eosinophil leukocytes was observed in the peribullosous areas of the dermis and perivascular areas (Figure 2). Before applying to us, the patient used topical corticosteroids, antifungals and systemic antimicrobial agents such as terbinafine, doxycycline and itraconazole, but had no benefit. The patient remembered that there were similar lesions in her mother too. The patient was accepted as Hailey-Hailey disease with his current dermatological examination, biopsy and family history.

Earlier in the disease course the patient was given topical corticosteroids, topical and systemic antimicrobial agents in addition to general precautions such as wearing appropriate clothes to minimize friction and sweating. She was followed for six months on this regimen with no improvement. One session of fractionated CO<sub>2</sub> laser application resulted in the aggravation of lesions. Subcutaneous methotrexate 15 mg per week was added to topical therapy for 3 months without improvement and the treatment was changed to oral acitretin 25 mg per day. After treatment with acitretin for one month, her symptoms aggravated with excessive xerosis of lips, hands and feet. Acitretin was stopped and cyclosporine 2.5 mg/kg/day was started. Almost all symptoms improved within a month (Figure 3). Cyclosporine was tapered down to 1.5 mg/kg/day for maintenance for 5 months and patient remained in remission. The patient was followed up for 1 year after the cessation of systemic cyclosporine and did well on occasional topical antibiotics and topical tacrolimus for minor exacerbations (Figure 4 shows the patient's axillar and inguinal region six months after the cessation of systemic cyclosporine). Because of a major recurrence, 2,5 mg/kg/day cyclosporine was started again after a year, and lesions regressed. As a result, the use of cyclosporine in these exacerbations was seen as the best option in this case.

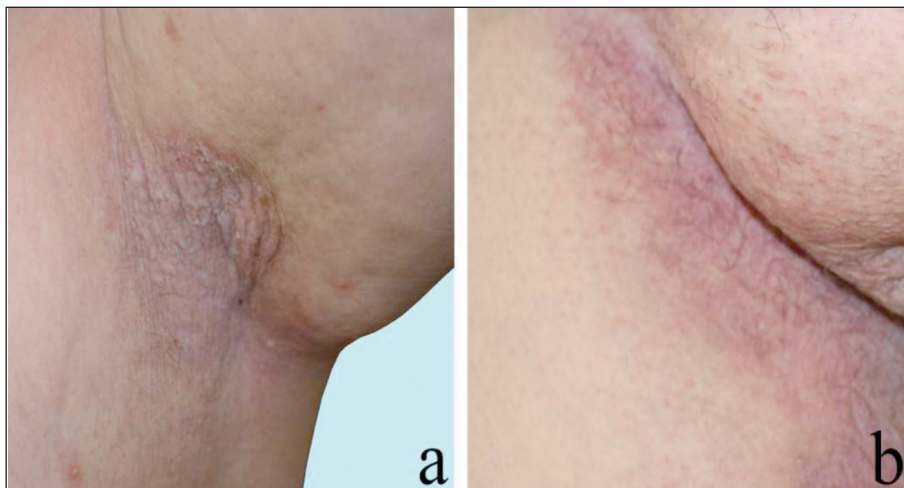


FIGURE 1: a. Axillar and b. inguinal regions before systemic cyclosporine treatment.

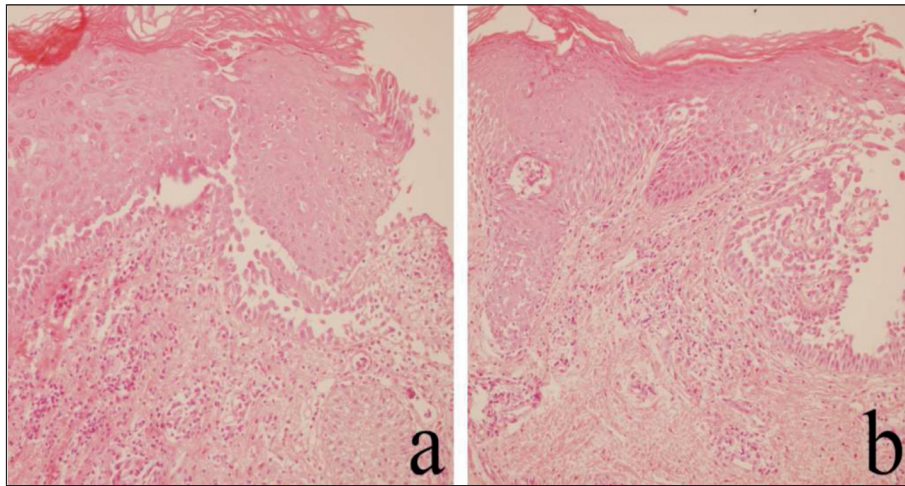


FIGURE 2: (a, b) Acantholysis and a bulla characterized by suprabasal cleavage in the epidermis (Hematoxylin and eosin, x 200).

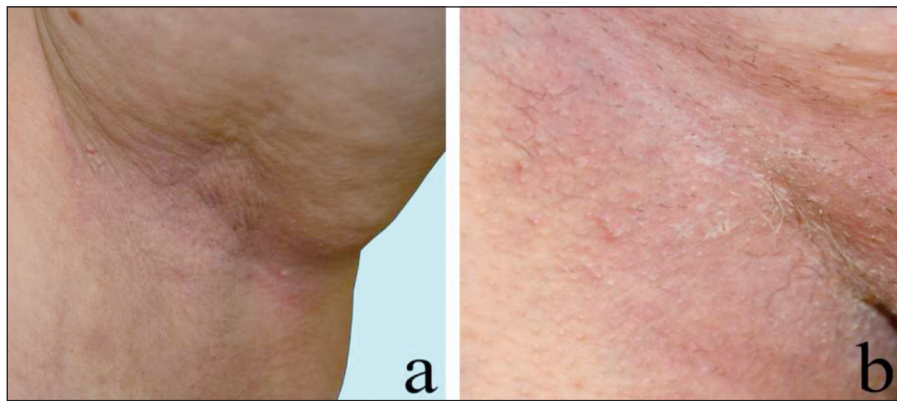

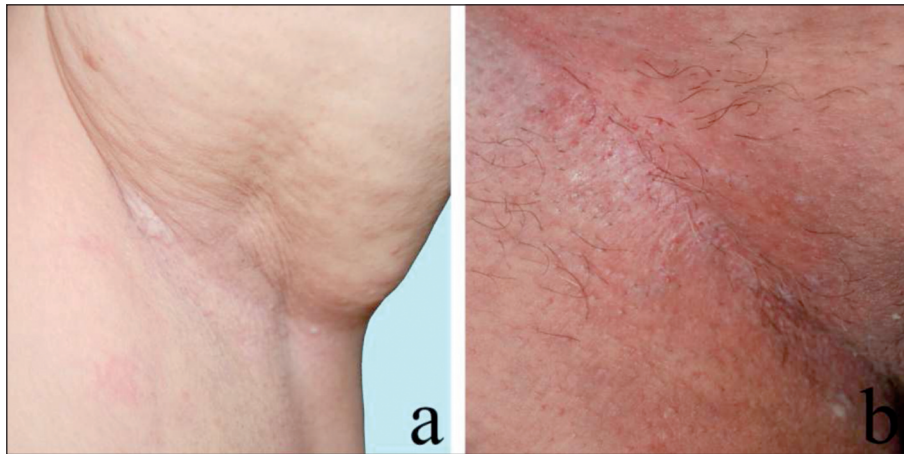
FIGURE 3: a. Axillary and b. inguinal regions one month after the initiation of systemic cyclosporine treatment.

## DISCUSSION

Lesions of HHD usually develop in the second or third decade of life; but the initial symptoms may be seen in the fourth or fifth decade. A flaccid vesicle on erythematous or normal appearing skin ensues and ruptures easily. Finally chronic, moist, malodorous vegetation and painful fissures usually develop. Friction, heat and sweating may aggravate the disease. Course of the disease is unpredictable and complete remission and flares are common. Topical and systemic antimicrobial agents may be required because secondary bacterial, fungal and viral infections play a substantial role in disease aggravation and persistence. Histopathology of HHD reveals prominent acantholysis in the suprabasil-

lary epidermis that extends towards the upper layers which is also known as “*the dilapidated brick wall appearance*”.

Treatment starts with general precautions such as wearing appropriate clothes to minimize friction and sweating. To prevent colonization and secondary bacterial, fungal and viral infections, topical and systemic antimicrobial agents should be used along with suitable cleansers. When used in early stages of the lesions, topical corticosteroids are effective in many cases.<sup>3</sup> Topical corticosteroid resistant patients may respond to intralesional injections. Case reports suggest that topical tacrolimus, 5-fluorouracil, calcitriol, tacalcitol and botulinum toxin may also be of use in terms of local therapy.<sup>1</sup> Superficial ablative techniques including



**FIGURE 4:** a. Axillary and b. inguinal regions six months later after the cessation of systemic cyclosporine.

dermabrasion, CO<sub>2</sub>-Erbium:YAG laser, photodynamic therapy with 5-ALA are equally effective and have replaced aggressive surgical approaches.<sup>4,5</sup> Some studies suggest systemic therapy with retinoids, prednisone, cyclosporine, methotrexate and dapsone can be helpful.<sup>1</sup>

The effectiveness of cyclosporine monotherapy<sup>6,8</sup> or combination<sup>2</sup> with other immunomodulatory agents in HHD has been shown in only a few cases. Dose of cyclosporine in these cases ranged between 2.5-5 mg/kg/day and time period to induce remission and relapse after discontinuation were diverse. Berth-Jones and colleagues reported a patient with severe exudation and pain attacks in the axilla and groin, despite using long-term topical 0.05% cobetasol propionate, who showed marked improvement after 16 weeks of cyclosporine at 2.8 to 3.4 mg/kg/day, but relapsed after discontinuation.<sup>6</sup> Ormerod and colleagues used slightly higher doses (5 mg/kg/day) for two patients that had previously been partial and temporary improvement in oral topical steroids, dapsone, methotrexate and PUVA treatments in whom rapid response was obtained and sustained even after the dose was lowered.<sup>7</sup> Nanda et al. reported a patient with partial healing with oral and topical antibiotics, topical antifungal, corticosteroids and dapsone treatments whose lesions completely cleared 3 weeks after starting cyclosporine at 2.5 mg/kg/day and did not relapse significantly even after discontinuation.<sup>8</sup> Varada et al. added cy-

closporine 2.8 mg/kg/day, then increased the dose to 3.8 mg/kg/day in a patient did not receive satisfactory treatment with acitretin 50 mg/day that previously used topical corticosteroids, prednisone, isotretinoin, etanercept and various antibiotics. Acitretin was reduced to 25 mg/day after that, and significant improvement was observed in the lesions of the patient at the end of the sixth month.<sup>2</sup> Since cyclosporine has well known systemic toxicity, starting with lower doses and adjusting the dose according to the clinical response is necessary.

The mechanism of action of cyclosporine in HHD pathophysiology is not well understood. It is likely that suppression of certain proinflammatory cytokine secretion and restoration of ATP2C1 mRNA levels that are increased by UVB exposure play a role.<sup>9</sup> Another theory suggests that cyclosporine plays a role in intracellular calcium regulation that may improve cell to cell adhesion in the epidermis.<sup>10</sup> Whatever the mechanism, it appears effective but relapse after discontinuation is usual.

In conclusion, we suggest that low dose cyclosporine can be considered as a rescue therapy for the treatment of refractory HHD to induce remission with a relatively short course of maintenance therapy in order to avoid toxicity related to long term use of this drug. After induction of remission, rotation to other immunomodulatory agents such as acitretin or combination with dose

sparing topicals to minimize cumulative toxicity seems logical.

### **Conflict of Interest**

*Authors declared no conflict of interest or financial support.*

### **Authorship Contributions**

**Writing Manuscript, Discussion and Supplying Resources:** Gökhan Şahin and Seda Koç Şahin; **Concept, Design, Analysis and Writing Manuscript:** Gökhan Şahin ve Nilgün Şentürk; **Critical Review:** Nilgün Şentürk.

## REFERENCES

1. Hohl D. Darier disease and Hailey-Hailey disease. In: Bologna JL, ed. *Dermatology*. 3rd ed. New York: Elsevier; 2012. p.887-97.
2. Varada S, Ramirez-Fort MK, Argobi Y, Simkin AD. Remission of refractory benign familial chronic pemphigus (hailey-hailey disease) with the addition of systemic cyclosporine. *J Cutan Med Surg* 2015;19(2):163-6.
3. Burge SM. Hailey-Hailey disease: the clinical features, response the treatment and prognosis. *Br J Dermatol* 1992;126(3):275-82.
4. Hamm H, Metze D, Bröcker EB. Hailey-Hailey disease. Eradication by dermabrasion. *Arch Dermatol* 1994;130(9):1143-9.
5. Beier C, Kaufmann R. Efficacy of erbium:YAG laser ablation in Darier disease and Hailey-Hailey disease. *Arc Dermatol* 1999;135(4):423-7.
6. Berth-Johns J, Smith SG, Graham-Brown RA. Benign familial chronic pemphigus (Hailey-Hailey disease) responds to cyclosporin. *Clin Exp Dermatol* 1995;20(1):70-2.
7. Ormerod AD, Duncan J, Stankler L. Benign familial pemphigus responsive to cyclosporin, a possible role for cellular immunity in pathogenesis. *Br J Dermatol* 1991;124(3):299-300.
8. Nanda A, Khawaja F, Harbi R, Nanda M, Dvorak R, Alsaleh QA. Benign familial pemphigus (Hailey-Hailey disease) responsive the low dose cyclosporine. *Indian J Dermatol Venerol Leprol* 2010;76(4):422-4.
9. Mayuzumi N, Ikeda S, Kawada H, Ogawa H. Effects of drugs and anticytokine antibodies on expression of ATP2A2 and ATP2C1 in cultured normal human keratinocytes. *Br J Dermatol* 2005;152(5):920-4.
10. Nicchitta CV, Kamoun M, Williamson JR. Cyclosporine augments receptor-mediated cellular Ca<sup>2+</sup> fluxes in isolated hepatocytes. *J Biol Chem* 1985;260(25):13613-8.