

# Reconstruction of the Popliteal Vasculature After a Close-Range Shotgun Injury: Case Report

## Yakın Mesafe Tüfek Yaralanması Sonrası Popliteal Damar Yapılarının Rekonstrüksiyonu

Hamit Serdar BAŞBUĞ,<sup>a</sup>  
Kanat ÖZİŞİK<sup>a</sup>

<sup>a</sup>Department of Cardiovascular Surgery,  
Kafkas University Faculty of Medicine,  
Kars

Geliş Tarihi/Received: 11.02.2016  
Kabul Tarihi/Accepted: 27.03.2016

Yazışma Adresi/Correspondence:  
Hamit Serdar BAŞBUĞ  
Kafkas University Faculty of Medicine,  
Department of Cardiovascular Surgery,  
Kars,  
TÜRKİYE/TURKEY  
s\_basbug@hotmail.com

**ABSTRACT** Popliteal penetrating firearm traumas carry a high risk of vascular, neurologic, and musculoskeletal injury with an eventual progression to limb loss. If the damage also includes the popliteal artery (PA) and the popliteal vein (PV), the morbidity and mortality further increase. Shotgun and gunshot injuries are often confused and may be used interchangeably. However, the shotgun injury is clinically and ballistically different from the gunshot injury. Furthermore, the close-range shotgun wounds may have a more severe impact than the gunshot wounds as in this case. We present the diagnostic imaging and the surgical treatment of a patient having a total cut of PA and the PV together with a massive popliteal tissue loss due to a close-range shotgun injury. In this case report, we aimed to repeat the routine methodology of the common surgical treatment in the light of new interesting figures.

**Key Words:** Popliteal artery; firearms; vascular system injuries

**ÖZET** Popliteal penetran ateşli silah travmaları, vasküler, nörolojik ve muskuloskeletal yaralanmalar açısından yüksek risk taşımakta ve ekstremitte kaybına kadar ilerleyebilmektedir. Eğer bu hasar popliteal arter (PA) ve popliteal veni (PV) de kapsıyorsa, mortalite ve morbidite daha da artar. Tüfek ve tabanca yaralanmaları sıklıkla birbirleriyle karıştırılmakta ve birbirlerinin yerine kullanılabilmektedir. Oysaki, tüfek yaralanması klinik olarak da balistik olarak da tabanca yaralanmasından çok farklıdır. Dahası, yakın mesafeden ateşlenmiş tüfek yaralanmaları, bu vakada da olduğu gibi tabancaya göre çok daha ciddi etkiye sahip olurlar. Yakın mesafe tüfek yaralanmasına bağlı masif popliteal doku kaybı ile birlikte PA ve PV de tam kesisi olan hastanın teşhis görüntülerini ve cerrahi tedavisini sunmaktayız. Bu olgu sunumunda, olağan cerrahi tedavinin rutin metodolojisinin yeni ilginç görüntülerin ışığında tekrarlanması amaçlanmıştır.

**Anahtar Kelimeler:** Popliteal arter; ateşli silahlar; vasküler sistem yaralanmaları

Türkiye Klinikleri J Cardiovasc Sci 2016;28(1):35-8

The incidence of firearm injuries among the civil population has increased sharply in many countries sometimes reaching an epidemic level. The vascular surgeons dealing with the firearm injuries should have a command of detailed knowledge and the current concepts about ballistic wounding together with the pathophysiology of fracture and soft-tissue injury.<sup>1</sup> The incidence of limb loss after the arterial injuries due to a shotgun injury often correlates with the mechanism and extent of the tissue damage. The duration of the ischemic period before revascularization and the association of venous injury or development of compartment syn-

drome also contribute the outcome.<sup>2</sup> Injuries to the popliteal artery are rare but associated with high rates of limb loss as well as high levels of mortality and morbidity.<sup>3,4</sup> The variety of presentations and wide-range of injury patterns contribute the lack of management protocols and lack of prescriptive advice on clinical approach and treatment options.<sup>1,3</sup>

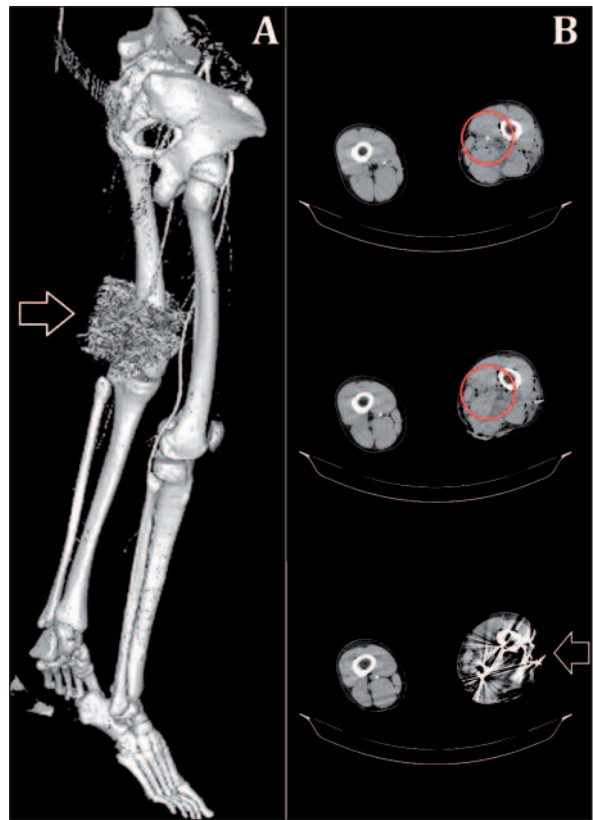
We presented a female patient with a close-range shotgun wound to her left popliteal fossa with a massive tissue loss and bleeding due to disruption of the vascular structures. Popliteal vascular structures were reconstructed, and the photos were captured during the operation. Both the pre-operative diagnostic scans and the intraoperative images were pathognomonic as they exhibited the whole surgical process and the management of trauma.

## CASE REPORT

A 32-year-old female arrived at the emergency department with a mangled left lower extremity due to a short-distance shotgun wound. She was conscious with a blood pressure of 115/65 mmHg and heart rate of 84 bpm. She had an extensive injury in her left popliteal region. Upon inspection, there were a massive dermal and musculoskeletal defect with a cluster of pellets and some fabric pieces inside the open wound of the popliteal fossa. There was a massive bleeding originating from PA and PV. Palpation of the peripheral pulses revealed a pulse deficit on her left posterior tibial artery (PTA) and anterior tibial artery (ATA).

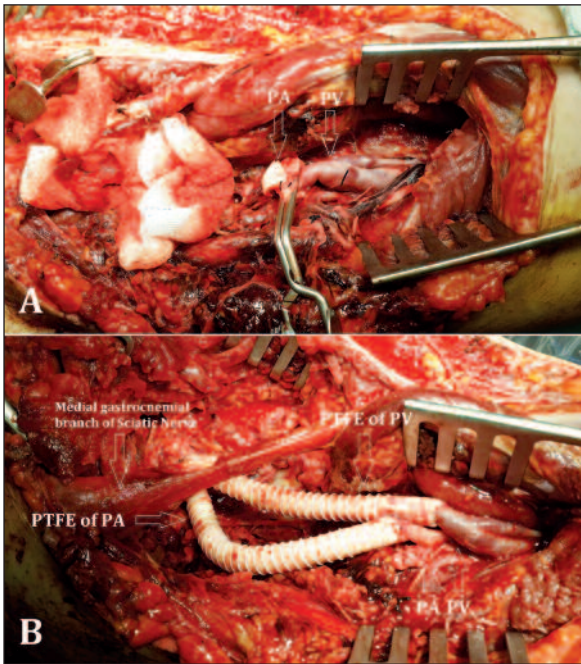
Three-dimensional reconstruction image of the Computerized Tomography (CT) Angiography views demonstrated the massive accumulation of the shotgun pellets around the knee joint (Figure 1A) Horizontal sections of the CT Angiography scan revealed the interruption of the PA at the level of popliteal fossa (Figure 1B). CT also revealed that there were no fracture in the bony structures (Figure 1).

The patient was positioned in prone position under general anesthesia. The left popliteal fossa was explored with no need of incision as it was al-



**FIGURE 1:** Computerized Tomography (CT) angiography (Three-dimensional reconstruction) is demonstrating the massive accumulation of pellets around the left knee (arrow) (A). Transverse slices of CT angiography is showing the interruption of the popliteal artery (encircled) and the cluster of pellets (arrow) (B).

ready opened due to the massive injury. A handful of pellets and some fabric pieces were removed before the extensive exploration of the wound. Thoroughly explored popliteal injury revealed a total cut of the PA with the accompanying total cut of the PV (Figure 2A). The cut edges of the PA and PV were clamped. The patient was given 5000 IU of unfractionated heparin for systemic anticoagulation. There was a massive segmental loss in both vascular structures, and they were decided to be repaired by synthetic graft interposition. The PA and PV were both repaired with an interposition of a polytetrafluoroethylene (PTFE) ringed graft (Figure 2B). Intraoperative thrombectomy was performed using a Fogarty catheter to each direction of the PA. PTA and ATA pulses were resumed intraoperatively on palpation. Diameters of the PTFE graft and the PA/PV were perfectly fitted to each other. The wound was thoroughly washed with ri-



**FIGURE 2:** Exploration of the disrupted popliteal vasculature (A). Popliteal artery (PA) and popliteal vein (PV) reconstruction with polytetrafluoroethylene (PTFE) graft interposition (B).

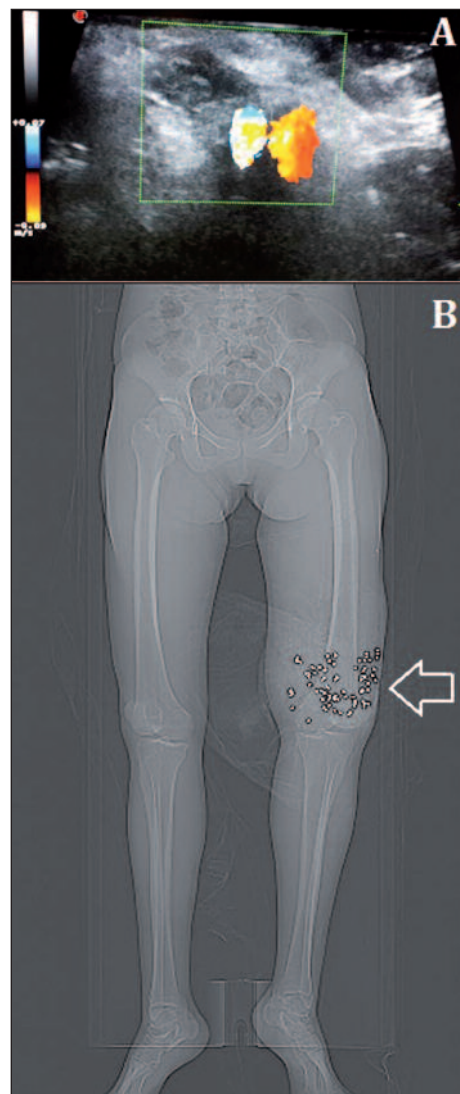
famicin solution to prevent the graft infection. Postoperative color Doppler ultrasound (DUS) examination revealed a triphasic circulation in the PA graft and monophasic circulation in the PV graft (Figure 3A). The PV graft was compressible that is an indicator of the patency. The postoperative anteroposterior plain roentgenogram showed a few residual shotgun pellets with a moderate increase in the diameter of the left thigh above the injury (Figure 3B). Ceftriaxone 3 g/day, gentamicin 160 mg/day and metronidazole 1500 mg/day were given intravenously as the antibiotherapy for ten days. The patient started to walk on the affected limb with no neurologic deficit, and she was discharged on the eleventh postoperative day with the intact grafts. Warfarin (5 mg/day) and ASA (150 mg/day) were prescribed for the protection of the grafts from thrombosis.

## DISCUSSION

The management of the peripheral vascular injuries among the civilians is a quite challenging in the western population. Because the vascular surgeons of the western world attend relatively few number

of cases in their daily practice, the management protocols are often built on the experiences of the others.<sup>5</sup> However, the peripheral vascular injuries have markedly increased in our region with a contextual shift from the blunt trauma or stab-related injuries to predominantly firearm injuries.

Primary evaluation and the management of the patient during the emergency ward period are important and should include the detailed anamnesis, physical examination with careful inspection and precise imaging. The patients should be scored with a comprehensive scoring system in all kind of



**FIGURE 3:** Postoperative Color Doppler ultrasound examination of the popliteal grafts is showing the patency (A). Postoperative plain roentgenogram is showing the remaining shotgun pellets (arrow) and the swollen left leg (B).

open traumas affecting the limbs. We always perform MESS scoring (Mangled Extremity Severity Scoring) to all patients with an upper or lower extremity injury.<sup>6</sup> This scoring system enables us to predict the possibility of amputation or the chance for salvage. Scoring also serves as a warning remark in a common language between the patient's family and the surgeon. The presence of an accompanying long bone fracture should also be evaluated.<sup>7</sup> Although some issues such as the optimum surgical sequence remain without consensus, the main purpose of the initial management should be directed to the hemostasis and reperfusion.<sup>8</sup> Repair of the fracture or displacement may be postponed until a complete revascularization is done. However, if the bone pathology has a compression effect over the artery that needs to be removed, the orthopedic intervention would be preceded.<sup>7</sup> During the surgical exploration, hemostasis should initially be constituted. Actively bleeding artery or vein not only impair the vision of surgeon but also lead a sudden blood loss, decreased blood pressure or even shock. Controlling the hemorrhage enables the surgical team to initiate the reconstruction process. The vascular structures are repaired by a simple repair, end-to-end anastomosis or with an autologous or

synthetic graft. All autologous grafts are harvested from the contralateral side veins and reversed before interposition.<sup>9</sup> In this case, PTFE grafts were chosen to facilitate the surgical process as the patient was prone positioned. The great saphenous vein (GSV) harvesting was hard to perform while the patient was lying face down. In addition to that, the diameter of the GSV did not fit the PA or PV diameter. Thus, ringed PTFE grafts were preferred in both PA and the PV reconstruction. As the wound had an extensive skin musculoskeletal tissue loss, aggressive intravenous antibiotic therapy was administered for ten days following the surgery. These patients with a tissue loss are more vulnerable to bacterial, synthetic graft infections.<sup>10</sup> If the skin wound couldn't have been closed primarily, a cutaneous graft would be needed for the closure.

As a conclusion, PA and PV injury are rare but devastating injury that may lead to limb loss, especially in patients with a high energy close-range shotgun mechanism. The initial management should be directed to the prompt revascularization. Venous autografts or synthetic grafts may be used to replace the segmental vascular defect, in which the latter have no harvesting time.

## REFERENCES

1. Bowyer GW, Rossiter ND. Management of gunshot wounds of the limbs. *J Bone Joint Surg Br* 1997;79(6):1031-6.
2. Guerrero A, Gibson K, Kralovich KA, Pipinos I, Agnostopolous P, Carter Y, et al. Limb loss following lower extremity arterial trauma: what can be done proactively? *Injury* 2002;33(9):765-9.
3. Gupta R, Quinn P, Rao S, Sleunarine K. Popliteal artery trauma. A critical appraisal of an uncommon injury. *Injury* 2001;32(5):357-61.
4. Ozisik K, Dural K, Okcu O, Han S, Yildirim E, Sakinci U. Pseudoaneurysms of the popliteal and tibioperoneal arteries after gunshot injuries. *J Trauma* 2003;55(3):485-8.
5. Hafez HM, Woolgar J, Robbs JV. Lower extremity arterial injury: results of 550 cases and review of risk factors associated with limb loss. *J Vasc Surg* 2001;33(6):1212-9.
6. Brown KV, Ramasamy A, McLeod J, Stapley S, Clasper JC. Predicting the need for early amputation in ballistic mangled extremity injuries. *J Trauma* 2009;66(4 Suppl):S93-7.
7. McHenry TP, Holcomb JB, Aoki N, Lindsey RW. Fractures with major vascular injuries from gunshot wounds: implications of surgical sequence. *J Trauma* 2002;53(4):717-21.
8. Kauvar DS, Sarfati MR, Kraiss LW. National trauma databank analysis of mortality and limb loss in isolated lower extremity vascular trauma. *J Vasc Surg* 2011;53(6):1598-603.
9. Melton SM, Croce MA, Patton JH Jr, Pritchard FE, Minard G, Kudsk KA, et al. Popliteal artery trauma. Systemic anticoagulation and intraoperative thrombolysis improves limb salvage. *Ann Surg* 1997;225(5):518-27.
10. Mullenix PS, Steele SR, Andersen CA, Starnes BW, Salim A, Martin MJ. Limb salvage and outcomes among patients with traumatic popliteal vascular injury: an analysis of the National Trauma Data Bank. *J Vasc Surg* 2006;44(1):94-100.