

Subclavian Venous Port Catheter Implantation in General Surgery: 238 Cases From a Single Center

Subklavyen Venöz Port Kateter İmplantasyonu: Tek Merkezden 238 Olguluk Genel Cerrahi Deneyimi

Osman Serhat GÜNER,^a
L. Volkan TÜMAY,^a
Abdullah ZORLUOĞLU,^a
Bülent ORHAN^b

^aClinic of General Surgery,
^bClinic of Medical Oncology,
Acıbadem Hospital, Bursa

Geliş Tarihi/Received: 12.04.2013
Kabul Tarihi/Accepted: 07.09.2013

Yazışma Adresi/Correspondence:
Osman Serhat GÜNER
Acıbadem Hospital,
Clinic of General Surgery, Bursa,
TÜRKİYE/TURKEY
serhatguner@yahoo.com

ABSTRACT Objective: In general surgery, venous port catheters (VPC) are useful for maintaining long-term parenteral nutrition and protecting the venous system from trauma due to repeated access, such as in cancer patients. However, the most common users of this technique are cardiovascular surgeons and radiologists. The most popular route for long-term central venous catheterization is the subclavian vein, although it carries a 12% rate of peri-procedural complications. The aim of this retrospective study was to investigate the early and late complications associated with percutaneous insertion of VPCs by general surgeons and to compare the complication rates with those reported in the literature. **Material and Methods:** We investigated clinical and demographical data of 238 cancer patients who underwent totally implantable, indwelling, subclavian port catheterization in our General Surgery Clinic between March 2006 and December 2009. The port catheters implanted to the patients by the two experienced surgeons, using the same technique. **Results:** One patient developed pneumothorax (0.42%) and in 4 (1.68%) patients inadvertent subclavian artery puncture was occurred. Catheter migration developed in 3 (1.26%) cases, two caused by spontaneous catheter rupture (Pinchoff Syndrome) and the other one caused by catheter disconnection. **Conclusion:** In experienced hands, percutaneous implantation of an indwelling port catheter through the subclavian vein is safe with low complications and a high success rate. Good patient monitoring and a multidisciplinary approach are important for management of any likely complications.

Key Words: Catheterization, central venous; catheters, indwelling

ÖZET Amaç: Venöz port kateter, uzun süreli parenteral nütrisyon ihtiyacı olan ve kanser hastaları gibi sıkça venöz girişim yapılan hastalarda venöz sistemi travmadan korumak için kullanılan faydalı bir uygulamadır. Hastaların yaklaşık %12'sinde perioperatif komplikasyonlar ortaya çıksa da, subklavyen ven kullanımını uzun dönem santral venöz kateterizasyon için en popüler yoldur. Bu teknik sıklıkla kardiyovasküler cerrahlar ve girişimsel radyologlar tarafından uygulanmaktadır. Retrospektif çalışmamızın amacı, klinik tecrübemizi okuyucularla paylaşmak ve literatür eşliğinde gelişen erken ve geç dönem komplikasyonları irdelemektir. **Gereç ve Yöntemler:** Mart 2006- Aralık 2009 tarihleri arasında Acıbadem Bursa Hastanesi Genel Cerrahi kliniğinde total implante edilebilir kalıcı subklaviyen port kateter takılan 238 kanser hastasına ait klinik ve demografik veriler retrospektif olarak incelendi. Bu çalışmaya dahil edilen hastalara implante edilen port kateterler; bu konuda daha önceden deneyim kazanmış iki cerrah tarafından aynı teknikle yapıldı. **Bulgular:** Bir hastada pnömotoraks (% 0,42) dört hastada (%1,68) arter ponksiyonu görüldü. Üç olguda kateter migrasyonu (% 1,26), iki olguda spontan kateter rüptürü (pinch-off sendromu) ve bir olguda (%0,42) kateter diskonneksiyonu görüldü. **Sonuç:** Kalıcı port kateter takılması için perkütan teknik ile subklavyen ven kullanımı, deneyimli ellerde güvenle uygulanabilen, komplikasyon oranı düşük, başarı oranı yüksek bir tekniktir. Gelişecek komplikasyonları yönetmede iyi hasta takibi ve multidisipliner yaklaşım çok önemlidir.

Anahtar Kelimeler: Kateterizasyon, santral venöz; kateterler, kalıcı

In general surgery, venous port catheters (VPC) are useful for maintaining long-term parenteral nutrition and protecting the venous system from trauma due to repeated access, such as in cancer patients. However, the most common users of this technique are cardiovascular surgeons and radiologists.

Long-term central venous catheters were first used for parenteral nutrition in 1973.¹ Six years later, Hickman modified this catheter by increasing the diameter, after which the Hickman catheter was first utilized for chemotherapy, and venous port catheters gained popularity in the 1980s.^{2,3} Today, port catheters have become part of the clinical routine and they are used for both patients scheduled for home total parenteral nutrition (TPN) and as a means of vascular access for administering chemotherapy, fluids, and transfusions of blood and blood products to cancer patients.⁴

Central venous port catheters can be inserted by three methods: by open surgery, percutaneously, and percutaneously under ultrasound guidance; each of those has advantages and disadvantages. The catheter is usually placed in the cephalic, internal jugular, or subclavian vein. The most popular route for long-term central venous catheterization is the subclavian vein, although it carries a 12% rate for peri-procedural complications.⁵⁻⁷ The aim of this retrospective study was to investigate the early and late complications associated with percutaneous insertion of VPCs by general surgeons, and to compare the complication rates with those reported in the literature.

MATERIAL AND METHODS

We analyzed the clinical and demographical data of 238 cancer patients who underwent totally implantable, indwelling, subclavian port catheterization in the General Surgery Clinic of Acibadem Bursa Hospital, between March 2006 and December 2009. All of the neoadjuvant and/or adjuvant chemotherapy protocols for the patients included in this study were administered in the Oncology Clinic of our hospital. All patients gave

their informed consents before the surgical procedures.

The port catheters were inserted by two experienced surgeons using the same technique in an operating room under sedation (Dormicum + Fentanyl) and local anesthesia (prilocaine hydrochloride), while ensuring proper sterility. The port catheters were inserted into the subclavian vein using the Seldinger technique under fluoroscopic guidance. First, we percutaneously punctured the subclavian vein and sent the guide wire through this needle. We then dilated the tract and advanced the sheath into the vena cava. The port catheter was inserted and the sheath peeled away. Next, we created a port pocket and tunnel. This is the most important step to prevent malfunction of the catheter and the pocket space should be sufficient to create a mild curve after connection of the port and the catheter. All patients received a preoperative antibiotic prophylaxis with 1 g of cefazolin sodium.

Our preferred route for catheter implantation is the right subclavian vein, due to its shorter length. In 225 cases, we used the right subclavian vein, and in the remaining 13 the left subclavian vein was selected due to previous right thoracic surgery in three cases, radiotherapy in eight cases, and an implanted port catheter in two cases. A Chemosite (Autosuture Schweiz, Switzerland) indwelling-port catheter was used in 228 of the included patients, and the Braun Access port systems (Braun, Germany) in the remaining 13. After insertion of the catheter, the port system was washed with 100 IU/ml of heparinized fluid, which was repeated monthly.

After implantation, routine chest radiographs were taken in all patients. The patients without any complaints or complications were discharged on the same day. Chemotherapy was not administered for 24 h following catheter implantation, or longer in the case of complications.

All complications were classified as early or late. Peri-procedural complications were accepted as the early complications, whereas those arising after discharge were classified as the late compli-

cations. The study end point was considered as last outpatient follow-up date, the date of catheter extraction due to catheter-related complications, or for the patients who passed away, the date of death. Demographic data were expressed as mean \pm standard deviation and as median (minimum-maximum range).

RESULTS

We investigated data from 238 cancer patients, 129 male and 109 female patients who had their VPCs in our clinic between 2006 and 2009. Their mean age was 58 ± 11 years and the median follow-up period was 287 (12-1109) days. Age, sex, primary cancer type, operation and follow-up times are summarized in Table 1. Early and late complications are summarized in Table 2.

EARLY COMPLICATIONS

One patient developed pneumothorax (0.42%) and in four patients (1.68%) the subclavian artery was punctured. The pneumothorax was treated by tube drainage and the four cases of subclavian artery puncture were treated with 5 min pressure on the needle entrance point.

Patient's Characteristics	(%)	
Mean Age \pm SD (years)	58 \pm 11	
Male (n)	129	54,2
Female (n)	109	45,8
Primary malignancy	(n)	(%)
Colorectal cancer	102	42,9
Breast	34	14,3
Stomach	32	13,4
Lung	20	8,4
Pancreas	11	4,6
Head and neck	12	5
Gynecologic	10	4,2
Lymphoma	9	3,8
Other	8	3,4
Catheter follow-up		
Mean Operation time \pm SD (min)	22,6 \pm 2,1	
Follow-up time (median days, (range))	287 (12-1109)	

SD: Standard deviation.

TABLE 2: Complications.

Early term complications	(n)	(%)
Arterial puncture	4	1,7
Pneumothorax	1	0,4
Total	5	2,0
Late complications	(n)	(%)
Port-related sepsis	3	1,3
Malposition	3	1,3
Migration	3	1,3
Catheter rupture	2	0,8
Catheter disconnection	1	0,4
Extravasation	4	1,7
Vascular occlusion	4	1,7
SVCS	2	0,8
Subclavian ven thrombosis	2	0,8
Fibrine sleeve	22	9,2
Total	39	16,4

SVCS: Superior vena cava syndrome.

LATE COMPLICATIONS

In two cases (0.84%) with lung and rectal cancer, symptoms such as erythema, facial swelling, and shortness of breath were observed 7-10 days after catheter insertion. Superior vena cava thrombosis was detected on thorax computerized tomography (CT). Both cases were deemed as having Superior Vena Cava Syndrome (SVCS) and the catheters were removed. Then, by interventional radiology, a stent was implanted in one of the patients and balloon dilation was applied in the other. In three patients receiving chemotherapy, there was no blood return from the catheters and on chest radiographs displacement of the catheter tip into the right jugular vein was detected. These malpositions were corrected in the operation room under fluroscopy. The displaced catheter tips were retracted to the subclavian vein, after which a new catheter was placed using a guide wire passed through the old catheter, without requiring a new puncture. Two other patients developed venous thrombosis of the subclavian vein. In both cases, anticoagulant therapy was initiated after catheter extraction.

Catheter migration occurred in three cases (1.26%), two caused by spontaneous catheter rup-

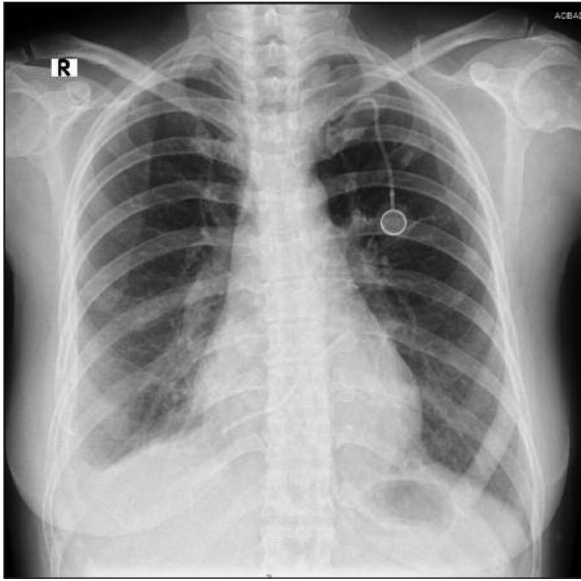


FIGURE 1: Pinch-off syndrome.

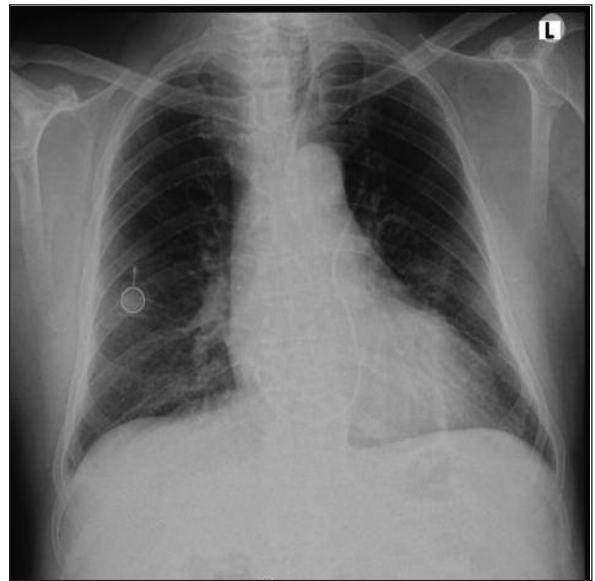


FIGURE 2: Disconnection.

ture (Pinchoff Syndrome) and one by catheter disconnection (Figures 1, 2). The diagnosis of migration was made by thoracic radiographs taken due to the absence of blood return from the port catheter. Venous angiography revealed that two of the catheter tips were in the right atrium while the other one reached the pulmonary artery. In each case, the catheter tips were extracted by the interventional radiology team via the percutaneous transfemoral route.

Three of our cases (1.26%) developed a port infection during the monitoring period. The infection did not resolve despite antibiotic therapy in one patient with port pocket infection, the infected port was removed. In the remaining two cases, the port catheters were removed due to catheter associated infections.

In 22 cases (9.2%) blood return from the catheter was absent, and thoracic radiographs were taken to rule out port dislocation. Venographies of these cases with proper catheter positioning in radiographs revealed fibrin sheaths on the catheters, and occlusion was treated in 14 cases by thrombolytic therapy. The remaining eight catheters were removed. In this study, the port explanting rate was 3.4%.

DISCUSSION

Central venous port systems are important in the treatment and care of cancer and general surgery patients. Although there is no consensus on the definition of late complications in the literature, the complications that develop beyond the peri-procedural period following insertion of the catheter have been defined as late complications.⁸

Early complications of subclavian vein puncture include pneumothorax, hemothorax, air embolism, and arterial perforation.⁹ The incidence of pneumothorax in subclavian vein punctures is 1-4%. The most important factors contributing to this complication are the experience of the surgeon and the attention paid to the anatomical landmarks.¹⁰ In our series, only one case (0.42%) developed pneumothorax, which was treated by tube drainage. In four cases, an artery was punctured and 5 min of compression prevented additional morbidity.

Sakamoto et al. reported a 0.4% pneumothorax rate in 500 ultrasound-guided port catheterizations; which is the lowest rate reported to date.¹¹ Our pneumothorax rate is very close to the lowest rates reported, confirming our hypothesis

that port catheters can be implanted with very low complication rates, even without ultrasound guidance, by an experienced surgeon. It is indisputable that low arterial puncture rates can be achieved with ultrasound guidance. However, in our series, arterial puncture neither caused serious complications nor prevented catheter insertion from the same side.

The incidence of catheter-associated venous thrombosis was low (1.68%) in our series. The correlation between cancer and thromboembolism increases as a result of cancer therapy and direct trauma to the vein, depending on the long-term central venous catheter usage.¹² Thrombosis may lead to many complications, such as increased infection risk, pulmonary embolism, and post-phlebotic syndrome at the upper extremities, which will subsequently incur higher costs.¹³ In our cases, thrombophylaxis was not employed. A recent meta-analysis showed that thrombophylaxis in cancer patients with venous ports did not significantly affect the catheter-associated thrombosis or bleeding risk, or did not cause undue harm.^{14,15}

Puel et al. reported that the venous thrombosis development risk was higher with catheters inserted from the right side, primarily due to damage to the vein wall.¹⁶ In our series, both cases that developed thrombosis in the superior vena cava had catheters inserted from the right side. The thrombosis that developed in the vena cava was treated with balloon dilation in one case and with anticoagulant therapy in the other. The thrombosis in the subclavian vein was treated with low-molecular-weight heparin after removal of the catheter.

Dislocation of the catheter tip has been reported in several series at a rate of 1.3 to 5.4%.^{4,17-19} Displacement usually occurs into the jugular system. It has been suggested that spontaneous catheter displacement could be due to fluctuations in intrathoracic pressure.¹⁹ Winston et al. reported brachialplexopathy following cytotoxic drug injection into a catheter that had migrated into the vertebral vein.²⁰ In cases with no blood return or

resistance to fluid infusion, it is important to verify the location of the catheter by thoracic radiography.²¹⁻²² All of the three catheter tip displacements in our series were into the right jugular vein, but no related complications were observed. The distal end of the catheter was exposed by the incision of the skin below the clavicle, and it was retracted to the subclavian vein under fluoroscopy, after which the new catheter was inserted into the right atrium through the guide wire.

Compression of the catheter between the first rib and the clavicle is called the "pinch-off sign", which has been reported at a rate of 1.1 to 5.0%, and it leads to symptoms such as resistance to infusion, discomfort under the clavicle, and swelling during infusion.^{23,24-26} Fractures at the catheter caused by biomaterial fatigue at the compression point and embolism by the fractured particles occur at a rate of 1.0 to 2.2%.²⁷⁻²⁹ Regular thorax radiographs taken after catheter insertion help to check for compression. A more lateral site for subclavian vein puncture is recommended to reduce the risk of pinch-off syndrome.²⁴ In our series, pinch-off syndrome and related catheter rupture occurred in two cases (0.84%).

Displacement of the catheter by disconnecting from the port chamber is a rare (0.1 to 2.0%) complication. Its occurrence rate has decreased gradually after the improvement in safely locking catheter and port systems.^{24,28,30,31} Gently washing the catheter with a 10-ml syringe is especially recommended, since smaller syringes could increase the risk of disconnecting the catheter and the port chamber through higher pressure.^{21,32-34} In our series, the only case (0.42%) with catheter and port disconnection was one of the first 10 cases during the learning period for this novel technique.

In the three cases with catheter rupture and disconnection, the ruptured and disconnected catheter parts were extracted by an interventional radiology team via the femoral vein.

Port catheter malfunction is a decrease in the capacity of fluid infusion and blood withdrawal through the catheter. It usually results from kink-

ing of the catheter, fibrin sheath formation, clogging of the lumen by blood clots, precipitation of administered drugs and fluids, abutment of the catheter tip onto the vessel wall, or disconnection of the catheter. The incidence of catheter malfunction has been reported as 0.8 to 5%.^{29,31} The most common type of catheter malfunction is difficulty in blood withdrawal without resistance to infusion. It likely results from a fibrin sheath, which functions as a unidirectional flap valve at the catheter tip.³⁵ In our series, 22 patients (9.2%) had catheter malfunctions, likely due to subcutaneous kinking of the catheter out of its normal axis after port implantation.

CONCLUSION

When performed in experienced hands, percutaneous implantation of an indwelling port catheter through the subclavian vein is safe with a low complication and a high success rate. Additionally, ultrasound is not required for port placement. Good patient monitoring and a multidisciplinary approach are important for management of any likely complications.

We believe that general surgeons should consider the advantages of port catheter implantation post-operatively, especially for administration of chemotherapy.

REFERENCES

1. Broviac JW, Cole JJ, Scribner BH. A silicone rubber atrial catheter for prolonged parenteral alimentation. *Surg Gynecol Obstet* 1973;136(4):602-6.
2. Hickman RO, Buckner CD, Clift RA, Sanders JE, Stewart P, Thomas ED. A modified right atrial catheter for access to the venous system in marrow transplant recipients. *Surg Gynecol Obstet* 1979;148(6):871-5.
3. Niederhuber JE, Ensminger W, Gyves JW, Liepman M, Doan K, Cozzi E. Totally implanted venous and arterial access system to replace external catheters in cancer treatment. *Surgery* 1982;92(4):706-12.
4. Torramadé JR, Cienfuegos JA, Hernández JL, Pardo F, Benito C, González J, et al. The complications of central venous access systems: a study of 218 patients. *Eur J Surg* 1993;159(6-7):323-7.
5. Merrer J, De Jonghe B, Golliot F, Lefrant JY, Raffy B, Barre E, et al.; French Catheter Study Group in Intensive Care. Complications of femoral and subclavian venous catheterization in critically ill patients: a randomized controlled trial. *JAMA* 2001;286(6):700-7.
6. Sznajder JL, Zvebil FR, Bitterman H, Weiner P, Bursztein S. Central vein catheterization. Failure and complication rates by three percutaneous approaches. *Arch Intern Med* 1986;146(2):259-61.
7. Mansfield PF, Hohn DC, Fornage BD, Gregurich MA, Ota DM. Complications and failures of subclavian-vein catheterization. *N Engl J Med* 1994;331(26):1735-8.
8. Biffi R, Orsi F, Pozzi S, Pace U, Bonomo G, Monfardini L, et al. Best choice of central venous insertion site for the prevention of catheter-related complications in adult patients who need cancer therapy: a randomized trial. *Ann Oncol* 2009;20(5):935-40.
9. Teichgräber UK, Gebauer B, Benter T, Wagner J. [Long-term central venous lines and their complications]. *Rofo* 2004;176(7):944-52.
10. Biffi R, Corrado F, de Braud F, de Lucia F, Scarpa D, Testori A, et al. Long-term, totally implantable central venous access ports connected to a Groshong catheter for chemotherapy of solid tumours: experience from 178 cases using a single type of device. *Eur J Cancer* 1997;33(8):1190-4.
11. Sakamoto N, Arai Y, Takeuchi Y, Takahashi M, Tsurusaki M, Sugimura K. Ultrasound-guided radiological placement of central venous port via the subclavian vein: a retrospective analysis of 500 cases at a single institute. *Cardiovasc Intervent Radiol* 2010;33(5):989-94.
12. Lee AY. Cancer and thromboembolic disease: pathogenic mechanisms. *Cancer Treat Rev* 2002;28(3):137-40.
13. Frank DA, Meuse J, Hirsch D, Ibrahim JG, van den Abbeele AD. The treatment and outcome of cancer patients with thromboses on central venous catheters. *J Thromb Thrombolysis* 2000;10(3):271-5.
14. Akl EA, Kamath G, Yosuico V, Kim SY, Barba M, Sperati F, et al. Thromboprophylaxis for patients with cancer and central venous catheters: a systematic review and a meta-analysis. *Cancer* 2008;112(11):2483-92.
15. Chaukiyal P, Nautiyal A, Radhakrishnan S, Singh S, Navaneethan SD. Thromboprophylaxis in cancer patients with central venous catheters. A systematic review and meta-analysis. *Thromb Haemost* 2008;99(1):38-43.
16. Puel V, Caudry M, Le Métayer P, Baste JC, Midy D, Marsault C, et al. Superior vena cava thrombosis related to catheter malposition in cancer chemotherapy given through implanted ports. *Cancer* 1993;72(7):2248-52.
17. Kock HJ, Krause U, Pietsch M, Rasfeld S, Walz MK. [Implantable catheter systems. Experiences with 1000 patients with central venous ports]. *Dtsch Med Wochenschr* 1996;121(3):47-51.
18. Brothers TE, Von Moll LK, Niederhuber JE, Roberts JA, Walker-Andrews S, Ensminger WD. Experience with subcutaneous infusion ports in three hundred patients. *Surg Gynecol Obstet* 1988;166(4):295-301.
19. Lokich JJ, Bothe A Jr, Benotti P, Moore C. Complications and management of implanted venous access catheters. *J Clin Oncol* 1985;3(5):710-7.
20. Winston CB, Wechsler RJ, Kane M. Vertebral vein migration of a long-term central venous access catheter: a cause of brachial plexopathy. *J Thorac Imaging* 1994;9(2):98-100.
21. Gebarski SS, Gebarski KS. Chemotherapy port "Twiddler's syndrome". A need for preinjection radiography. *Cancer* 1984;54(1):38-9.
22. Yazigi A, Yazbeck P, Antakly MC. [Secondary migration of a central venous catheter linked to an implantable port]. *Cah Anesthesiol* 1992;40(8):613-6.
23. Aitken DR, Minton JP. The "pinch-off sign": a warning of impending problems with permanent subclavian catheters. *Am J Surg* 1984;148(5):633-6.

24. Biffi R, de Braud F, Orsi F, Pozzi S, Mauri S, Goldhirsch A, et al. Totally implantable central venous access ports for long-term chemotherapy. A prospective study analyzing complications and costs of 333 devices with a minimum follow-up of 180 days. *Ann Oncol* 1998; 9(7):767-73.
25. Klotz HP, Schöpke W, Kohler A, Pestalozzi B, Largiadèr F. Catheter fracture: a rare complication of totally implantable subclavian venous access devices. *J Surg Oncol* 1996;62(3):222-5.
26. Martin AJ, Morris LL, Reece J, Ford WD, Cassey J, Goldblatt E. Totally implantable vascular access in treatment of cystic fibrosis. *Lancet* 1986;2(8501):293.
27. Wickham R, Purl S, Welker D. Long-term central venous catheters: issues for care. *Semin Oncol Nurs* 1992;8(2):133-47.
28. Kock HJ, Pietsch M, Krause U, Wilke H, Eigler FW. Implantable vascular access systems: experience in 1500 patients with totally implanted central venous port systems. *World J Surg* 1998;22(1):12-6.
29. Biffi R, De Braud F, Orsi F, Pozzi S, Arnaldi P, Goldhirsch A, et al. A randomized, prospective trial of central venous ports connected to standard open-ended or Groshong catheters in adult oncology patients. *Cancer* 2001; 92(5):1204-12.
30. Biffi R, de Braud F, Orsi F, Pozzi S, Mauri S, Goldhirsch A, et al. Totally implantable central venous access ports for long-term chemotherapy. A prospective study analyzing complications and costs of 333 devices with a minimum follow-up of 180 days. *Ann Oncol* 1998; 9(7):767-73.
31. Di Carlo I, Cordio S, La Greca G, Privitera G, Russello D, Puleo S, et al. Totally implantable venous access devices implanted surgically: a retrospective study on early and late complications. *Arch Surg* 2001;136(9):1050-3.
32. Müller H, Zierski J. [The Huber needle as a special cannula for the puncture of implanted ports and pumps--a mistake in multiple variations]. *Klin Wochenschr* 1988;66(19):963-9.
33. Haindl H. Technical complications of port-catheter systems. *Reg Cancer Treat* 1989; 2(26):238-42.
34. Lam AW, Chen YM, Yang KY, Tsai CM, Perng RP. Disconnection of a venous Port-A-Cath followed by embolization after saline flush: rare case report. *Jpn J Clin Oncol* 1999;29(12):643-5.
35. Kurul S, Saip P, Aydin T. Totally implantable venous-access ports: local problems and extravasation injury. *Lancet Oncol* 2002; 3(11): 684-92.