

Polycythemia Vera (Vaquez' Disease): A Potential Cause of Spontaneous Coronary Artery Dissection: Letter to the Editor

Polistemia Vera (Vaquez Hastalığı): Spontan Koroner Arter Diseksiyonunun Olası Bir Nedeni

Levent ÖZDEMİR, MD, Msc,^a
Orhan Hakan ELÖNÜ, MD, Msc^b

^aDepartment of Cardiology,
Private Melikgazi Hospital,
^bDepartment of Cardiology,
Private Acıbadem Hospital,
Kayseri

Geliş Tarihi/Received: 03.01.2011
Kabul Tarihi/Accepted: 08.02.2011

Yazışma Adresi/Correspondence:
Levent ÖZDEMİR, MD, Msc
Private Melikgazi Hospital,
Department of Cardiology, Kayseri,
TÜRKİYE/TURKEY
dr.leventozdemir@hotmail.com

Key Words: Dissection;
coronary vessels;
polycythemia vera

Anahtar Kelimeler: Diseksiyon;
koroner damarlar; polistemia vera

Türkiye Klinikleri J Med Sci
2012;32(2):599-600

doi:10.5336/medsci.2011-22458

Copyright © 2012 by Türkiye Klinikleri

Spontaneous coronary artery dissection (SCAD) is a rare cause of angina pectoris, myocardial infarction (MI) or sudden death.¹ What caused dissection in our patient who was not at a usual age for idiopathic SCAD? In polycythemia vera (PV), thrombosis due to hyperviscosity and thrombocytosis is mostly concerned as the origin of the coronary ischemic complications. In one study, some histological alterations were shown in coronary intima.² We hereby report a case of SCAD on the grounds of PV and discuss the association SCAD and PV.

A 79 year-old (not a common age for SCAD) woman with a history of rest angina and dyspnea underwent a coronary arteriography. Her coronary arteriogram showed a biluminal lesion extending from proximal left anterior descending artery (LAD) to distal LAD (approximately 60 mm). The appearance was suggestive of SCAD of the left anterior descending artery without any significant atherosclerotic lesion (Figure 1). Right coronary artery was normal. Laboratory investigations revealed the hemoglobin level as 20.7 g/dL, hematocrit as 65%, erythrocyte volume as 58.5 mL/kg (normal: up to 32 mL/kg for woman) with splenomegaly on the physical examination. Subsequently, the diagnosis of polycythemia vera was made and the patient was treated with phlebotomy and hydroxyurea.³

SCAD is mostly seen in middle-aged women in the last trimester of pregnancy and in the early postpartum period in an otherwise healthy subject.⁴ The etiology of SCAD remains unclear. The presumed etiology of spontaneous coronary artery dissection was atherosclerotic plaque rupture, heavy physical exercise and hormonal influences related to pregnancy and contraception.⁵ Treatment consists of clinical and medical treatment, myocardial revascularization surgery, angioplasty with stent, and at times, even a heart transplant.⁶⁻⁸

Association of SCAD and PV has not previously been reported. One case was reported with concomitant SCAD and PV.⁵ However, there was no association between SCAD and PV in this case report. It was mentioned as

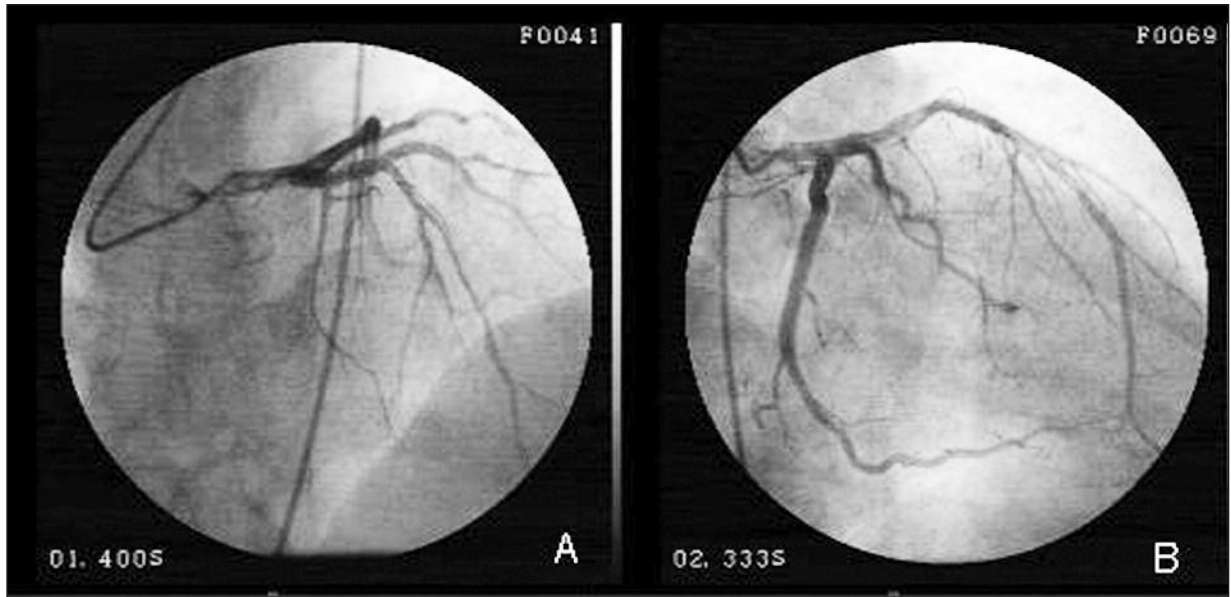


FIGURE 1: Spontaneous coronary artery dissection of the left anterior descending artery without any significant atherosclerotic lesion.

an incidental finding. In fact, SCAD is mostly seen in middle-aged women in the last trimester of pregnancy and early postpartum period. In contrary, our patient was 79 years old, which is not a usual age for idiopathic SCAD. Whether PV plays a role in the pathogenesis of SCAD is unclear. Hermanns et al. reported that pathological changes were present in coronary artery intima (hyperplasia) in PV patients.² We thought that this intimal hyperplasia and further histological changes might

have caused dissection. In PV, if there is an episode of acute coronary syndrome, it may be either result from thrombosis or dissection, due to intimal hyperplasia and possible further histological changes.

In conclusion, although this paper is a case report, we would like to emphasize that PV should be kept in mind in all cases of SCAD as a potential cause. This may lead to a decrease in the number of genuinely idiopathic SCAD.

REFERENCES

1. Pasalodos Pita J, Vazquez Gonzalez N, Perez Alvarez L, Vazquez Rodriguez JM, Castro Beiras A. Spontaneous coronary artery dissection. *Cathet Cardiovasc Diagn* 1994;32 (1):27-32.
2. Hermanns B, Handt S, Kindler J, Füzesi L. Coronary vasculopathy in polycythemia vera. *Pathol Oncol Res* 1998;4(1):37-9.
3. Berlin NI. Polycythemia vera: diagnosis and treatment 2002. *Expert Rev Anticancer Ther* 2002;2(3):330-6.
4. Dhawan R, Singh G, Fesniak H. Spontaneous coronary artery dissection: the clinical spectrum. *Angiology* 2002;53(1):89-93.
5. Kay IP, Williams MJ. Spontaneous coronary artery dissection: long stenting in a patient with polycythemia vera. *Int J Cardiovasc Intervent* 1999;2(3):191-3.
6. Roig S, Gómez JA, Fiol M, Guindo J, Pérez J, Carrillo A, et al. Spontaneous coronary artery dissection causing acute coronary syndrome: an early diagnosis implies a good prognosis. *Am J Emerg Med* 2003;21(7):549-51.
7. DeMaio SJ Jr, Kinsella SH, Silverman ME. Clinical course and long-term prognosis of spontaneous coronary artery dissection. *Am J Cardiol* 1989;64(8):471-4.
8. Kursaklıoğlu H, İyisoy A, Köse S. [Spontaneous coronary artery dissections: Review]. *Türkiye Klinikleri J Med Sci* 2006;26(1):62-7.