

# A Misdiagnosed Tonsillolith Appears as a Radiopaque Lesion Related to an Impacted Third Molar in the Mandible

## Mandibulada Gömülü Yirmi Yaş Dişi ile İlişkili Radyopak Bir Lezyon Olarak Yanlış Teşhis Edilen Bir Tonsil Taşı

Hüseyin Ozan AKINCI,<sup>a</sup>  
Nazife Begüm KARAN,<sup>b</sup>  
Hacer ULUTÜRK,<sup>a</sup>  
Ergün YÜCEL<sup>a</sup>

<sup>a</sup>Department of Oral and Maxillofacial Surgery,  
Gazi University Faculty of Dentistry,  
Ankara

<sup>b</sup>Department of Oral and Maxillofacial Surgery,  
Recep Tayyip Erdogan University,  
Faculty of Dentistry,  
Rize

Received: 18.10.2017  
Received in revised form: 07.12.2017  
Accepted: 18.12.2017  
Available online: 18.10.2018

Correspondence:  
Hüseyin Ozan AKINCI  
Gazi University Faculty of Dentistry,  
Department of Oral and Maxillofacial Surgery, Ankara,  
TURKEY/TÜRKİYE  
ozanakinci@gmail.com

**ABSTRACT** Tonsilloliths are calcified structures that develop in enlarged tonsillar crypts that are packed with bacteria and organic debris. Small areas of calcifications on tonsils are frequently encountered more commonly while larger concentrations and volumes of calcifications occurs with a much lower incidence. The ones with higher concentrations and volumes are named as "Tonsilloliths" (Tonsil Stones). They can be single, multiple, unilateral or bilateral. They can cause symptoms like; recurrent bouts of sore throat, dysphagia, bad taste and odor, otalgia and a foreign body sensation noted on swallowing. However, they are frequently totally asymptomatic. The purpose of this case report is to present the misdiagnosis of a radiopaque lesion associated with an impacted third molar by interpretation from routine panoramic radiography. Further tomographic imaging revealed that the radiopaque lesion is actually a tonsillolith which superimposed on the ramus of the mandible.

**Keywords:** Tonsillar calculi; tonsillolith; tonsil calcification

**ÖZET** Tonsil taşları, tonsil kriptalarının bakteri ve organik debris ile kaplanması sonucu oluşan kalsifiye yapılardır. Tonsiller üzerinde küçük kalsifiye alanların görülmesi sık karşılaşılan bir durum iken, büyük boyutlarda ve yoğunluklardaki tonsil kalsifikasyonları daha nadir olarak görülürler. Bu büyük boyutlardaki tonsil kalsifikasyonları "Tonsil Taşları" (Tonsillolit) olarak adlandırılırlar. Bunlar tek, birden fazla sayıda, tek taraflı veya çift taraflı olarak görülebilirler. Semptom olarak; tekrarlayan boğaz ağrılarına, disfajiye, ağızda kötü tad ve kokuya, kulak ağrısına ve yutkunma sırasında yabancı cisim varlığı hissine sebep olabilirler. Bazen de tamamen asemptomatik olabilirler. Bu vaka raporunda; rutin panoramik radyografik incelemede gömülü 20 yaş dişi ile ilişkide bir lezyon gibi görülen radyopak görüntünün tomografik inceleme sonucunda ramus bölgesine süperpoze olup yanlış yorumlanan bir tonsil taşının görüntüsü olduğu sunulmaktadır.

**Anahtar Kelimeler:** Tonsiller kalkuli; tonsillolit; tonsil kalsifikasyonu

**T**onsilloliths are calcified structures and known to be formed by bacteria and organic debris in tonsillar crypts.<sup>1-5</sup> Small areas of calcifications on tonsils are frequently encountered, and more common compared to larger concentrations and volumes of calcifications, which occur with a much lower incidence rate.<sup>2,4,6,7</sup>

During clinical examination, tonsilloliths may be seen as either white or yellow hard objects within the tonsillar area.<sup>1,5,8</sup> They may be single or multiple and seen unilateral or bilateral.<sup>4,8,9</sup> Yet, they are usually encountered unilateral and in a single formation.<sup>1,7</sup> They can cause odor and bad taste besides symptoms such as; otalgia, dysphagia, sore throat and a foreign

body sensation while swallowing.<sup>5,7,10</sup> However, they are frequently totally asymptomatic.<sup>8,11</sup>

The occurrence of tonsilloliths are reported equally in both genders.<sup>3,4</sup> They may be discovered accidentally in routine panoramic radiographs.<sup>5,8,12</sup> Tonsilloliths are easily misdiagnosed because of their radiopaque appearance on radiographs. On panoramic radiographs, because of the positioning of the elements, they tend to superimpose on the ascending ramus of the mandible or the third molar region. Because of this visual complexity, the possibility of tonsilloliths should be considered during the final diagnoses of the radiopaque lesions in this region.<sup>11</sup>

The aim of this case report is to present a misdiagnosis of a radiopaque lesion being associated with an impacted third molar as the result of a misinterpreted routine panoramic radiography. Further tomographic results revealed that the radiopaque lesion was actually a tonsillolith that visually superimposed on the ramus of the mandible.

## CASE REPORT

A 60 year-old female patient was referred to Gazi University, Department of Oral and Maxillofacial Surgery for the evaluation and assessment of pain and dysphagia. The patient reported suffering of recurrent sore throats, dysphagia, malodor, a pain reflected to the right side of the mandibular area as well as teeth and ear, and a foreign body sensation while swallowing for about two years. Some superficial dental caries, an impaired dental bridge, and edentulous alveolar ridges were observed during the intraoral clinical examination. The palpation of the tonsillar area, which had been causing the patient's complain of pain, was carried out bidigitally. Not any noticeable difference from normal tissue was explored. A detailed palpation of the adjacent tissues was carried out and the result was found normal in tone.

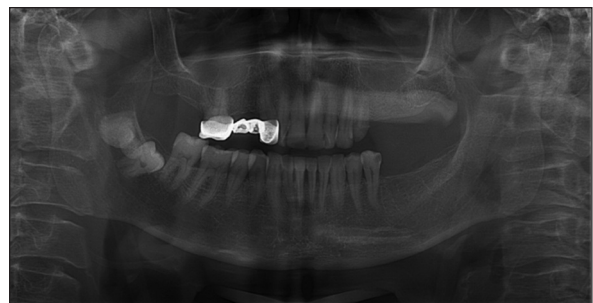Examination of the pharyngeal area with a tongue depressor yielded a large ulcerating right non-inflamed palatine tonsil. The tonsil was yellowish-white colored, mobile, and bigger in size than the other tonsil. The surface of the tonsil was

irregular but it was not tender and the patient did not have any symptoms of infection. Also there was also no palpable neck lymphadenopathy detected. The patient's medical history was unremarkable. Her general health was excellent.

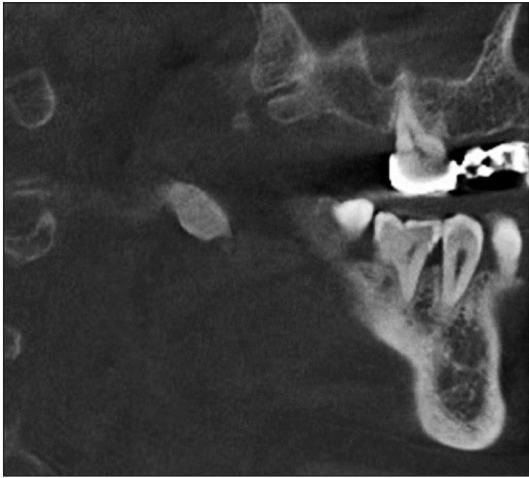Radiographic examination revealed a radiopaque lesion related to an impacted third molar (Figure 1). A second panoramic radiograph was taken to ensure that the image of the radiopaque lesion was not a radiograph artifact. Before any intervention on the lesion, a computed tomography (CT) scan was taken to reinforce the diagnosis. The results of the scan revealed the fact that there was not any intrabony lesion (Figure 2). What was observed was, instead, a superimposition of a radiopacity in the pharynx zone, leading to a prediagnosis of tonsillolith (Figures 3-4). The patient was directed to department of Otolaryngology and the magnetic resonance (MR) images captured there actually supported this prediagnosis. The proposed treatment was the removal of the tonsillolith and a total tonsillectomy operation. The operation carried out by Gazi University Otolaryngology Department under general anesthesia after which, immediate regression of symptoms was obtained. No major complications had been observed during the postoperative follow up, a year after.

## DISCUSSION

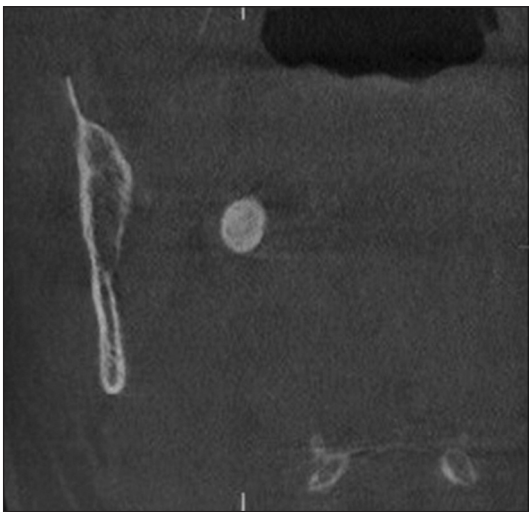
Tonsilloliths are most commonly seen in young adults who have a history of recurrent sore throat.<sup>4,6,8</sup> The sizes range from tiny undescrivable radiopaque lesions, to giant tonsilloliths in the literature.<sup>6,13,14</sup>



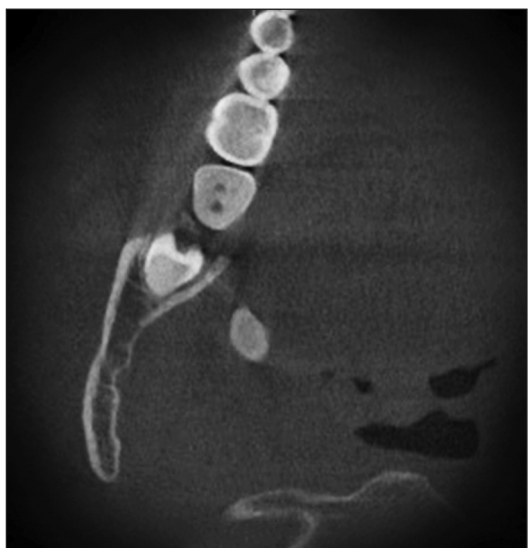**FIGURE 1:** Panoramic radiograph revealed a radiopaque lesion related to an impacted third molar.



**FIGURE 2:** Sagittal view of computed tomography scan demonstrating a radiopaque lesion in the right pharyngeal region.



**FIGURE 3:** Coronal view of computed tomography scan.



**FIGURE 4:** Transverse view of computed tomography scan.

Tonsils mainly consist of lymphoid tissues.<sup>5,6</sup> The surface of the tonsil forms crypts.<sup>6</sup> The specific etiology of tonsilloliths is still unknown.<sup>1,5-7</sup> Repeated inflammation of the tonsillar crypts may cause fibrosis of the surrounding tissues.<sup>1,6</sup> Retention cysts are formed within the inflamed crypts by bacterial and epithelial debris. Tonsilloliths are believed to be formed as a consequence of the calcification, resulting from the deposition of inorganic salts within the saliva as phosphate, carbonate, calcium and magnesium.<sup>4,5,8</sup> Foreign bodies in the tonsillar crypts such as tablet or capsules are other possible etiological factors.<sup>5</sup> Tonsilloliths also play a role in the inflammation of the tonsil, by acting as a reservoir for pathogen microorganisms.<sup>10</sup>

Tonsilloliths can be detected on routine panoramic radiographs, although their occurrence has a low frequency rate.<sup>2,5</sup> It should be kept in mind that these calcified structures are sometimes associated with other lithiasis, such as sialoliths.<sup>15</sup> It is essential to hold a differential diagnosis of radiopaque lesions of the mandible.<sup>5</sup> Advanced imaging techniques such as MRI and CT can provide precise information in the establishment of the final diagnosis.<sup>5,8</sup>

Surgical removal of the tonsils are necessary for the definitive diagnosis.<sup>8</sup> In general, tonsilloliths are asymptomatic and require conservative treatment only. Yet, there has been a number of reported cases that show life-threatening effects such as odynophagia and dyspnea, caused by upper airway obstruction.<sup>1</sup>

The bacterial composition of the tonsilloliths depends on the health of the upper respiratory tract.<sup>1,10</sup> The study of Tsuneishi et al. showed that the bacterial compositions of the tonsilloliths carry at least one anaerobic bacterial species that produces hydrogen sulfide or methyl mercaptan. The methyl mercaptan and hydrogen sulfide are known to be the factors of oral malodor, which, as a common symptom for tonsillolith, could be explained through the same reasoning.<sup>10</sup>

Tonsilloliths or tonsil calculi may be misdiagnosed as acute follicular tonsillitis, tuberculosis,

syphilis or mycosis. The main reason of such misdiagnosis is the similarities between tonsilloliths and these diseases, resulted from the whole calcifications around the pharyngeal zone.<sup>8</sup>

Tonsilloliths may also be confused with the anatomical bone structures which appear to be more radiopaque than dense mandibular ramus, large maxillary tuber, hamulus pterygoideus, elongated processus styloideus, calcified lymph nodes, salivary gland calcifications, phleboliths, and calcification of arteries.<sup>1,5,8</sup>

Garres Osteomyelitis, foreign bodies, osteoma, sclerosing osteitis, idiopathic osteosclerosis, fibrous dysplasia may be misdiagnosed as radiopaque structures in the radiographs as well.<sup>4</sup> Dental practitioners have to be aware of these ghost images and the possibility of superimpositions on panoramic radiographs, as they cause misinterpretations. In order to prevent such misinterpretations, the possibility of the existence of tonsilloliths should always be considered during

the process of differential diagnosis of the lesions in this region.

### Source of Finance

*During this study, no financial or spiritual support was received neither from any pharmaceutical company that has a direct connection with the research subject, nor from a company that provides or produces medical instruments and materials which may negatively affect the evaluation process of this study.*

### Conflict of Interest

*No conflicts of interest between the authors and / or family members of the scientific and medical committee members or members of the potential conflicts of interest, counseling, expertise, working conditions, share holding and similar situations in any firm.*

### Authorship Contributions

**Idea/Concept:** Hüseyin Ozan Akıncı; **Design:** Nazife Begüm Karan; **Control/Supervision:** Ergün Yücel; **Data Collection and/or Processing:** Hüseyin Ozan Akıncı; **Analysis and/or Interpretation:** Hüseyin Ozan Akıncı; **Literature Review:** Hacer Ulutürk; **Writing the Article:** Hüseyin Ozan Akıncı; **Critical Review:** Nazife Begüm Karan; **References and Fundings:** Nazife Begüm Karan; **Materials:** Hacer Ulutürk.

## REFERENCES

- Lo RH, Chang KP, Chu ST. Upper airway obstruction caused by bilateral giant tonsilloliths. *J Chin Med Assoc* 2011;74(7):329-31.
- Ram S, Siar CH, Ismail SM, Prepageran N. Pseudo bilateral tonsilloliths: a case report and review of the literature. *Oral Surg Oral Med Oral Pathol Oral Radiol Endod* 2004;98(1):110-4.
- Mandel L. Multiple bilateral tonsilloliths: case report. *J Oral Maxillofac Surg* 2008;66(1):148-50.
- Chan J, Rashid M, Karagama Y. An unusual case of a tonsillolith. *Case Rep Med* 2012; 2012:587503.
- Sharma KH, Phull TS. Unilateral tonsillolith: a serendipitous finding. *Asian J Oral Health Allied Sci* 2011;1(3):213.
- Caldas MP, Neves EG, Manzi FR, de Almeida SM, Bóscolo FN, Haiteir-Neto F. Tonsillolith-report of an unusual case. *Br Dent J* 2007;202(5):265-7.
- Hung CC, Lee JC, Kang BH, Lin YS. Giant tonsillolith. *Otolaryngol Head Neck Surg* 2007;137(4):676-7.
- el-Sherif I, Shembesh FM. A tonsillolith seen on MRI. *Comput Med Imaging Graph* 1997;21(3):205-8.
- Haring JI. Case #9. Tonsilloliths. *RDH* 1996;16(9):8, 55.
- Tsuneishi M, Yamamoto T, Koeguchi S, Tamaki N, Fukui K, Watanabe T. Composition of the bacterial flora in tonsilloliths. *Microbes Infect* 2006;8(9-10):2384-9.
- Ozcan E, Ural A, Oktemer TK, Alpaslan G. Bilateral tonsillolithiasis: a case report. *Oral Surg Oral Med Oral Pathol Oral Radiol Endod* 2006;102(3):e17-8.
- Cramer M, Bassetti R, Werder P, Kuttenger J. [Tonsil calculi in the orthopantomography image]. *Swiss Dent J* 2016;126(1):29-36.
- Silvestre-Donat FJ, Pla-Mocholi A, Estelles-Ferriol E, Martinez-Mihi V. Giant tonsillolith: report of a case. *Med Oral Patol Oral Cir Bucal* 2005;10(3):239-42.
- Dykes M, Izzat S, Pothula V. Giant tonsillolith-a rare cause of dysphagia. *J Surg Case Rep* 2012;2012(4):4.
- Suarez-Cunqueiro MM, Dueker J, Seoane-Leston J, Schmelzeisen R. Tonsilloliths associated with sialolithiasis in the submandibular gland. *J Oral Maxillofac Surg* 2008;66(2):370-3.