

# Classification of the thoracic and abdominal lymph nodes of the rat

Mustafa SARSILMAZ<sup>1</sup>, Yakup GÜMÜŞALAN<sup>1</sup>, H.Hamdi ÇELİK<sup>2</sup>,  
Memduh GEZİCİ<sup>3</sup>, M.Doğan AKŞİT<sup>2</sup>

<sup>1</sup>Dept. of Anatomy and, <sup>2</sup>Research Center, Gülhane Military Medical Academy,  
<sup>3</sup>Dept. of Anatomy, Medical School of Hacettepe University, Ankara, TURKEY

*The organization of lymphoid system in laboratory animals has not been documented well. In this study, 24 adult white rats of both sexes were used. The lymph nodes of the rats were marked by injection of India Ink to certain parts of their bodies. The numbers, weight, size, and localization of the lymph nodes were noted for each site. The nomenclature convenient to the localization and classification of the lymph nodes has also been done. Descriptions were made in the light of previous studies and Nomina Anatomica Veterinaria. [Turk J Med Res 1994, 12(b): 185-191]*

Key Words: Lymph node, Rat

Rats are frequently used as laboratory animals in biological investigations. Therefore, the importance of the anatomy of the rat and especially the nodes and tracts of the lymphatic system has increased (1). Major functions of the lymph nodes are to filtrate the lymphatic substance, to phagocytate the particulate material, to produce antibodies, to contribute the proliferation and recirculation of the lymphocytes (2).

Various investigations on the lymphatic system of various domestic and laboratory animals have been done. Some of these investigations were systematical in nature and some of them were detailed studies on certain structures. There is an abundance of the systematical studies or the standardization of the lymph nodes of the rat. However, morphological specialities such as the anatomical localization, neighbouring structures, shape, size and number of the lymph nodes of the rat do not reflect a certain standard. Because of the discrepancy between the previous works, we thought that it would make lots of use to study on this subject.

Our study on the lymph nodes of the rat consisted of two steps. In the first step, the classification of the cranial, cervical, front and back extremity lymph nodes of the rat has been done. Results of this study

were published as a separate paper (3). In this study, which comprises the second step, the lymph nodes of the rat in the thoracic and abdominal cavities have been investigated in detail.

## MATERIALS AND METHODS

Twenty four normal adult rats of both sexes, each weighing between 150 and 300 g were studied. The animals were obtained from Gulhane Military Medical Academy Research Center. Rats were anaesthetized by intramuscular injection of Ketamin (Ketalar im.) at a dose of 40 mg/kg. Then 0.5 cc, 50% black India Ink (Rotring Drawing Ink Black, Art 591017) in saline was injected into thoracic and abdominal cavities and 0.25 cc into the ventral aspect of the tail of the rats. For the purpose of marking out the abdominal and thoracic lymph nodes sufficiently, different waiting periods (24,48,72 hours and 1 week) were tested after the injections of India Ink. At the end of the waiting periods, rats were killed by overdose ether inhalation. Then, they were dissected by classic methods and the lymph nodes were brought out. Anatomical localization, neighbouring structures and the number of the lymph nodes were noted. Weight of the lymph nodes were determined by using a Sartorius scale. By using milimetric paper, the length and the width of the lymph nodes were measured and photographs were taken. Histologic sections were also made.

## RESULTS

The lymph nodes of the rat were divided into two main groups according to their localization in thoracic or ab-

Received: April 17, 1993

Accepted: Sept. 29, 1994

Correspondence: Mustafa SARSILMAZ

Dept. of Anatomy  
Gulhane Military Medical Academy  
Ankara-TURKEY

**Table 1.** Measured values of the weight, length, width and number of the lymph nodes together with the groups and names of them

Lymph Nodes (LN)	Weight (g) min-max.	Length/Width (mm) min-max.	Number min-max.
<b>A.LN located in thoracic cavity:</b>			
Lnn.parathyria.....	0.015-0.02	1/1	3-5
right	0.03-0.04	1-3/1-2	2-4
left	0.035-0.045	1-3/1-2	3-5
right	0.005-0.1	1/1	0-1
left	0.005-0.015	1/1	0-1
<b>B.LN located in abdominal cavity:</b>			
1. Lnn. viscerates:			
	0.015-0.02	1/1	1-3
Lnn.gastrici dorsales.....	0.025-0.035	1-2/1-1.5	2-3
	0.02-0.025	1-1.5/1	2
	0.01-0.04	1-3/1-2	3-13
	0.01-0.03	1-2/1-1.5	2-5
2. Lnn. parietales:			
Lnn.caudalis.....	0.02-0.03	1-2/1-1.5	0-1
Lnn.iliari..... right	0.03-0.04	2-3/1-2	1
left	0.04-0.05	2-3/1-2	1-2
Lnn. paraaortic]..... right	0.025-0.035	1-2/1-1.5	0-1
left	0.025-0.03	1-2/1-1.5	1
1 nn.rpnaIAQ right	0.02-0.03	1-2/1	1-2
left	0.02-0.025	1-2/1	1
right	0.015-0.02	1/1	0-1
left	0.015-0.025	1/1	0-1

dominal cavities. By paying attention to the studies of the previous authors, the lymph nodes in each group were named accordingly. By taking into account the localizations of the lymph nodes, a scheme of nomenclature and the number of the lymph nodes are shown in Table 1.

The lymph nodes that were found in our study are classified as follows.

#### A. Lymph nodes in thoracic cavity

They were evaluated in three groups which consisted of parathyric, dorsal mediastinal and paravertebral lymph nodes (Figure 1).

1. Lnn.parathyria: They are embedded in the fat lateral to the capsule of the thymus gland, and are three or five in number. They become significant from light gray to dark black in colour according to the amount of India Ink that is held within them. They have been found constantly in all dissections (Picture 1).

2. Lnn.mediastinales dorsales: These lymph nodes are located both at the right and left sides posterior to pulmonary trunk and postero-inferior to the bifurcation of trachea. Dorsal mediastinal lymph nodes on the left were larger and more in number relative to the right. Generally, the number of the lymph nodes located on the right side were two to four; but they were three to five on the left. They have been found constantly in all dissections.

3. Lnn.paravertebrals: Their localizations were nearby the vertebral column just below the costal neck. They were two in number. Generally the right lymph node was localized below the eighth and the left one was localized below the ninth costal neck. These lymph nodes were smaller in size and not always existed.

#### B. Lymph nodes in abdominal cavity

These lymph nodes were evaluated in two sub-groups as visceral and parietal. The visceral group was comprised of intraperitoneal lymph nodes that were related with intraabdominal organs. Whereas the lymph nodes located on the posterior abdominal wall formed the parietal group.

##### In the visceral group

Lienal, dorsal gastric, portal, cranial and caudal mesenteric lymph nodes and omental lymphoid accumulations were defined (Figure 1,2).

1. Lnn.lienales: They were localized near the greater curvature of the stomach medial to the spleen, and were three in number at most. They were generally of middle size and found constantly.

2. Lnn.gastrici dorsales: They were localized posterior to the stomach and at the left of the portal lymph nodes that were found nearby the portal vein. They were ordered usually vertically but sometimes horizontally. These lymph nodes were of middle size and generally paired and were found constantly (Picture 2).

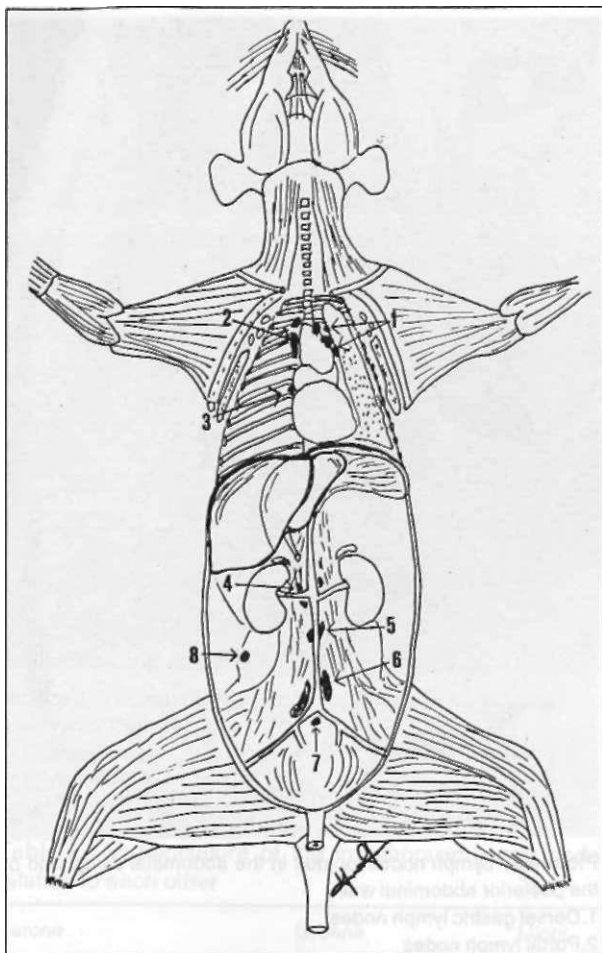


Figure 1. Schematic representation of the lymph nodes existing in the thoracic and abdominal (parietal group) cavities.

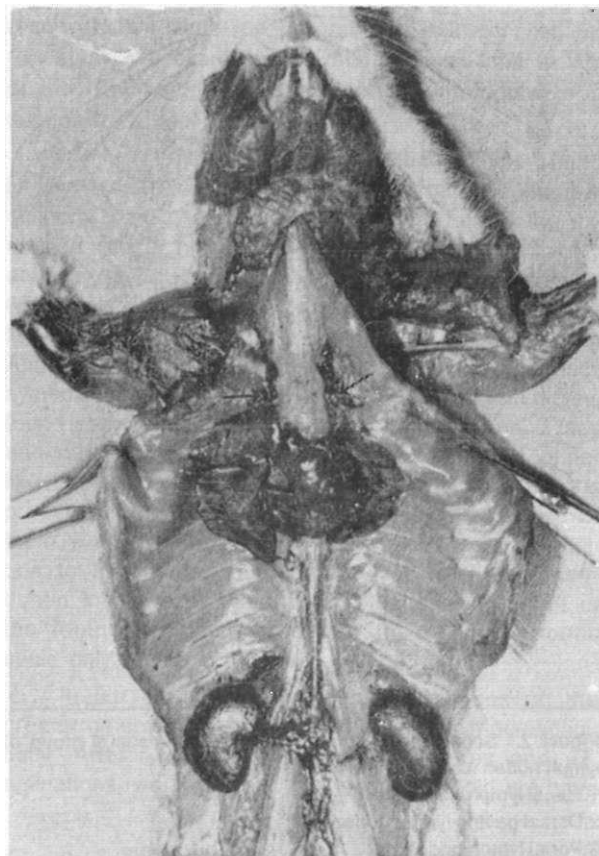
1. Parathymic lymph nodes
2. Dorsal mediastinal lymph nodes
3. Paravertebral lymph node
4. Renal lymph nodes
5. Paraaortic lymph nodes
6. Iliac lymph nodes
7. Caudal lymph node
8. External lumbar lymph node

3. *Lnn.portales*: They lie vertically just nearby the portal vein. They were of middle size but also smaller than the dorsal gastric lymph nodes. These lymph nodes were paired and their presence were constant (Picture 2).

4. *Lnn.mesenterici craniales*: They lie along the root of the mesenterium. They were three to thirteen in number. They may be arranged separately from each other and may also form masses. Their sizes were variable and they were constant (Picture 2).

5. *Lnn.mesenterici caudales*: They were localized in the peritoneum medial to the descending colon. Their sizes were variable like the cranial mesenteric ones and they were found constantly.

*Turk J Med Res 1994; 12 (5)*



Picture 1. Parathymic lymph nodes, located lateral to the thymus gland (arrows)

**Omental lymphoid accumulations:** They were found in the distal parts of the greater omentum in a distributed manner. Their sizes were very small and they were not always seen. When examined histologically, it was seen that they did not have the structure of a lymph node and were only lymphoid accumulations.

### In the parietal group

Caudal, iliac, paraaortic, renal and external lumbar lymph nodes were defined (Figure 1,2).

1. *Lnn.caudalis*: This is a unique lymph node which is located below the bifurcation of abdominal aorta. It may become visible when the India Ink is injected to the ventral part of the tail. Its presence is not constant.

2. *Lnn.iliaci*: They lie on both sides of the distal portion of the abdominal aorta. They were large and frequently two in number, but sometimes three. If there was only one iliac lymph node, it was usually localized on the right. They were constant (Picture 2).

3. *Lnn.paraaortici*: They were found on both sides of the abdominal aorta where the proximal and the middle one third of the abdominal aorta intersect. They were of middle size and two in number. These lymph nodes

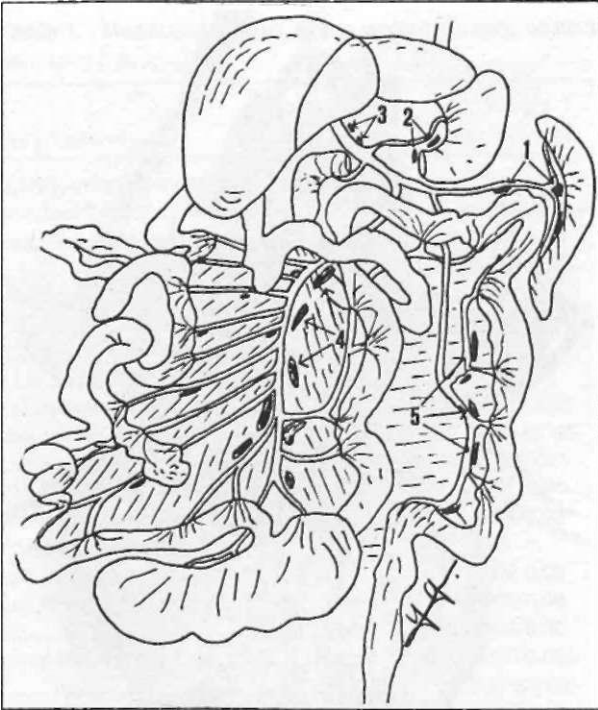


Figure 2. Schematic representation of the visceral group of lymph nodes existing in the abdominal cavity

1. Lienal lymph nodes
2. Dorsal gastric lymph nodes
3. Portal lymph nodes
4. Cranial mesenteric lymph nodes
5. Caudal mesenteric lymph nodes

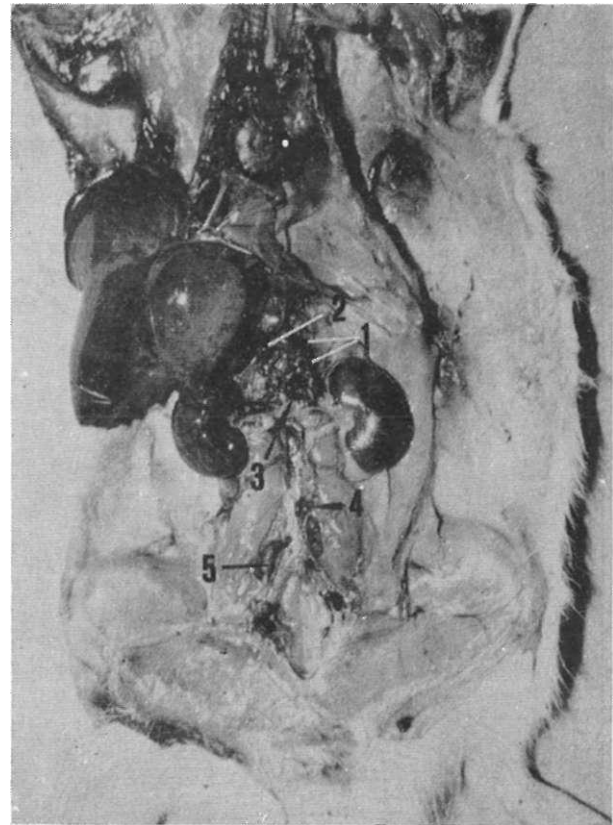
were constant (Picture 2). The normal structure of a lymph node was observed in the section of these nodes (Picture 3).

4. Lnn.renales: They were localized dorsocranial to the renal vein and were found on both sides. They were of middle size and their presence were not constant (Picture 2).

5. Lnn.lumbales externas: They were localized in the retroperitoneal fat pad lateral to the psoas major muscle. They usually lie in the region where lumbar vein courses towards the inferior vena cava. These lymph nodes were found one on each side, were of middle size and not always seen.

## DISCUSSION

When particulate substances such as colloidal carbon (black India Ink) are injected in a subserosal or subcutaneous area, they rapidly fill the lymph capillaries and accumulate in the regional lymph nodes (1). With this method, they may easily be distinguished from the adjacent tissues. While some of the lymph nodes do not collect any carbon particles, some of them pick the contrast material up less and are seen light gray in colour. On the other hand, there may be significantly



Picture 2. Lymph nodes located in the abdominal cavity and on the posterior abdominal wall

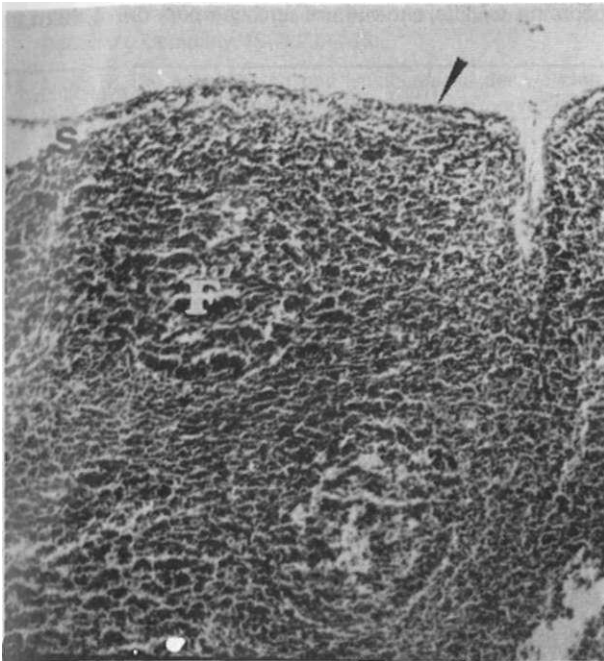
1. Dorsal gastric lymph nodes
2. Portal lymph nodes
3. Renal lymph nodes
4. Paraortic lymph node
5. Iliac lymph nodes

dark coloured lymph nodes proportional to the amount of carbon collected in them (4). Colour differences that are seen between the lymph nodes during our study are due to the same reason that Blau and Gaugas have reported.

Many authors (5-16) investigated the lymphatic system of various animals. When the results of these investigations are evaluated, it becomes clear that there is not a common terminology which defines the lymphatic system of those animals.

Barone et al (17), Greene (18), Miotti (19), Tilney (1) and Kawashima (9) did not put forward a common terminology in their studies on rats. Chiasson (20) also did not give enough information on the lymphatic system of the rat in his atlas.

The requirement for a common terminology is obvious in the investigations in which laboratory animals are used. The lymph nodes that have been identified in most of the previous studies are similar in many respects. However, there is no standard terminology.



Picture 3. The histologic section of a paraaortic lymph node  
 Arrowhead: Capsule  
 S: Marginal sinus  
 F: Lymph follicle

result of their study on pregnant rats. In the light of this study, we examined the number, size and weight of the lymph nodes of the adult rats thoroughly and summarized them in Table 1.

Tilney (1) reported that the localization of the lymph nodes would not change whereas the number of them could change according to the age of the examined rat. In his paper, he commented on Higgin's studies on newborn rats in which few lymph nodes were found and pointed out that this was directly related with the age of these rats. He also noted that Andrew and Andrew while investigating the lymphatic systems of the young and adult rats in their studies, found some differences stemming from the age. Tilney and other authors that were mentioned in his paper like Casparis (1918) and Simer (1938) supposed the presence of the omental lymph nodes, but none of them was able to demonstrate these nodes. In addition to this, lymphonodi omentales were also mentioned in *Nomina Anatomica Veterinaria* (21), but in the footnote it was noted that these lymph nodes could only be found in horses.

In our study, we dissected the tissues on the greater omentum resembling lymph nodes macroscopically. After routine histological procedures and examinations, we saw that these specimens did not have

**Table 2.** Nomenclature of the intrathoracic lymph nodes according to different authors and comparison of them in relation to each other

Barone	Greene	Miotti	Tilney	Kawashima
Lnn.inter costales		Lnn.para vertebrates	Lnn.para vertebrates	
Lnn.mediastinales anteriores	Lnn.thoracici	Lnn.mediastinales anteriores		
Lnn.mediastinales posteriores	Lnn.thoracici	Lnn.mediastinales posteriores	Lnn.mediastinales posteriores	Lnn.medjastinales
Lnn. bronchiales	Lnn.thoracici	Lnn.tracheobronchiales		Lnn.bronchiales
—	Lnn.thoracici	Lnn.sternales	Lnn.parathyfici	—

This difficulty was also encountered in the comparison of studies which were made on the same type of laboratory animal. Specifically, a standard for the number and nomenclature of the lymph nodes of the rat is needed. We have listed the lymph nodes which were defined by different names and the authors relative to each other in Table 2 and 3.

Mc Lean et al (2), emphasized the importance of the number, size and weight of the lymph nodes as a

lymph node architecture and were only omental lymphoid accumulations.

The lymph nodes which are among the basic elements of the lymphoid system are being investigated by more and more investigators in various laboratory animals. We believe that, in the studies aiming to contribute to this subject, it is necessary to clarify the nomenclature differences of the lymph nodes of the rat and to put forward a certain standard on the subject.

**Table 3.** Nomenclature of the intraabdominal lymph nodes according to different authors and comparison of them in relation to each other

Barone	Greene	Miotti	Tilney	Kawashima
Lnn.iliaci interni (promontorii)	Ln.caudalis	Ln.sacralis hypogastrics	Lnn.caudales	Ln.sacralis
Lnn.iliaci externi	Lnn.lumbales	Lnn.lumbales	Lnn.iliaci	Lnn.iliaci
Lnn.lumbo aortici		Lnn.para aortici	Lnn.paraaortici	
Lnn.iliaci circumflexa		Lnn.iliaci laterales	Lnn.lumbales extérnales	Lnn.lumbales (Lnn.coeliaci)
Lnn.renales	Lnn.renales	Lnn.renales	Lnn.renales	Lnn.coeliaci
Lnn.hepatici		Lnn.hepaticus	Lnn.portales	
Lnn.gastrici	Lnn.cisternales	Lnn.cisternales	Lnn.gastrici posteriores	Lnn.coeliaci
	Lnn.Henaus	Lnn.gastroduodeno pancreatici	Ln.Henaus	
Lnn.mesenterici	Lnn.intestinalis	Lnn.jejunales	Lnn.mesenterici superiores	Lnn.mesenterici craniales
Lnn.caecales	Lnn.intestinales	Lnn.ileocaecales	Lnn.mesenterici superiores	Lnn.mesenterici craniales
Lnn.colici	Lnn.intestinales	Lnn.colici craniales& caudales	Lnn.mesenterici inferiores	Lnn.mesenterici caudales

### Rafa ait göğüs ve karın boşluğu lenf nodçillerinin sınıflandırılması

*Laboratuvar hayvanlarında, lenfoid sistemin organizasyonu tam olarak ortaya konmamıştır. Bu nedenle, her iki cinsten olmak üzere toplam 24 erişkin beyaz rat kullanılarak bu çalışma yapıldı. Ratların vücuduna belirli bölgelerden çini mürekkebi enjekte edilerek lenfnodları belirgin hale getirildi. Her bölgedeki lenf nodlarının sayıları, ağırlığı, boyutu ve lokalizasyonu belirlendi. Lenf nodlarının lokalizasyona uygun isimlendirilmesi ve sınıflandırılması önceki çalışmalara ve Nomina Anatomica Veterinaria'ya uygun olarak yapıldı. [Türk J MedRes 1994; 12(5): 185-191]*

## REFERENCES

1. Tilney NL. Patterns of lymphatic drainage in the adult laboratory rat. J Anat 1971; 109(3):369-83.
2. Mc Lean JM, Mosley JG, Gibbs ACC. Changes in the thymus, spleen and lymph nodes during pregnancy and lactation in the rat. J Anat 1974; 118(2):223-9.
3. Sarsılmaz M, Gezici M. Göğüs ve karın dışındaki rat lenf nodüllerinin sınıflandırılması. Yeni Tıp Dergisi 1992; 9(4):7-12.
4. Blau JN, Gaugas JM. Parathymic lymph nodes in rats and mice. Immunology 1968; 14:763-5.
5. Miotti R. Die lymphknoten und lymphgefasse des syrischen goldhamsters. Acta Anat 1961; 46:192-216.
6. Chretien PB, Behar JR, Kohn Z et al. The canin lymphoid system: A study of the effect of surgical excision. Anat Rec 1967; 159:5-16.
7. Özgüden T. Yerli tiftik keçisi ile Karaman koyununda karın, leğen ve ard bacak lenf sisteminin makroanatomik (komparatif topografik) ve subgross araştırılması. AÜ Vet Fak Dergisi 1967; 14:387-413.
8. Allen ED, Mc Lean JM. Some observations on pelvic lymph nodes of the rabbit during pregnancy. J Anat 1971; 109(2):201-7.
9. Kawashima Y. The lymph system in rodents. Jap J Vet Res 1972;20:35-43.
10. Tanudimadja K, Ghoshal NG. The lymph nodes and lymph vessels of thoracic viscera of the goat (Capra hircus). Anat Histol Embryol 1973; 2:316-26.
11. Tanudimadja K, Ghoshal NG. Lymph nodes and lymph vessels of the head of the goat (Capra hircus). Am J Vet Res 1973;34:909-14.
12. Hampl A, Zalesak J. Superficial lymph nodes in mink (Lutreola vison). Acta Univ Agric Fac Agron 1979; Brno XXVII:169-75.
13. Hampl A, Kopunecz P. Lymph nodes in hare (Lepus europaeus Pallas 1778). I.Lymph nodes of the head and neck. Acta Univ Agric Fac Agron 1982; Brno XXX:121-32.
14. Hampl A, Koutny P. Lymph nodes in hare (Lepus europaeus Pallas 1778). II.Superficial lymph nodes of thorax, abdomen, pelvis and limbs. Acta Univ Agric Fac Agron 1982; Brno XXX: 133-43.
15. Hopwood PR. An investigation of the topography of the lymphatic system of the grey kangaroo (Macropus giganteus). I.The superficial lymphatic system. J Anat 1987; 157:181-95.
16. Hampl A, Prasek J. Lymph nodes in hare (Lepus europaeus Pallas 1778). III.Lymphocentrum iliosacrale. Anat Anz Jena 1990; 171:31-4.
17. Barone R, Bertrand M, Desenclos R. Recherches anatomiques sur les ganglions lymphatiques des petits rongeurs de laboratoire (cobaye, rat et souris). Revue de Médecine Vétérinaire 1950; 101:423-37.

18. Greene EC. Anatomy of the Rat. New York&London: Hafner Publishing Company, 1963:239-336.
19. Miotti R. Die lymphknoten und lymphgefasse der weissen ratte (*Rattus norvegicus* Berkenhout, *Epimys norvegicus*). *Acta Anat* 1965; 62(4):489-527.
20. Chiasson RB. Laboratory Anatomy of the White Rat. 4th ed. Iowa USA: Wm C Brown Company Publishers, 1980:73-5.
21. International Committee on Veterinary Anatomical Nomenclature of the World Association of Veterinary Anatomists. Mexico City 1980, published in Ithaca New York, 1983.