

A Case of Autoimmune Lymphoproliferative Syndrome with Kimura's Disease Like Histopathology

Kimura Hastalığına Benzeyen Histopatolojik Bulguları Olan Otoimmün Lenfoproliferatif Sendromlu Bir Olgu

Saniye GÜLLE, MD,^a
Huseyin GÜLEN, MD,^a
Hasan AĞIN, MD,^a
Ferah GENEL, MD,^b
Suna ASILSOY, MD,^c
Canan VERGİN, MD,^a
Safiye AKTAŞ, MD^d

Departments of

^aPediatric Hematology,

^bPediatric Immunology,

^cPediatric Allergy,

^dPathology,

Dr. Behçet Uz Child Disease and Surgery Education and Research Hospital, İzmir

Geliş Tarihi/Received: 13.05.2008

Kabul Tarihi/Accepted: 19.11.2008

Yazışma Adresi/Correspondence:

Saniye GÜLLE, MD

Dr. Behçet Uz Child Disease and

Surgery Education and

Research Hospital,

Department of Pediatric Hematology,

İzmir,

TÜRKİYE/TURKEY

saniyegulle@mynet.com

ABSTRACT Autoimmune lymphoproliferative syndrome (ALPS) is characterized by a nonmalignant lymphadenopathy (LAP), hepatosplenomegaly and other autoimmune disorders, usually hemolytic anaemia and immune-mediated thrombocytopenia. Several non-haematological autoimmune disorders have also been reported with ALPS including Guillain-Barre syndrome, glomerulonephritis and autoimmune hepatitis. In ALPS, the potential exists for multiple autoimmune disorders to occur in a single patient. Kimura's disease is a chronic inflammatory disorder of unknown etiology but it is thought to be an immunologic or autoimmune disorder. Kimura's disease manifests as tumor-like swelling in the soft tissues that is associated with eosinophilia and a high concentration of IgE in the peripheral blood. In this report, we present a case that was diagnosed as ALPS with generalized lymphadenopathy, hepatosplenomegaly, coombs positive hemolytic anaemia and immunophenotyping of peripheral blood but besides who was showing the characteristics of Kimura's disease with high serum IgE level, eosinophilia and lymph node pathology.

Key Words: Autoimmunity; lymphatic diseases; eosinophilia

ÖZET Otoimmün lenfoproliferatif sendrom (ALPS), malign olmayan lenfadenopati (LAP), hepatosplenomegali, otoimmün bulgularla giden bir hastalıktır. En sık görülen otoimmün hastalık hemolitik anemi ve immün trombositopenidir. ALPS'li hastalarda hematolojik olmayan otoimmün hastalıklara da rastlanmaktadır. Bunlar arasında glomerülofrit, Guillain-Barre sendromu ve otoimmün hepatit sayılabilir. Aynı hastada zaman içinde birden fazla otoimmün hastalık gelişebileceği de bildirilmiştir. Kimura hastalığı ise etiyolojisi bilinmeyen immünolojik veya otoimmün bir bozukluğa bağlı gelişebilen kronik inflamatuvar bir hastalıktır. Bu hastalık yumuşak dokuda tümör benzeri şişlik, periferik kanda eozinofili ve IgE yüksekliği ile seyredir. Bu makalede, yaygın LAP'ı, hepatosplenomegalisi, Coombs pozitif hemolitik anemisi ve periferik kanın akım sitometrik incelemesindeki bulguları ile ALPS tanısı alan ancak eozinofili, yüksek serum IgE düzeyi ve lenf nodunun histopatolojik bulguları ile Kimura hastalığı özellikleri gösteren bir olgu sunulmuştur.

Anahtar Kelimeler: Otoimmünite; lenfadenopati; eozinofili

Türkiye Klinikleri J Pediatr 2009;18(4):345-8

Autoimmune lymphoproliferative syndrome (ALPS) is a pediatric disease characterized by chronic nonmalignant lymphoproliferation, autoimmunity, LAP, hepatosplenomegaly, and haematological abnormalities such as haemolytic anemia, thrombocytopenia and neutropenia.¹ Elevated numbers and percentages (>%) of double-negative (CD4⁻CD8⁻) T cells, and characteristic pathologic findings in lymph nodes or sple-

en are the other important diagnostic features of ALPS.² Genetic basis has been elucidated in some forms of the disease (i.e. defects in Fas, FasL, caspase 10 and caspase 8 genes) and patient were classified under three subgroups based on the genetic defect.³

Kimura's disease (KD) is a chronic inflammatory disease with tumor-like lesions that is associated with eosinophilia and a high concentration of IgE in the peripheral blood.⁴ Although the etiology is unknown, it probably represents an aberrant chronic immune response. It is also known to predominantly occur in men from Asia and presents as painless swellings in the subcutis, often in the head and neck region, and may be associated with regional lymphadenopathy.⁵ We describe a 4 years-old Turkish boy with ALPS associated with KD histology.

CASE REPORT

A 4-year-old boy born to non-consanguenous Turkish parents was admitted to our hospital with chief complaints of pallor, fever, persistent cough, multiple cervical swelling for three months. His past history was not remarkable significant. On physical examination he was pale. Generalized LAP (axillary, cervical and inguinal, the largest lymph node was 3 x 3 cm in axillary region) mobile, rigid and painless and hepatosplenomegaly (4 cm and 5 cm below the costal margins respectively) were present. His initial blood count showed a hemoglobin level of 5, 6 g/dL, a hematocrite of 20%, a platelet count of $350 \times 10^9/L$ and a white blood cell count of $15 \times 10^6/L$ (37% polymorphonuclear cell, 50% lymphocyte, 1% monocyte, 12% eosinophils.) The reticulocyte count was 6%. The direct Coombs test was positive. Stool examination was normal. Viral serologic studies including cytomegalovirus, Epstein-Barr virus, herpes simplex virus, rubella virus, hepatitis B virus, hepatitis C virus, human immunodeficiency virus and toxoplasma were negative for an acute infection. Serum immunoglobulins (IgG; 1400 mg/dL, IgA; 110 mg/dL, IgM; 150 mg/dL) were in the normal range according to age. Serum IgE level was elevated (2600 mg/dL) and antiphospholipid antibodies were positive. Bone mar-

row aspiration revealed increased number of myeloid precursors (myeloid/erythrocyte ratio: 5/1 and eosinophils (17%).

Peripheral blood flow cytometric analysis showed that CD95 (Fas) expression was 18% and CD4⁺CD8⁻ T cells were 36% in lymphocyte population. Genetic analysis for ALPS could not be performed. Axillary lymph node biopsy was performed and nodal architecture was mainly preserved. The histopathologic evaluation of the lymph node biopsy revealed fibrous bundles intersected from perinodal areas. The sinuses were patent and a prominent reactive follicular hyperplasia existed (Figure 1). Pale areas in the interfollicular zone were composed of epithelioid histiocytes, eosinophils, immunoblasts intermingled with endothelial venules. There were a few Warthin-Finkeldey giant cells around the microabscesses formed by eosinophils (Figure 2). The pathologic diagnosis was Kimura's disease. The case was considered as ALPS by findings of hepatosplenomegaly, lymphadenopathy, immune hemolytic anemia, autoantibody positivity and increased double negative T cells. But the histopathologic findings of lymph node and the presence of eosinophilia with increased IgE level were confirmed to Kimura's disease.

Corticosteroid treatment may be used in both two clinical conditions. For this patient prednisolone therapy 2 mg/kg per day was started, continued for 4 weeks and then tapered off within three months. In the follow-up, the hepatosplenomegaly,

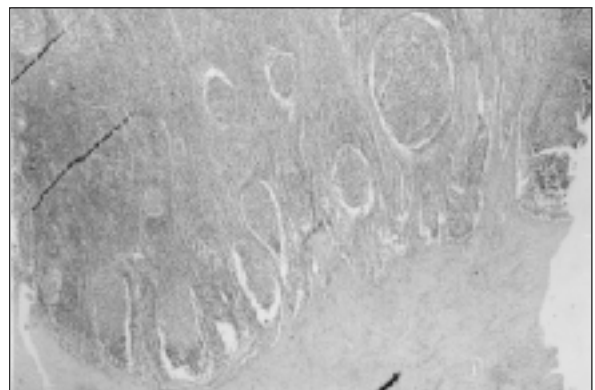

FIGURE 1: Prominent follicular hyperplasia and fibrous bundles penetrating the lymph node (HE, x40)

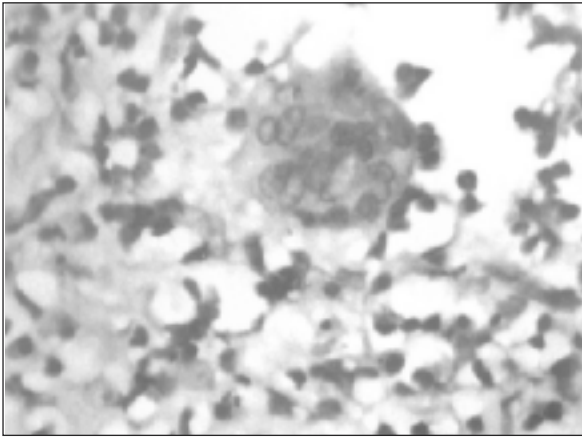


FIGURE 2: Prominent eosinophil infiltration and Warthin-Finkeldey like giant cell (HE, x40).

enlarged lymph nodes, immune hemolytic anemia and respiratory system findings had regressed within 3 months. The direct Coombs test became negative, the hemoglobin level was 10 g/dL, and hematocrite 27%. Ten months after the treatment our patient's clinical condition is well.

DISCUSSION

In the differential diagnosis of a child with generalized lymphadenopathy, hepatosplenomegaly and autoimmuncytopenia systemic infections, lymphoreticular malignancies and autoimmune diseases should be considered.⁶ The laboratory findings concerning infectious diseases and malignancies were negative in our patient. A positive result of the direct Coombs test, autoimmune hemolytic anemia, and thrombocytopenic purpura are the most common features of autoimmunity in patients with ALPS.⁷ In our patient the presence of hepatosplenomegaly, LAP and immune hemolytic anemia suggested the diagnosis of ALPS. Anticardiolipin antibody positivity and increased double negative T cells supported the diagnosis. But genetic analysis could not be performed.

The prevalence of KD is not known, but most cases are reported from the Far East. It is a benign chronic inflammatory disease that usually involves deep subcutaneous tissue and lymph nodes of the head and neck region. Other sites of involvement including the axilla, groin, limbs, and trunk have

also been described. Elevated serum immunoglobulin E levels and peripheral blood eosinophilia are also common. KD is histologically, enlarged germinal centers in the lymphoid follicles were prominent, and a large number of eosinophils had infiltrated around follicles. Polykaryocytes (Warthin-Finkeldey-type giant cells), eosinophils in germinal centers, eosinophilic folliculolysis can also be observed.⁴ Our patient in addition of the ALPS findings presented with eosinophilia and a high concentration of IgE in the peripheral blood. Severe infiltration by eosinophils and granulation in the stroma were observed in his enlarged lymph nodes. Enlarged germinal centers in the lymphoid follicles were prominent, and prominent eosinophil infiltration and Warthin-Finkeldey like giant cell. These findings were consistent with KD.

The differential diagnosis includes Hodgkin lymphoma, angioimmunoblastic T-cell lymphoma, Langerhans cell histiocytosis, florid follicular hyperplasia, Castleman disease, dermatopathic lymphadenopathy, Churg-Strauss syndrome, drug reaction, and parasitic lymphadenitis.⁸ Our patient had not taken any drugs, he had no positive parasitic serological findings. By histopathological features, these diseases were excluded. The most differential diagnosis of KD includes angiolymphoid hyperplasia with eosinophilia (ALHE) and hypereosinophilic syndrome ALHE usually occurs in Caucasians, and hypertrophic endothelial cells in the vessels are generally observed in histologic sections. In addition, the nodules (<1.5 cm) are usually smaller than in KD and there is no LAP.⁹ Hypereosinophilic syndrome shows a severe multiple systemic organ dysfunctions involving the heart and does not show LAP.¹⁰ On this basis, we concluded that KD was the most appropriate diagnosis.

The characteristic morphologic findings of KD are also defined in autoimmune disease cases in the literature.¹¹ The common finding of the 2 diseases is also observed in our case. Googe PB et al have been reported an adult case of KD with manifestations of a connective tissue disease (Hashimoto thyroiditis, keratoconjunctivitis sicca, and membranous glomerulonephritis).¹² Some of authors pro-

pose that KD represents an aberrant immune reaction to an as yet unknown stimulus.⁸ According to these literatures, autoimmune disease and KD may be found together.

As a result, the patients with generalized LAP, hepatosplenomegaly and autoimmune hematologic findings have to be evaluated histopathologically

and ALPS should be considered. Likewise, KD can be diagnosed with high serum IgE level, eosinophilia, generalized LAP and histopathological findings. In view of the fact that KD is associated with increased immune response and seen with other autoimmune diseases, we thought that co-existence of ALPS and KD was not incidental.

REFERENCES

1. van der Werff Ten Bosch J, Schotte P, Ferster A, Azzi N, Boehler T, Laurey G, et al. Reversion of autoimmune lymphoproliferative syndrome with an antimalarial drug: preliminary results of a clinical cohort study and molecular observations. *Br J Haematol* 2002; 117(1):176-88.
2. Oren H, Ozkal S, Gülen H, Duman M, Uçar C, Atabay B, et al. Autoimmune lymphoproliferative syndrome: report of two cases and review of the literature. *Ann Hematol* 2002; 81(11):651-3.
3. Türkanlı Asal G, Sanal SO. [Autoimmune lymphoproliferative syndrome]. *Turkiye Klinikleri J Pediatr Sci* 2007;3(4):18-22.
4. Hosaka N, Minato T, Yoshida S, Toki J, Yang G, Hisha H, et al. Kimura's disease with unusual eosinophilic epithelioid granulomatous reaction: a finding possibly related to eosinophil apoptosis. *Hum Pathol* 2002;33(5):561-4.
5. Chim CS, Fung A, Shek TW, Liang R, Ho WK, Kwong YL. Analysis of Clonality in Kimura's Disease. *Am J Surg Pathol* 2002;26(8):1083-6.
6. Straus SE, Sneller M, Lenardo MJ, Puck JM, Strober W. An inherited disorder of lymphocyte apoptosis: the autoimmune lymphoproliferative syndrome. *Ann Intern Med* 1999;130(7):591-601.
7. Rieux-Laucat F, Blachère S, Danielan S, De Villartay JP, Oleastro M, Solary E, et al. Lymphoproliferative syndrome with autoimmunity: A possible genetic basis for dominant expression of the clinical manifestations. *Blood* 1999; 94(8):2575-82.
8. Abuel-Hajja M, Hurford MT. Kimura disease. *Arch Pathol Lab Med* 2007;131(4):650-1.
9. Shenefelt PD, Rinker M, Caradonna S. A case of angiolymphoid hyperplasia with eosinophilia treated with intralesional interferon alfa-2a. *Arch Dermatol* 2000;136(7):837-9.
10. Sen T, Ponde CK, Udawadia ZF. Hypereosinophilic syndrome with isolated Loeffler's endocarditis: complete resolution with corticosteroids. *J Postgrad Med* 2008;54(2):135-7.
11. Hui PK, Chan JK, Ng CS, Kung IT, Gwi E. Lymphadenopathy of Kimura's disease. *Am J Surg Pathol* 1989;13(3):177-86.
12. Googe PB, Harris NL, Mihm MC Jr. Kimura's disease and angiolymphoid hyperplasia with eosinophilia: two distinct histopathological entities. *J Cutan Pathol* 1987;14(5):263-71.