

Role of Radical Surgery in the Treatment of Liver Hydatid Cyst

^{id} Sami AÇAR^a, ^{id} Erman ÇİFTÇİ^b

^aDepartment of General Surgery, University of Health Sciences Zeynep Kamil Women and Children's Diseases Training and Research Hospital, İstanbul, Türkiye

^bDepartment of Obstetrics and Gynecology, University of Health Sciences Zeynep Kamil Women and Children's Diseases Training and Research Hospital, İstanbul, Türkiye

ABSTRACT Cystic echinococcosis (CE), also known as hydatid disease, is a zoonotic disease that occurs when a parasite in the classification of cestoda, *Echinococcus granulosus*, transmits into the human body at the larval stage. It can be encountered in every stage of life, but mostly between 20-40 years. Approximately 60-70% of cysts develop in the liver mostly in the right lobe. It can grow in size between 1 to 5 cm per year. Usually, drainage and omentopexy are preferred after the cystotomy. Post-operative biliary fistula occurs in 30-50% of cases. When the cystic diameter is greater than 10 cm, the occurrence rate dramatically increases. In the case of a fistula that lasts longer than 10 days, it is defined as a permanent biliary fistula. A 35-year-old male patient diagnosed with stage 2 cystic echinococcosis developed post-operative cystobiliary fistula, its treatment procedure, and the treatment cost is presented.

Keywords: Echinococcosis; biliary fistula; endoscopic retrograde cholangiopancreatography; sphincterotomy

Cystic echinococcosis (CE) usually occurs where animal husbandry is common and the regulations are not strict accordingly. Echinococcosis has an incidence of 18-20 per 100 thousand people in our country.¹ It is also known that the prevalence rate in the society is 0.8-11% and 0.8-6.6% per 100 thousand in people who undergo surgery due to echinococcosis.^{2,3} Echinococcosis is usually (60-70%) located in the liver.

The ratio for the disease to be complicated is roughly 60%.⁴ The most important problem encountered is cystobiliary fistula. Major rupture occurs when the content of the cyst discharges to one of the great bile ducts. It can be detected in 5-20% of the patients preoperatively. Minor rupture manifests as a biliary fistula giving rise after a surgical or invasive procedure. Minor rupture can come across in 40% of the

cases.⁵ The incidence of cystobiliary fistula increases when cysts grow in diameter and are localized centrally in the liver.⁶

Even though being an infectious disease, echinococcosis warrants attention due to the lack of effective medical treatment options, the need for patients to undergo an invasive procedure, is labor-intensive, and, at the same time requiring significant resources, moreover having considerable mortality rate. To prevent the disease from the spread, the ways of the transmission have to be known well, precautions must be taken accordingly, and society must be informed. Apart from the side effects of the operation, the negative impact on the quality of life is a problem itself. Considering treatment costs and loss of labor, it puts a heavy burden on medical expenditures. By presenting the case of 2 intracystic drainages

Correspondence: Sami AÇAR

Department of General Surgery, University of Health Sciences Zeynep Kamil Women and Children's Diseases Training and Research Hospital, İstanbul, Türkiye

E-mail: acarrsami@yahoo.com



Peer review under responsibility of Türkiye Klinikleri Journal of Case Reports.

Received: 13 Aug 2021

Received in revised form: 13 Oct 2021

Accepted: 21 Oct 2021

Available online: 25 Oct 2021

2147-9291 / Copyright © 2022 by Türkiye Klinikleri. This is an open access article under the CC BY-NC-ND license (<http://creativecommons.org/licenses/by-nc-nd/4.0/>).

which couldn't be removed for 7 months due to the development of postoperative cystobiliary fistula, we aimed to exemplify the extent of change on the quality-of-life of the patient, the hardship of solution-oriented interventions, and the expenditure in the way of treatment. Informed consent was obtained from the patient for this case report.

CASE REPORT

A 35-year-old male patient was admitted with complaints of abdominal pain and fatigue. Cystic mass lesions in liver segments 4 and 6 were detected in computerized tomography (CT) (Figure 1). Considering the size and features of the cysts, interventional radiological procedures were not preferred. A subcostal incision on the right side of the abdomen and exploratory laparotomy were carried out. The cyst located on segment 6 of the liver was found to be perforated. For both of the cysts, drainage was performed with cystotomy. Cavities have been closed by omentopexy. During the operation, bile content couldn't be found in the cystic content. Jackson-Pratt drains, which have a diameter of 10 mm, were inserted into both of the cavities. Bile content started to come out of the drains the day after the surgery. During the 18-day-long clinical observation of the patient, there was bile leakage from drains with varying amounts. Those drains include the left drain located in the cystic cavity situated in segment 4 of the liver and the right drain located in the cystic cavity situated in segment 6 of the liver. The amount of bile leakage for each drain is 655 cc and 220 cc for left and right drains, respectively. The first endosco-

pic retrograde cholangiopancreatography (ERCP) procedure to treat cystobiliary fistula is performed after the 21st day of the surgery. During the procedure, leakage from the right lobe has been spotted. The procedure has terminated with a sphincterotomy operation. Each drain's flow was reduced on the 1st day to 140 and 50 cc for left and right drains, respectively. The flows reached the previous steady states for each of the drains during consecutive days. Five days after the 1st ERCP procedure, a 2nd ERCP is performed. During the operation, a plastic stent diameter of 10F and length of 10 cm were inserted into the common bile duct. During 51 days, left drain flow remained at an average of 600 cc, right drain flow remained at an average of 70 cc. Fifty two days after the 2nd ERCP, the 3rd ERCP procedure was performed. A 10F stent was replaced with a plastic stent diameter of 12F and length of 10 cm into the common bile duct. During the 101-days following, the left drain's flow decreased to the average of 85 cc, and the right drainage flow decreased to the average of 50 cc (Figure 2). The stent located in the common bile duct was removed in the 4th ERCP intervention 48 days after the 3rd ERCP procedure.

DISCUSSION

The patient of high socio-cultural status remained asymptomatic until the late stage of the disease. He had to take a break from work for 204 days. His quality of life has significantly deteriorated. He received 112 days of inpatient treatment. The patient was treated with 2 Jackson-Pratt drains for 190 days. During that time, he underwent 4 ERCP procedures, and

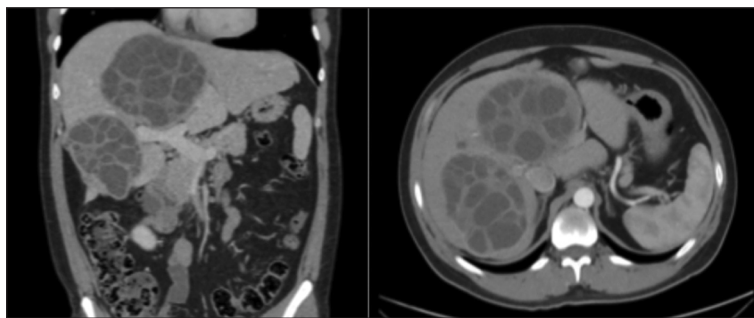


FIGURE 1: World Health Organization Informal Working Group on Echinococcosis classified hydatid cysts based on ultrasonographic imagery as active (CE1, CE2), transitional (CE3a, CE3b), and inactive (CE4, CE5) cysts. During the stages CE2 and CE3b, surgical treatment is indicated. CE2 hydatid disease according to ultrasonography larger than 15 cm in liver segments 4 and 6 in the preoperative period. Computerized tomography image of CE2 disease.

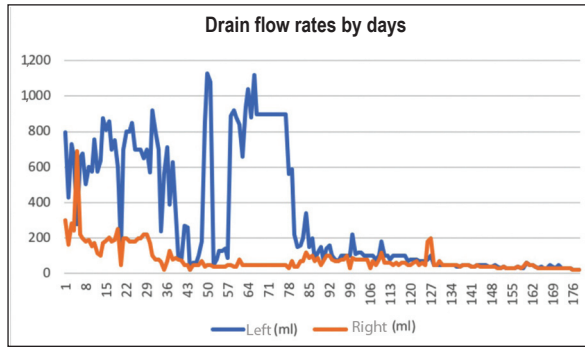


FIGURE 2: Flow rates of drains in the cyst lodge during the treatment process. **Blue:** Left drain (Segment 4 located cystotomy lodge). **Orange:** Right drain (Segment 6 located cystotomy lodge).

the stent placed in the common bile duct has been changed twice. He underwent magnetic resonance imaging 6 times and CT 4 times. He received antibiotic treatment for 88 days. There had been 38 biochemical tests and 6 antibiograms of the drain content done.

To decide which procedure to choose for the treatment, type of the cyst, localization and complicated or uncomplicated characteristics of the cyst should be considered. Surgical treatment is indicated for the cysts which are large in diameter, classified as an uncomplicated active and transitional stage, compressing surrounding vital organs, unable to treat percutaneously, and having cystobiliary communication.⁷ The main purpose of surgical treatment is to eliminate the parasite, preventing the relapse of the disease, and reduce complications and mortality.⁸ Fundamentals of conservative surgery consist of removal of the cystic content and leaving the pericyst partially or completely. Conservative surgeries are simpler and safer than radical surgeries. But this statement became controversial due to the complications emerging after the surgery and the long length of stay. Bile fistula is a hard-to-treat complication that manifests from conservative surgery.⁹ When emerges, it is hard to locate the biliary leakage area with a new operation. In this case, decreasing the mean basic pressure of the common bile duct should be the goal by placing the stent in the common bile duct with the help of ERCP-assisted-sphincterotomy. Mortality

rate is 0.5-1.5% and local risk of recurrence is 20-25% after the conservative surgery.^{10,11} Radical surgery consists of hepatectomy and pericystectomy, and it accounts for 10% of the overall surgical procedures. The procedure should be performed with special attention to not open the cyst and removing the cystic content or removal of the pericyst with or without removing the surrounding parenchyma. Post-operative morbidity has a rate of 3-30%.¹² The advantage of radical surgery is the lack of the probability of infection of the cavity and lower probability of bile fistula emergence (0-7.7%). The probability of the surgical wound infection is lower than 3%, and the recurrence rate is 0-6.4%.¹² Cystic echinococcosis patients with a longer cystic diameter of 10 cm, having the feature of multiple cysts, and cysts are closer to the center of the liver need a multidisciplinary approach. Radical surgery should be performed on those patients who have a high probability of emergence of the cistobiliary fistula.

Acknowledgements

Thanks to Dr. Erman Çiftçi for his support in the treatment process of the patient.

Source of Finance

During this study, no financial or spiritual support was received neither from any pharmaceutical company that has a direct connection with the research subject, nor from a company that provides or produces medical instruments and materials which may negatively affect the evaluation process of this study.

Conflict of Interest

No conflicts of interest between the authors and / or family members of the scientific and medical committee members or members of the potential conflicts of interest, counseling, expertise, working conditions, share holding and similar situations in any firm.

Authorship Contributions

Idea/Concept: Sami Açar; **Design:** Sami Açar; **Control/Supervision:** Sami Açar; **Data Collection and/or Processing:** Erman Çiftçi; **Analysis and/or Interpretation:** Sami Açar; **Literature Review:** Sami Açar; **Writing the Article:** Sami Açar; **Critical Review:** Sami Açar; **References and Findings:** Sami Açar; **Materials:** Sami Açar.

REFERENCES

1. McManus DP, Zhang W, Li J, Bartley PB. Echinococcosis. *Lancet*. 2003;362(9392): 1295-304. [[Crossref](#)] [[Pubmed](#)]
2. Yazar S, Ozkan AT, Hökelek M, Polat E, Yılmaz H, Ozbilge H, et al. Türkiye'de 2001-2005 yılları arasında kistik ekinokokkozis [Cystic echinococcosis in Turkey from 2001-2005]. *Türkiye Parazitol Derg*. 2008;32(3):208-20. Turkish. [[Pubmed](#)]
3. Romig T, Dinkel A, Mackenstedt U. The present situation of echinococcosis in Europe. *Parasitol Int*. 2006;55 Suppl:S187-91. [[Crossref](#)] [[Pubmed](#)]
4. Symeonidis N, Pavlidis T, Baltatzis M, Ballas K, Psarras K, Marakis G, et al. Complicated liver echinococcosis: 30 years of experience from an endemic area. *Scand J Surg*. 2013; 102(3):171-7. [[Crossref](#)] [[Pubmed](#)]
5. Atahan K, Küpeli H, Deniz M, Gür S, Cökmez A, Tarcan E. Can occult cystobiliary fistulas in hepatic hydatid disease be predicted before surgery? *Int J Med Sci*. 2011;8(4):315-20. [[Crossref](#)] [[Pubmed](#)] [[PMC](#)]
6. Kayaalp C, Bzeizi K, Demirbag AE, Akoglu M. Biliary complications after hydatid liver surgery: Incidence and risk factors. *J Gastrointest Surg*. 2002;6(5):706-12. [[Crossref](#)] [[Pubmed](#)]
7. Brunetti E, Kern P, Vuitton DA; Writing Panel for the WHO-IWGE. Expert consensus for the diagnosis and treatment of cystic and alveolar echinococcosis in humans. *Acta Trop*. 2010;114(1):1-16. [[Crossref](#)] [[Pubmed](#)]
8. Tagliacozzo S, Miccini M, Amore Bonapasta S, Gregori M, Tocchi A. Surgical treatment of hydatid disease of the liver: 25 years of experience. *Am J Surg*. 2011;201(6):797-804. [[Crossref](#)] [[Pubmed](#)]
9. Daradkeh S, El-Muhtaseb H, Farah G, Sroujeh AS, Abu-Khalaf M. Predictors of morbidity and mortality in the surgical management of hydatid cyst of the liver. *Langenbecks Arch Surg*. 2007;392(1):35-9. [[Crossref](#)] [[Pubmed](#)]
10. Georgiou GK, Lianos GD, Lazaros A, Harissis HV, Mangano A, Dionigi G, et al. Surgical management of hydatid liver disease. *Int J Surg*. 2015;20:118-22. [[Crossref](#)] [[Pubmed](#)]
11. Yorganci K, Sayek I. Surgical treatment of hydatid cysts of the liver in the era of percutaneous treatment. *Am J Surg*. 2002;184(1): 63-9. [[Crossref](#)] [[Pubmed](#)]
12. Ramia JM, Ruiz-Gomez F, De la Plaza R, Veguillas P, Qui-ones J, Garcia-Parre-o J. Ambispective comparative study of two surgical strategies for liver hydatidosis. *World J Gastroenterol*. 2012;18(6):546-50. [[Crossref](#)] [[Pubmed](#)] [[PMC](#)]