

# Concurrent Pre-Diagnosis Epilepsy and WPW Syndrome in Two Siblings Presenting with Syncope: Case Report

## Eşzamanlı Epilepsi ve WPW Sendromu Öntanılarını Olan Senkop ile Başvuran İki Kardeş

Zeynep BAŞTUĞ GÜL,<sup>a</sup>  
Yakup ERGÜL,<sup>b</sup>  
Hüseyin Altuğ ÇAKMAK,<sup>c</sup>  
Mehmet GÜL<sup>d</sup>

<sup>a</sup>Clinic of Neurology,  
Bakırköy Prof. Dr. Mazhar Osman  
Hospital of Mental Health and Neurology,

<sup>b</sup>Clinic of Pediatric Cardiology,

<sup>c</sup>Clinic of Cardiology,  
Mehmet Akif Ersoy Cardiovascular and  
Thoracic Surgery Center,  
Training and Research Hospital,  
İstanbul

<sup>d</sup>Clinic of Cardiology,  
Rize Kackar Government Hospital,  
Rize

Geliş Tarihi/Received: 13.08.2015

Kabul Tarihi/Accepted: 01.02.2016

Yazışma Adresi/Correspondence:  
Mehmet GÜL  
İstanbul Mehmet Akif Ersoy  
Cardiovascular and Thoracic Surgery  
Training and Research Hospital,  
Clinic of Cardiology, İstanbul,  
TÜRKİYE/TURKEY  
dmg23@gmail.com

**ABSTRACT** Patients with WPW syndrome may present with palpitations, syncope, or sudden cardiac death. An epileptic seizure is a clinically discernible event, which results from the synchronous and excessive discharge of a group of neurons in the cerebral cortex. Epilepsy and WPW Syndrome may lead to similar clinical symptoms in the same age groups. These cases are interesting in terms of differential diagnosis of WPW syndrome and epilepsy in siblings with recurrent syncope attacks.

**Key Words:** Epilepsies, myoclonic; syncope; Wolff-parkinson-White syndrome

**ÖZET** WPW sendromlu hastalar çarpıntı, senkop veya ani kardiyak ölüm ile karşımıza çıkabilir. Epileptik nöbet serebral korteksteki bir grup nöronun senkron ve aşırı deşarjından kaynaklanan farkedilebilir klinik bir olaydır. Epilepsi ve WPW Sendromu, aynı yaş gruplarında benzer klinik belirtilere yol açabilir. Tekrarlayan senkop atakları olan kardeşlerde WPW Sendromu ve epilepsi ayırıcı tanısı açısından olgular ilgi çekicidir.

**Anahtar Kelimeler:** Epilepsiler, miyoklonik; Senkop; Wolff-Parkinson-White Sendromu

**Türkiye Klinikleri J Cardiovasc Sci 2015;27(3):111-3**

Wolff-Parkinson-White (WPW) Syndrome and epilepsy, which are usually seen in the same age group, are important etiological factors for syncope. Diagnosis and treatment approaches are very important in both settings which lead to similar findings.

### CASE REPORT

Seven years old male sibling had a history of recurrent syncope attacks at home. The patient was assessed for etiology of syncope in elective setting by neurologist. Cranial magnetic resonance imaging (MRI) and electroencephalographic (EEG) examination were normal. The diagnosis of atonic epileptic attack according to patient history and physical examination and sodium valproic acid was prescribed. However, patient's symptoms continue under valproic acid treatment. Moreover, he was referred to cardiologist when an electrocardiogram (ECG) revealed Wolff-Parkinson-White (WPW) Syndrome (Figure 1a). An electrophysiological study (EPS) was performed for his recurrent syncope attacks, which may be triggered by

pre-excitatory pathways. Due to the occurrence of an accessory pathway efficient refractory period (APERP) of 260 msn in EPS, and pre-excited R-R interval (Afib preexc RR) of 227 msn in triggered atrial fibrillation, an ablation procedure was performed during the same session. Hemodynamic status of patient impaired during AF attack. The cryoablation procedure was successfully performed to the right posteroseptal region, accompanied by the EnSite NavX electroanatomical mapping system.

Since there was a history of out-of hospital several syncope attacks in 17 years old female sibling, she was assessed by neurologists. The diagnosis of myoclonic epilepsy was made according to patient history and physical examination and sodium valproic acid was prescribed. The EEG examination and cranial MRI showed normal findings; however the patient's ECG showed WPW Syndrome (Figure 1b). After that, the patient was assessed by cardiologist and EPS was planned for differential diagnosis and risk stratification. In EPS, the APERP and Afib preexc RR interval were found to be 310 msn and 346 msn, respectively. In contrast with the previous sibling, an ablation procedure was not performed for her low risk of arrhythmia. Before valproic acid treatment, this patient had approximately two syncope attacks in a year and had myoclonic jerks which recurred

every 2 weeks. Syncope attack was not repeated under treatment with valproic acid over the long term follow-up. Since patient had low risk for WPW syndrome as a result of EPS procedure, these complaints were assumed to epilepsy.

## DISCUSSION

Syncope, a transient loss of consciousness, is a common clinical problem. Vasovagal syncope, which is the most common cause of syncope (61-80%), is a self-treated benign disorder that sometimes disrupts the quality of health. The other causes of syncope were cardiac and neurogenic mechanisms including epilepsy. Patients with WPW syndrome may present with palpitations, syncope, or sudden cardiac death. The condition is often sporadic and of unknown etiology in the majority of cases. An epileptic seizure is a clinically discernible event, which results from the synchronous and excessive discharge of a group of neurons in the cerebral cortex. One of the important separating features of epileptic seizure and vasovagal syncope are precipitant factors, prodromal symptoms, and complaints during the attack, as well as symptoms after the episode, which help in differentiating between seizure and syncope. Loss of consciousness precipitated by pain or occurring after exercise, micturition, defecation, or stressful events is generally due to syncope, whereas an aura may precede a seizure. At least 5 minutes of the loss of consciousness, disorientation after the event, and slowness in return to consciousness suggest a seizure. While syncope can result in seizure-like activity, rhythmic movements such as clonic or myoclonic jerks are precede seizures.

Cranial magnetic resonance imaging (MRI) and EGG were important for diagnosis. However, as our cases, these diagnostic modalities show normal findings in some settings, which history taking and physical treatment help to elucidate underlying pathophysiology.<sup>1</sup> In first sibling, since having a high risk in EPS procedure and unresponsive setting for valproic acid, cardiac etiologies were assumed. Antiepileptic treatment was stopped after ablation procedure and no complaints were seen in the follow-up term. Moreover, second sib-

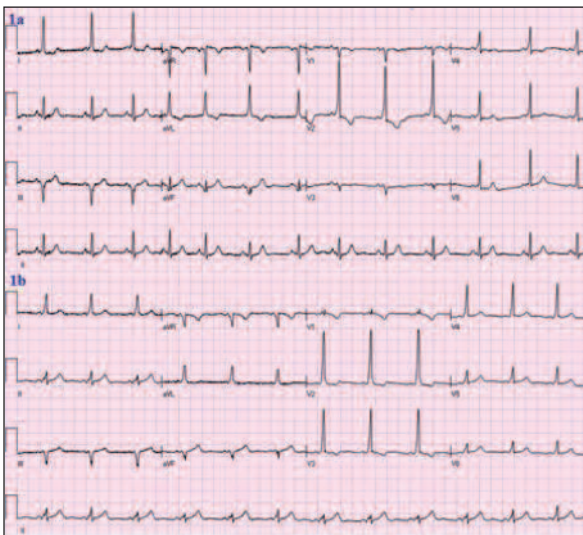


FIGURE 1a, b: Baseline ECG recordings of two brothers.

ling had a low risk in EPS procedure and had a responsive for valproic acid. The symptoms of this sibling were assumed to epilepsy because of these peculiarities. WPW Syndrome is one of the causes of cardiac syncope, especially in young populations, while epilepsy and WPW Syndrome may lead to similar clinical symptoms in the same age groups. Because of the normal findings of the EEGs and cranial MRIs for the two siblings, differential diagnoses were very difficult. While the genetic inheritance of epilepsy is well known, there is very limited information for the genetic inheritance of WPW in the literature. In addition, cerebral hypoxia, which may be caused by cardiac diseases, leads to epileptic attacks.<sup>2</sup> Channelopathies are a heterogeneous group of disorders which result from the malfunction of ion channels located in the membranes or many cellular organelles of cardiac cells. These disorders include the nervous system (e.g., generalized epilepsy with febrile seizures, familial hemiplegic migraine, episodic ataxia, and hyperkalemia and hypokalemic periodic paralysis), the cardiovascular system (e.g., long QT syndrome, Brugada syndrome, and catecholaminergic polymorphic ventricular tachycardia [CPVT]). Especially, cardiac channelopathies, such as long QT syndrome and CPVT, can be misdiagnosed as refractory epilepsy when in fact these events represent convulsive syncope. There was no sudden cardiac death history in siblings family in terms of

cardiac channelopathies. Precise knowledge and suspicion for these arrhythmogenic conditions may expedite early diagnosis which improves short and long term outcomes. Genetic researches are very important both to understand the basic mechanisms of epilepsy and to investigate new drugs for this setting. Most mutations in epilepsies have been identified in ion channel genes without structural brain abnormalities. Targeted molecular diagnosis is now available for different forms of epilepsy.<sup>3</sup>

Epileptic disorders and cardiogenic syncope may both manifest with convulsions, loss of consciousness, and loss of postural tone, leading to a high level of misdiagnosis. The one-lead ECG during video-EEG monitoring is a key component, which may allow correct diagnosis and treatment.<sup>4</sup> While electrocardiographic record is important during patient symptoms, holter rhythm and loop recorder devices are used to capture life threatening cardiac events. EPS and ablation procedure are basic and important modalities for risk stratification and treatment of WPW. Although vasovagal reflex is the most important cause of syncope, cardiogenic and neurogenic mechanisms were also considered in pediatric and puberty periods. Because of the different treatment modalities for epileptic attacks and cardiac syncope, their differential diagnoses are very crucial to improve short and long term prognoses.

## REFERENCES

1. Köksal A, Öztürk M, Sözmen V, Altunkaynak Y, Baybaş S, Sütpideler NH. The classification of outpatients of the epilepsy clinic according to the ILAE systems for seizure and epilepsy types. *Epilepsi* 2004;10(3):149-53.
2. Panduranga P, Al-Farqani A, Al-Rawahi N. Atrial fibrillation with wide QRS tachycardia and undiagnosed Wolff-Parkinson-White syndrome: diagnostic and therapeutic dilemmas in a pediatric patient. *Pediatr Emerg Care* 2012;28(11):1227-9.
3. Guerrini R, Marini C, Mantegazza M. Genetic epilepsy syndromes without structural brain abnormalities: clinical features and experimental models. *Neurotherapeutics* 2014;11(2):269-85.
4. Mayor LC, Lemus HN, Burneo J, Palacio AC, Linares S. Cardiogenic syncope diagnosed as epileptic seizures: the importance of ECG during video-EEG recording. *Epileptic Disord* 2015;17(2):198-203.