

Doxycycline Induced Esophageal Ulcer: Case Report

Doksisiklin Kullanımına Bağlı Özofagus Ülseri

Irmak SAYIN, MD,^a
Şahin DOĞANAY, MD,^a
Halil DEĞERTEKİN, MD^b

Departments of
^aInternal Medicine,
^bGastroenterohepatology,
Ufuk University Faculty of Medicine,
Ankara

Geliş Tarihi/Received: 21.10.2008
Kabul Tarihi/Accepted: 20.12.2008

*Abstract of this article was presented
as a poster at 10th National Internal
Medicine Congress.*

Yazışma Adresi/Correspondence:
Irmak SAYIN, MD
Ufuk University Faculty of Medicine,
Department of Internal Medicine,
Ankara,
TÜRKİYE/TURKEY
irmaksayin@yahoo.com

ABSTRACT Although not frequent in medical literature, pill-induced esophageal injury is an important condition because of its possible complications. It is well established that certain drugs have the potential to cause esophageal mucosal injury. A 33 year old female patient appeared in our outpatient clinic with the complaints of sudden onset odynophagia, retrosternal burning sensation, and nausea. She first realized retrosternal pain following the first dose of doxycycline tablets prescribed by the department of Obstetrics & Gynecology. With the presenting features, esophagogastroduodenoscopy was planned. With the endoscopic findings, the patient was diagnosed with pill-induced esophageal injury resulting from doxycycline treatment, and the doxycycline treatment was stopped. She also was put on a lansoprazole 30 mg bid regimen, during the following three days, her symptoms improved. Although not frequently encountered in the clinical practice, pill-induced esophageal injury should be kept in mind as an important complication of certain drug therapies.

Key Words: Doxycycline; esophagitis; deglutition disorders

ÖZET İlaça bağlı özofagus hasarı literatürde sık görülmemekle birlikte yol açabileceği komplikasyonlar açısından önemli bir durumdur. Özofagus mukozasında hasar oluşumuna özellikle bazı ilaçların yol açtığı iyi bilinmektedir. 33 yaşında bayan hasta kliniğimize ani ortaya çıkan disfaji, retrosternal yanma hissi ve bulantı şikayetleri ile başvurdu. Retrosternal yanmanın Jinekoloji & Obstetrik kliniği tarafından başlanan doksisiklin tabletinin ilk dozundan sonra başladığını ifade etti. Bu bulgularla özofagogastroduodenoskopi planlandı. Endoskopik bulgular sonucunda, hastaya doksisiklin tedavisi sonucunda gelişen özofagus ülseri tanısı kondu ve tedavi durduruldu. Lansoprazol 30 mg bid tedavisi başlandı, takip eden 3 gün içerisinde hastanın şikayetleri geriledi. Klinikte sık karşılaşılmamasına rağmen, belirli bazı ilaç gruplarının yol açabileceği ilaca bağlı özofagus hasarı mutlaka akılda tutulması gereken bir durumdur.

Anahtar Kelimeler: Doksisiklin; özofajit; yutma bozuklukları

Türkiye Klinikleri J Gastroenterohepatol 2009;16(2):80-3

Esophageal injury resulting from pills is not a common entity in medical literature. Missed or misdiagnosis of the cases together with underreporting may contribute to the low incidence of pill-induced esophageal injury. However, it is well established that certain drugs have a propensity for causing esophageal mucosal injury.¹ Among these medicines, tetracycline, doxycycline, clindamicine, potassium chloride, quinidine, barium sulphate, and emepronium bromide are noteworthy; and 90% of the cases present in the literature are reported to be related to the medici-

nes listed above.^{2,3} In this article, we present a case of pill-induced esophageal injury who developed an esophageal ulcer resulting from doxycycline treatment.

CASE REPORT

A 33 year old female patient appeared in our outpatient clinic with the complaints of sudden onset odynophagia, retrosternal burning sensation, and nausea. A careful history revealed that, she had not had any dyspeptic complaints until 4 days ago, when she first realized retrosternal pain following the first dose of doxycycline tablets prescribed by the department of Obstetrics & Gynecology. On questioning further, she also declared that she had taken the pill with a little amount of water and the timing for the pill had been just before the bedtime. Even though she had not continued taking the pills, her odynophagia, retrosternal burning, nausea, and mid-esophagus pain complaints did not improve, and she sought medical help. With the presenting features, esophagogastroduodenoscopy was planned. Patient provided written informed consent and confirmed her willing to go esophagogastroduodenoscopy. During the procedure it was observed that, superficial ulcers covered with exudative membranes were clustered on a normally appearing mucosa in the mid-esophageal region (Figure 1). Multiple biopsies were performed. The distal part of the esophagus and the stomach appeared normal. With these findings, the patient was

diagnosed with pill-induced esophageal injury resulting from doxycycline treatment, and the doxycycline treatment was stopped. She also was put on a lansoprazole 30 mg bid regimen and was counseled to consume liquid food. During the following three days, her symptoms improved a lot, and after 6 weeks of treatment, a control esophagogastroduodenoscopy was performed. This time, the esophagogastroduodenoscopy demonstrated a totally normal esophageal mucosa (Figure 2).

DISCUSSION

Pill-induced esophageal injury is a well established but also an easy to miss complication of certain drugs. Although not encountered frequently, it may cause important morbidity in parallel with the extent of mucosal injury.⁴ Due to the absence of simple and noninvasive diagnostic procedures, the exact incidence of this complication with certain drugs is not known yet.⁵ Drug and patient related factors contribute to the occurrence of mucosal damage. The chemical nature and solubility of the drug, and its contact time with the esophageal mucosa are important drug related factors. Especially pills coated with a gelatinous material tend to adhere to esophageal mucosa, when taken with a limited amount of water.⁶ Esophageal motility disorders, esophageal strictures, and consumption of a limited amount of water with the pills are patient related factors.⁴ Lesions of pill-induced esophageal injury are frequently encountered at the

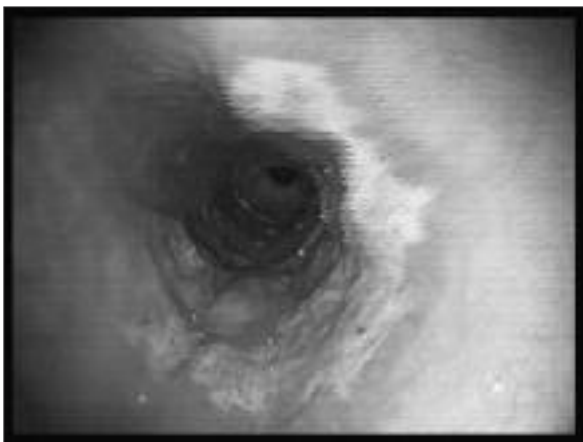


FIGURE 1: Before treatment.

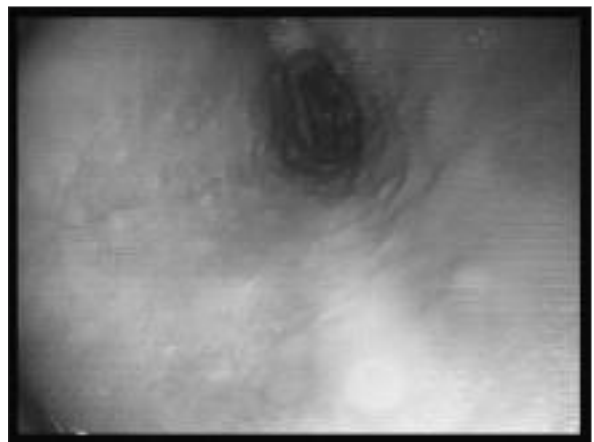


FIGURE 2: After treatment.

physiological narrowings of the esophagus, namely the mid-esophagus and the lower esophageal sphincter.⁷ Typical symptoms of pill-induced esophageal injury are sudden onset odynophagia and retrosternal burning sensation (pyrosis).^{8,9} While the most sensitive method for the diagnosis of pill-induced esophageal injury is esophagogastroduodenoscopy, the most common finding on endoscopy is the presence of single or multiple superficial ulcers surrounded by a normally appearing mucosa. These ulcers, which may be scattered may also form clusters, and although they are usually small in size, they may sometimes reach a size of a few centimeters. On some occasions, only inflammatory changes may be observed without any apparent ulcerations, and pieces of the pill may be present on the edges of these lesions. Although rare, deeper ulcers may also be observed. Ulcers penetrating the large vasculature or the mediastinum may cause serious life-threatening complications as hemorrhage or mediastinitis. Being nonpathognomonic, the biopsies show only non specific esophagitis with necro-inflammatory changes. Because of this reason, in the presence of a compatible history and typical endoscopic findings, there may be no need for obtaining biopsies.^{4,10,11}

The main approach for the treatment of pill-induced esophageal injury is the withdrawal of the offending drug and the addition of symptomatic treatment.¹² The need or the efficiency of a specific treatment for the acute mucosal lesion is not clear. However, in order to block the irritative effect of gastric acid on the existing lesions, antacids, histamine H2 receptor blockers, proton pump inhibitors, and sucralfate have been used empirically.

Although worries about its toxic side effects limits its use, viscous lidocaine may be helpful as a topical anesthetic agent in patients with serious odynophagia. Odynophagia may also bring about the need for parenteral fluid administration, or in lengthy cases the need for total parenteral nutrition may become evident. In uncomplicated cases, most of the pain of the mucosal lesions diminishes in days to weeks. While the acute esophageal stricture and dysphagia caused by the inflammation and edema regresses spontaneously, bougie dilatation of the chronic fibrotic strictures may be needed.^{1,9} On the occasion of complications such as esophageal perforation or hemorrhage, specific therapy must be implemented immediately. To emphasize again, the most important steps for the treatment of pill-induced esophageal injury are, correct and timely diagnosis, and the avoidance of the offending drug.¹²

As a conclusion, although not frequently encountered in the clinical practice, pill-induced esophageal injury should be kept in mind as an important complication of certain drug therapies, because of its potential serious complications. In order to prevent this complication, the patients should be counseled to take the offending drugs with plenty of water, and to keep a sitting or standing position while taking the pills and afterwards. In cases appearing with complaints of sudden onset odynophagia and retrosternal burning, following the start of a medical therapy, pill-induced esophageal injury must be remembered and after the completion of the appropriate diagnostic procedures, immediate medical treatment must be implemented.

REFERENCES

1. Castell OD. Medication-Induced Esophagitis. In: Rose BD, ed. UpToDate, 8.1 (CD version). Wellesly, MA: UpToDate Inc, 2000.
2. Bott S, Prakash C, McCallum RW. Medication-induced esophageal injury: survey of the literature. *Am J Gastroenterol* 1987;82(8):758-63.
3. Yaşa MH, Bektaş A, Özkan S, et al. [Esophagitis due to drugs]. *Gastroenteroloji* 1996;7(Ek 1):41.
4. Baehr PH, McDonald GB. Esophageal disorders caused by infection, systemic illness, medications, radiation, and trauma. In: Feldman M, Scharschmidt BF, Sleisenger MH, eds. *Gastrointestinal and Liver Disease*. 6th ed. Philadelphia: WB Saunders; 1998. p.519-39.
5. Kikendall JW, Johnson LF. Pill-induced esophageal injury . In: Castell DO, ed. *The Esophagus*. 2nd ed. Boston: Little Brown; 1995. p. 619.
6. Hey H, Jørgensen F, Sørensen K, Hasselbalch H, Wamberg T. Oesophageal transit of six commonly used tablets and capsules. *Br Med J (Clin Res Ed)* 1982;285(6356):1717-9.

7. Kikendall JW. Pill esophagitis. J Clin Gastroenterol 1999;28(4):298-305.
8. Eng J, Sabanathan S. Drug-induced esophagitis. Am J Gastroenterol 1991;86(9):1127-33.
9. İşler M, Bahçeci M, Aksakal G. [Doxycycline-induced esophageal ulceration: report of two cases]. Türkiye Klinikleri J Gastroenterohepatol 2001;12(3):191-3.
10. Kikendall JW. Pill-induced esophagitis. In: Brandt LJ, ed. Clinical Practice of Gastroenterology. 1st ed. Philadelphia: Current Medicine, Inc; 1999. p.91-6.
11. Yılmaz Ö, Bilgiç Y, Bilen Y, Okçu N. [Doxycycline induced esophageal injury: case report]. Türkiye Klinikleri J Med Sci 2008;28(4):569-71.
12. Ovarlamporn B, Kulwichit W. Tetracycline-induced esophageal ulcer: a condition that probably more common than it appears to be. J Med Assoc Thai 1991;74(10):443-7.