

# Inflammatory Pseudotumor in the Posterior Cervical Region: Case Report

## Posterior Servikal Bölgede İnflamatuvar Psödötümör

Sema ZER TOROS, MD,<sup>a</sup>  
Çınar AKKAYNAK, MD,<sup>a</sup>  
Barış NAİBOĞLU, MD,<sup>a</sup>  
Şerike AKKAYNAK, MD,<sup>b</sup>  
Hülya KAHVE NOSHARI, MD,<sup>a</sup>  
Senem ESEN, MD,<sup>a</sup>  
Erol EGELİ, MD<sup>a</sup>

<sup>a</sup>Departments of <sup>a</sup>Otorhinolaryngology,  
Head and Neck Surgery  
<sup>b</sup>Pathology, Haydarpaşa Numune  
Hospital, İSTANBUL

Geliş Tarihi/Received: 15.11.2006  
Kabul Tarihi/Accepted: 18.01.2007

Yazışma Adresi/Correspondence:  
Sema ZER TOROS, MD  
Haydarpaşa Numune Hospital,  
Department of Otorhinolaryngology,  
Head and Neck Surgery, İSTANBUL  
semazertoros@yahoo.com

**ABSTRACT** Inflammatory pseudotumor (IP) is an uncommon non-neoplastic lesion of unknown etiology. Although seen in all age groups in the pediatric population, this tumor is most commonly found in the lungs. We report a very rare case of IP involving the posterior cervical region in a 12 year-old child. To the best of our knowledge, it is one of the few cases described in the neck. It has a distinct histological appearance and benign clinical course. IP must be considered in the differential diagnosis of neck masses because it can easily be misdiagnosed as a malignancy.

**Key Words:** Granuloma, plasma cell; histiocytoma, benign fibrous

**ÖZET** İnflamatuvar psödötümör (İP), etiolojisi bilinmeyen, nadir nonneoplastik bir lezyondur. Pediatrik grupta tüm yaş gruplarında ve en sık akciğerlerde görülür. Biz 12 yaşında bir çocukta, posterior servikal bölgeye yerleşmiş, nadir bir İP olgusu sunuyoruz. Bizim literatür bilgilerimize göre, bu olgu boyunda yerleşen birkaç olgudan biridir. Farklı bir histolojik görünümü ve benign klinik gidişi vardır. İP yanlışlıkla malignite olarak teşhis edilebileceği için, boyun kitlelerinin ayrıntı tanısında akılda tutulmalıdır.

**Anahtar Kelimeler:** Granülom, plazma hücresi; histiositoma, benign fibröz

**Türkiye Klinikleri J Med Sci 2008, 28:239-242**

Inflammatory pseudotumor (IP) is a pathological term that has been used to describe an inflammatory fibrosing tumor forming process.<sup>1</sup> It is a rare lesion of unknown etiology that most commonly occurs in the lung.<sup>2</sup> It may occur anywhere in the body including the liver, spleen, soft tissue, skin, orbita, lacrimal glands, salivary glands and lymph nodes.<sup>3</sup> In the head and neck region, it most frequently includes the orbita, but may also occur in the larynx, paranasal sinuses, parapharynx, infratemporal fossa, cheek, mandible and the cervical spine.<sup>2,4</sup>

It was first observed by Brunn in 1939, and Umiker et al in 1954 coined the term IP because of its ability to both clinically and radiologically mimic a malignancy. Berardi et al found up to 19 different names within the literature.<sup>5</sup> It has a variety of synonyms including plasma cell granuloma, histiocytoma, fibrous xanthoma, xanthomatous pseudotumor, inflamma-

tory myofibroblastic tumor, but the term most often used is IP.<sup>3</sup>

The etiology and pathogenesis remains controversial.<sup>1,3</sup>

A few reports described pediatric inflammatory myofibroblastic tumors involving the trachea and the neck.<sup>5</sup> We present a case of IP in a 12-year-old girl at the posterior cervical region of the neck, which is a rare location for IP.

### CASE REPORT

A 12-year-old girl presented with a 1-year history of a slowly enlarging swelling in the right posterior cervical region. This caused mild discomfort but she was otherwise symptom-free. At the time of presentation, there was a 2 x 2 x 3 cm mobile, painless, and welldefined mass at the posterior border of the lower 1/3 portion of the sternocleidomastoid muscle. Examination of the ears, nose and throat were normal. There were no laboratory test abnormalities.

Ultrasound examination revealed a welldefined, hypoechogenic and heterogenic mass at the right posterior cervical region, which suggested lymphoma.

Fine needle aspiration cytology showed reactive lymphoid hyperplasia, which was suggestive of granuloma. For definitive diagnosis, excisional biopsy of the mass was planned. Surgery was performed under general anesthesia. Postoperative pathology was consistent with inflammatory pseudolymphoma. The patient has been followed up for the last three years and there has been no evidence of recurrence.

### PATHOLOGY

The lymph node material was fixed in Bovin's solution and was routinely processed. Paraffine sections were stained with hematoxylin and eosin.

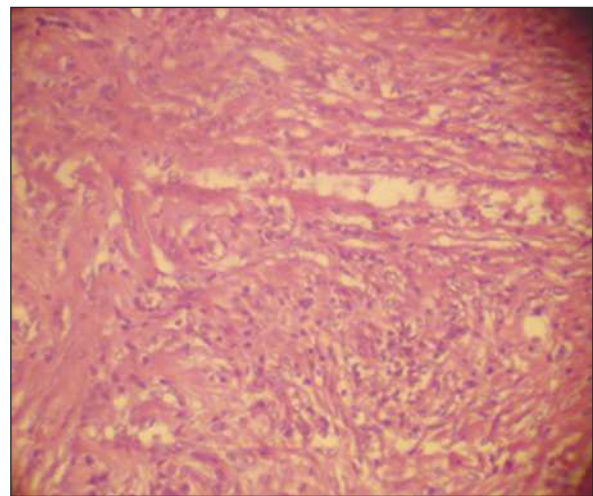
In microscopic sections, the nodal capsule trabeculae and hilus were expanded by sclerosed mesenchymal tissue containing blandlooking spindly cells, small blood vessels, and inflammatory cells (mainly plasma cells and lymphocytes combined

with some immunoblasts, eosinophils and neutrophils)

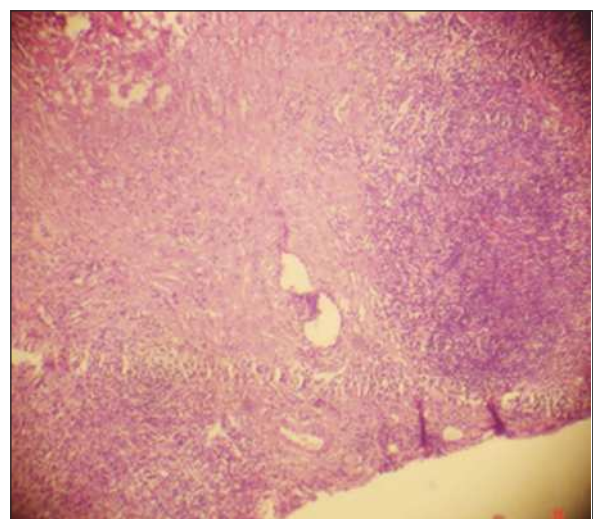
The lesion had the appearance of anastomosing cords connected to the hilum as multiple nodules. The spindly and polygonal cells were arranged in a vague fascicular or storiform pattern and comprised a mixture of histiocytes (Figure 1, Figure 2).

### DISCUSSION

IP is a term first introduced by Perrone et al to describe an inflammatory and/or fibrosing tumorlike



**FIGURE 1:** There is marked broadening of the connective tissue framework of the node (pole areas) (HEX40).



**FIGURE 2:** The lesion is characterized by spindly cells with a vague storiform pattern, branching capillaries or venules and chronic inflammatory cells (HEX100).

process that may involve many organs ranging from the lungs to the abdominal organs, skin, soft tissues, and lymph nodes.<sup>3,6</sup> IP is a distinct, yet heterogeneous group of mesenchymal tumors composed of various proportions of myofibroblasts, hyalinized collagenous stroma, and admixed inflammatory cells.<sup>7</sup> The age of the patients ranged from 19 months to 63 years.<sup>2</sup>

This tumor may mimic a severe disease because of its clinical presentation and morphological features, but its clinical behavior is benign.<sup>6</sup> The local recurrences, distant metastases, clonal chromosomal aberrations, and even sarcomatous progression in a small number of cases suggest that these lesions are potentially malignant.<sup>5</sup> We observed the current case for 3 years and she had no distant metastasis and recurrence.

Although the etiology of this tumor is controversial, some authors suggest that an inflammatory reaction secondary to trauma, autoimmune reaction, or infection may play a role.<sup>5</sup> The process was considered a primary immunologic lesion, a fibrogenetic disorder, a neoplasm, or a specific acute reaction secondary to infectious agents. Thus, IP may be described as a modality of response to different stimulants rather than the expression of a single agent.<sup>6</sup>

The disease presentation does not seem to be influenced by age, sex and ethnic background. It may either have an acute onset with high fever or an insidious, longer, and intermittent course. In the latter form, the disease is self-limited with localized and asymptomatic lymphadenopathy, in which case, nodal excision may be curative.<sup>6</sup>

In our case, there was no history of trauma or infection. It was a chronic process of 1-year duration rather than an acute reaction. She had no concurrent organ involvement or accompanying systemic symptoms such as fever, fatigue, or weight loss. Laboratory tests showed no abnormality; thus, nodal excision was sufficient for the treatment.

IP is a diagnosis of exclusion.<sup>5</sup> It has no distinctive characteristics either clinically or radiographi-

cally. Hence, a diagnosis of pseudotumor can be made only after other specific disorders are completely eliminated.<sup>4</sup>

Because of its local invasiveness, tendency to recurrence, and marked cellularity, even the experienced pathologist may misdiagnose these tumors as neoplasms such as fibrosarcoma, rhabdomyosarcoma, infantile myofibromatosis, and Hodgkin's lymphoma. Preoperative recognition is extremely important to avoid radical resection, radiation, and chemotherapy.<sup>6</sup>

Differential diagnosis includes nonspecific reactive hyperplasia, granulomatous lymphadenitis, Castleman's disease, virus related reaction versus T-cell lymphoma, Hodgkin's lymphoma, autoimmune disease, soft tissue sarcoma, rhabdomyosarcoma, and infantile myofibromatosis.<sup>2,5,6</sup>

In our case, preoperative fine needle aspiration biopsy suggested lymphoid hyperplasia or granuloma. The mass was removed completely under general anesthesia and yielded the definitive diagnosis of IP.

Weisman and Osguthorp reported that CT, MRI and ultrasound could be extremely helpful in differentiating IP from other inflammatory lesions and from neoplasms. However, many other reports suggest that CT and MRI are unable to differentiate between pseudotumor and a benign or malignant tumor.<sup>1,2</sup> Thus, a tissue biopsy is necessary for diagnosis.<sup>5</sup> In our clinical case, the only radiological test performed was the ultrasound examination of the posterior cervical region, and it was consistent with lymphoma.

IPs are rarely associated with recurrence. A few cases have been aggressive and patient death has been reported with liver IP.<sup>1</sup> IP is histologically benign and has never been reported to metastasize.<sup>4</sup>

Treatment options include surgical excision, radiotherapy and steroids or a combination of these depending on the location of the mass, the degree of invasion into surrounding tissues, and the possibility of complete resection.<sup>1,4,5</sup> Most cases are treated with surgical excision due to misdiagnosis of malignancy (as in our case).

The response to steroid therapy is known to be related to histological classification- the higher the chronic fibrosis, the less effective the response to steroid therapy.<sup>4</sup> Radiotherapy may be used in cases where steroid therapy yields no response, where there is relapse soon after treatment or where a high dose of steroid is contraindicated.<sup>4</sup> Surgical removal may be considered where complete resection is possible without damaging the neighboring structures.<sup>4</sup>

According to Trevenzoli et al, glucocorticosteroids are the treatment of choice. Cyclosporine and

novel agents such as alltrans retinoic acid derivatives that have demonstrated several regulatory effects on morphogenesis and cell differentiation may have a future therapeutic role.<sup>6</sup>

The overall prognosis of IP is excellent. Most recurrences occur within 1 year of initial surgery, with only a few reports of late recurrences. Follow up should be at regular intervals during the first year. Although extremely rare, sarcomatous transformation is possible and should be kept in mind during follow up.<sup>5</sup>

## REFERENCES

- 1 Mathews J, Nicol A, Dingle AF. Inflammatory pseudotumour in the submandibular region. *J Laryngol Otol* 2001;115:502-3.
- 2 Inui M, Tagawa T, Mori A, Yoneda J, Nomura J, Fukumori T. Inflammatory pseudotumor in the submandibular region. Clinicopathologic study and review of the literature. *Oral Surg Oral Med Oral Pathol* 1993;76:333-7.
- 3 Mielcarek MW, Bates C, Uppal S, Nadig S, Coatesworth AP. Benign inflammatory pseudotumour of the parotid gland: a case report and literature review. *Int J Clin Pract* 2004;58:527-9.
- 4 Cho YS, Kim SM, Chung WH, Hong SH. Inflammatory pseudotumour involving the skull base and cervical spine. *J Laryngol Otol* 2001;115:580-4.
- 5 Browne M, Abramson LP, Chou PM, Acton R, Holinger LD, Reynolds M. Inflammatory myofibroblastic tumor (inflammatory pseudotumor) of the neck infiltrating the trachea. *J Pediatr Surg* 2004;39:e1-4.
- 6 Trevenzoli M, Cattelan AM, Lanzafame M, Sasset L, Concia E, Vento S. Inflammatory pseudotumor of lymph nodes. *Ann Med Interne (Paris)* 2003;154:557-9.
- 7 El Shabrawi-Caelen L, Kerl K, Cerroni L, Soyer HP, Kerl H. Cutaneous inflammatory pseudotumor-a spectrum of various diseases? *J Cutan Pathol* 2004;31:605-11.