

Assessment of the Accuracy of the Multi Detector Computed Tomography in Defining Renal Artery Before Laparoscopic Donor Nephrectomy

Accuracy of Tomography for Renal Artery

Laparoskopik Donor Nefrektomi Öncesi Renal Arteri Tanımlamada Çok Dedektörlü Bilgisayarlı Tomografinin Doğruluğunun Değerlendirilmesi

Renal Arteri Tanımlamada Tomografinin Doğruluğu

Burhan COŞKUN,^a
Onur KAYGISIZ,^a
Kerem ÖZTÜRK,^b
Ahmet MERT,^a
Kadir Ömür GÜNSEVER,^a
Ayşegül ORUÇ,^c
Yakup KORDAN,^a
Hakan VURUŞKAN,^a
İsmet YAVAŞCAOĞLU^a

Departments of
^aUrology,
^bRadiology,
^cNephrology,
Uludağ University Faculty of Medicine,
Bursa

Geliş Tarihi/Received: 25.10.2017
Kabul Tarihi/Accepted: 07.11.2017

Yazışma Adresi/Correspondence:
Burhan COŞKUN
Uludağ University Faculty of Medicine,
Department of Urology, Bursa,
TURKEY/TÜRKİYE
coskunburhan52@gmail.com

ABSTRACT Objective: Renal transplantation is the most effective treatment option for end stage renal disease. Because of severe organ shortage, living kidney donors are important choices for transplantation. Evaluation of vascular anatomy of living donor's kidney before nephrectomy is essential to perform a successful procedure. Computed tomography angiography which is noninvasive and effective is preferred for evaluation in many centers. In this study we aimed to compare the results of the multi detector CT angiography (MDCTA) with operation findings in patients who underwent live renal transplantation. **Material and Methods:** Living kidney donors between January 2008 and December 2015 were evaluated retrospectively. MDCTA findings and operation notes were compared. **Results:** A total 110 living kidney donors (50.57 ± 12.26 years, 46.4% male) were evaluated. Renal artery anatomic variations were detected in 27.3% and 31% of right and left kidneys, respectively. The accuracy of the MDCTA was 95.4% and 98.2% regarding renal artery and early branching of the artery, respectively. **Conclusion:** MDCTA is serving an accurate modality in preoperative assessment of renal arteries before laparoscopic donor nephrectomy.

Keywords: Kidney transplantation; living donors; renal artery; tomography, x-ray computed; angiography

ÖZET Amaç: Böbrek nakli, son dönem böbrek yetmezliğinde en etkili tedavi seçeneğidir. Kadaverik organ havuzun yetersizliğinden dolayı canlı böbrek nakli önemlidir. Canlı verici böbreklerinin vasküler anatomisinin nefrektomi öncesi değerlendirilmesi başarılı bir ameliyat için gereklidir. Birçok merkezde değerlendirme için noninvaziv ve etkin olan bilgisayarlı tomografi (BT) anjiyografi tercih edilir. Bu çalışmada canlı böbrek nakli yapılan vericilerde multi dedektör BT anjiyografi (MDBTA) bulgularının ameliyat bulguları ile karşılaştırılması amaçlandı. **Gereç ve Yöntemler:** Ocak 2008 ile Aralık 2015 arasında canlı böbrek vericileri retrospektif olarak değerlendirildi. MDBTA bulguları ve ameliyat notları karşılaştırıldı. **Bulgular:** Toplam 110 canlı böbrek vericisi (50.57 ± 12.26 yıl, %46.4 erkek) değerlendirildi. Renal arterin anatomik varyasyonları sırasıyla sağ ve sol böbrekler için %27.3 ve %31 oranında tespit edildi. MDBTA'nın doğruluğu sırasıyla renal arter ve arterin erken dallanması ile ilgili olarak %95.4 ve %98.2 idi. **Sonuç:** MDTBA, laparoskopik verici nefrektomi öncesi renal arterlerin preoperatif değerlendirilmesinde uygun bir yöntemdir.

Anahtar Kelimeler: Böbrek transplantasyonu; canlı vericiler; renal arter; tomografi, x-ray bilgisayarlı; anjiyografi

Renal transplantation is the most effective treatment option for end stage renal disease.¹⁻³ As a consequence of the industrialized world more patients are being diagnosed with end stage renal disease predominantly due to diabetes and hypertension.⁴ Although the numbers of the patients in the waiting list for renal transplantation are increasing, kidney donation from deceased patients is not sufficient.^{5,6}

Live kidney donation is an alternative method to deceased donation. Graft survival rates of the live kidney transplantation is found to be longer than the deceased kidney transplantation.⁷ Today, the kidney can be harvested from the live donors laparoscopically which provides a better comfort and cosmetic appearance at post-operative period which has resulted and increase in numbers of live donation.⁸

Preoperative assessments before donor nephrectomy is extremely important not only for safety of the donor, also important for the success of the operation.⁹ Outstandingly, accurate determination of renal vessel anatomy is essential. Conventional, computed tomography (CT) or magnetic resonance imaging (MRI) angiography are available for this purpose.¹⁰ Today, CT angiography has replaced conventional angiography in many of the centers.⁹

In this study we aimed to compare the results of the multi detector CT angiography (MDCTA) with operation findings in patients who underwent live renal transplantation.

MATERIAL AND METHODS

Following an approval (2016-18/9) from the institutional ethical committee the medical records of the patients who underwent LDN between January 2008 and December 2015 were retrospectively reviewed. The study was performed in accordance with Helsinki Declaration. The patients with CT angiography record in patient achieving and communication system were included in the study. A radiologist reassessed CT angiography images without any information regarding operation notes of the patients. Then, the radiological findings were compared with the operation notes. Three experienced laparoscopic surgeons performed all of the laparoscopic nephrectomy (LPN) operations.

IMAGING PROTOCOL

All of the imaging was performed with 64 multi-detector-row computed tomography (MDCT), (Somatom Definition 64; Siemens Medical Solutions, Erlangen, Germany). Imaging protocol included non-contrast and excretory images from upper margin of the kidney to the lower end of the blad-

der; arterial images starting from dome of the diaphragm to the middle of the sacrum and nephrogenic images of the same area with 0.6 mm slices. Non contrast images were used to diagnose nephrolithiasis or non-enhanced density of the mass lesions.

Axial images with 5 mm. were assessed routinely. Constructed images from 0.6 mm. slices were assessed in coronal and sagittal planes at working station (Leonardo; Siemens Medical Solutions, Malvern, PA) (Figure 1).

The terminology for definition of other renal arteries besides the main renal artery is presented below.

Polar artery: This refers to an additional artery which originating from the aorta and directly piercing the upper or the lower pole of the kidney.

Accessory artery: This refers to an additional renal artery which does not consistent with a polar renal artery.

Early branching: This refers to diverging of the main artery in a distance of ≤ 1.5 cm from its origin at the abdominal aorta.

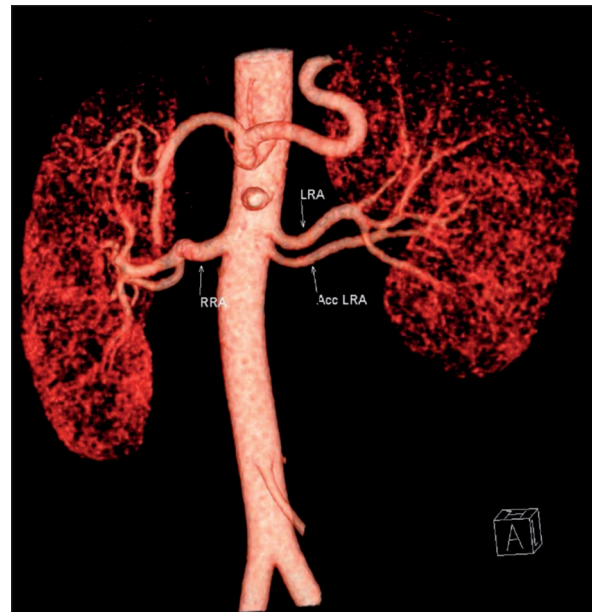


FIGURE 1: Constructed images of a donor with a left accessory renal artery. RRA: right renal artery, LRA: left renal artery, Acc LRA: left accessory renal artery.

STATISTICAL METHOD

The data was analyzed by using SPSS statistical software version 23.0 (SPSS Inc., Armonk, NY, USA). Chi square and Fisher's Exact test was used for comparison between surgical and radiological findings. A p value of 0.05 or less were considered significant. The surgical findings were considered as the reference point for calculation of sensitivity, specificity and the accuracy of MDCTA.

RESULTS

A total of 216 patients underwent laparoscopic donor nephrectomy (LDN) during the study period. The total number of patients with an available record at patient achieving and communication system was 110. The mean age of the patients was 50.57 ± 12.26 years, 51 (46.4%) patients were male and 59 (53.6%) were female. There was no supernumerary artery in 80 (72.7%) and 76 (69%) patients' right and left kidneys respectively. The numbers of supernumerary and early branching arteries obtained with MDCTA are listed in Table 1. A total of 82 (74.6%) left kidney and 28 (25.4%) right kidney were transplanted.

Comparison of the MDCTA findings with the operation notes regarding renal artery is presented in Table 2. The sensitivity and the specificity of the MDCTA were 97.8% (90/92) and 83.3% (15/18) respectively. The accuracy of the MDCTA was 95.4% (105/110).

Table 3 shows comparison of the MDCTA findings with operation notes regarding early branching of the artery. The sensitivity and the specificity of the MDCTA were 98.9% (96/97) and

TABLE 1: The numbers of the main artery only, supernumerary arteries and early branching arteries.

	Right Kidney	Left Kidney
One artery	80 (72.7%)	76 (69%)
Accessory artery	14 (12.7%)	16 (14.5%)
2 nd Accessory artery	1 (0.9%)	-
Polar artery	10 (9%)	11(10%)
2 nd Polar artery	1 (0.9%)	1 (0.9%)
Early branching	7 (6.3%)	10 (9%)

TABLE 2: Comparison of MDCTA with operation findings regarding the number of the artery on transplanted kidney.

MDCTA Findings	Operation Findings		Total
	Single artery	Multiple artery	
Single artery	90	3	93
Multiple	2	15	17
Total	92	18	110

P<0.001

MDCTA: Multi detector computed tomography angiography.

TABLE 3: Comparison of MDCTA with operation findings regarding presence of "early branching" on transplanted kidney.

MDCTA Findings	Operation Findings		Total
	Not Present	Present	
Not Present	96	1	97
Present	1	12	13
Total	97	13	110

P<0.001

MDCTA: Multi detector computed tomography angiography.

92.3% (12/113) respectively. The accuracy of the MDCTA was 98.2% (108/110).

DISCUSSION

Normal arterial pattern of the kidney includes a single artery. However, variations are not infrequent. This phenomenon is mainly due to embryonic ascent of the kidney.^{11,12}

In our series the rate of supernumerary arteries were 27.3% and 31% in arteries of the right and left kidneys respectively, according to the MDCTA. These rates were in accordance with other series carried out either in cadaver or imaging series. In a retrospective review of imaging and cadaveric series, Satayapal et al. reported a median rate of 28.1% for supernumerary arteries.¹³ The rate of multiple arteries in Turkish population was found to be 27% in review of 820 patients with MDCTA.¹⁴

It is highly important to have an idea of whether if there is an anomaly in renal artery before performing a renal surgery. This is much more important in renal transplantation surgeries.¹⁵ It is ideal to transplant the kidney with single artery.

There are conflicting reports regarding the outcomes of renal transplantation with multiple arteries. Hemorrhagic and thrombotic complications can occur where multiple arteries are anastomosed.¹⁶ However, there are other reports with finding no difference in outcomes of anastomosis with single and multiple arteries.¹⁷

Renal angiogram was the previous gold standard imaging method for pre-operative determination of the renal vasculature.¹⁸ Since introduction of the high quality axial imaging modalities such as MDCTA and MRI angiography; these modalities became popular due to non-invasive their nature.¹⁹ MDCTA is fast, and has additional advantage of ability to diagnose urinary stones or renal masses with higher rates of donor compliance.^{20,21}

The main purpose of the present study was to review confirmation of the MDCTA findings with operation notes in patients undergoing live donor renal transplantation. The sensitivity and the specificity of the MDCTA for detecting extra arteries were calculated as 97.8% and 83.3% respectively. The accuracy of the MDCTA was 95.4%. Our findings were in accordance with the other studies in the literature. Kawamoto et al. reported a sensitivity and specificity rate of 65-88% and 96-100% respectively.²² Similarly, Hainen et al. reported a sensitivity rate of 93% and specificity of 100% with an accuracy rate of 98%.¹⁵ While the rate of accuracy for detecting accessory arteries with one-channel CT angiography technique found to range between 78-89% this rate was reported as 89-97% with MDCTA.^{9,22}

Three patient reported to have a single artery on MDCTA had found to have multiple arteries at surgery (two polar and one accessory arteries) Also, no multiple arteries notice in operation two patients with a report of a polar artery on MDCTA.

When the results were compared for the early branching of the renal artery the sensitivity and the specificity of the MDCTA were 98.9% and 92.3% respectively. The accuracy of the MDCTA was 98.2%.

Also, these findings were in accordance with other reports in the literature. In Kawamoto's series the sensitivity, specificity and the accuracy rates for the detection of early branching were 90%,97% and 96% respectively. The rate of accuracy for early branching was reported between 89-99%.

Since the left renal vein is longer than the right renal vein it is easier to make an easier vein anastomosis with the left-kidney. For this reason, in our clinic we prefer to choose the left kidney in live renal transplantation if the arteries of both kidney is equal and there is no major difference in functionality of the kidney. The rate of left kidney for transplantation was 74.6% in our series.

The kidneys with more complex arterial anatomy were not considered as potential donors. This makes the main limitation of the present study. It is possible to have increased numbers of conflicts between MDCTA findings with operation notes when these kidneys were considered.

CONCLUSION

In conclusion MDCTA is serving an accurate modality in preoperative assessment of renal arteries before laparoscopic donor nephrectomy.

Conflict of Interest

Authors declared no conflict of interest or financial support.

Authorship Contributions

Idea/Concept: Burhan Coşkun, Onur Kaygısız, Kerem Öztürk, Ayşegül Oruç; **Design:** Yakup Kordan, Hakan Vuruşkan, İsmet Yavaşcaoğlu, Burhan Coşkun, Kerem Öztürk, Ahmet Mert; **Control/Supervision:** Yakup Kordan, Hakan Vuruşkan, İsmet Yavaşcaoğlu; **Data Collection:** Kerem Öztürk, Ahmet Mert, Ayşegül Oruç, Kadir Ömür Günseren, Onur Kaygısız; **Analysis and/or Interpretation:** Kerem Öztürk, Burhan Coşkun, Ahmet Mert, Ayşegül Oruç, Kadir Ömür Günseren; **Literature Review:** Onur Kaygısız, Kadir Ömür Günseren; **Writing the Article:** Burhan Coşkun; **Critical Review:** Burhan Coşkun, Onur Kaygısız, Kerem Öztürk, Ahmet Mert, Kadir Ömür Günseren, Ayşegül Oruç, Yakup Kordan, Hakan Vuruşkan, İsmet Yavaşcaoğlu; **References and Findings:** İsmet Yavaşcaoğlu, Hakan Vuruşkan, Yakup Kordan.

REFERENCES

- Suthanthiran M, Strom TB. Renal transplantation. *N Engl J Med* 1994;331(6):365-76.
- Abecassis M, Bartlett ST, Collins AJ, Davis CL, Delmonico FL, Friedewald JJ, et al. Kidney transplantation as primary therapy for end-stage renal disease: a National Kidney Foundation/Kidney Disease Outcomes Quality Initiative (NKF/KDOQI) conference. *Clin J Am Soc Nephrol* 2008;3(2):471-80.
- Wolfe RA, Ashby VB, Milford EL, Ojo AO, Ettenger RE, Agodoa LY, et al. Comparison of mortality in all patients on dialysis, patients on dialysis awaiting transplantation, and recipients of a first cadaveric transplant. *N Engl J Med* 1999;341(23):1725-30.
- Stevens LA, Viswanathan G, Weiner DE. Chronic kidney disease and end-stage renal disease in the elderly population: current prevalence, future projections, and clinical significance. *Adv Chronic Kidney Dis* 2010;17(4):293-301.
- Nathan HM, Conrad SL, Held PJ, McCullough KP, Pietroski RE, Siminoff LA, et al. Organ donation in the United States. *Am J Transplant* 2003;3 Suppl 4:29-40.
- Persijn GG, Smith M, de Vries E, de Boer J, Smits J, Cohen B. Trilogi 2001 symposium: tackling the organ shortage problem. *Transplant Proc* 2002;34(7):2553-5.
- Nemati E, Einollahi B, Lesan Pezeshki M, Porfarziani V, Fattahi MR. Does kidney transplantation with deceased or living donor affect graft survival? *Nephrourol Mon* 2014;6(4):e12182.
- Ratner LE, Montgomery RA, Kavoussi LR. Laparoscopic live donor nephrectomy: the four year Johns Hopkins University experience. *Nephrol Dial Transplant* 1999;14(9):2090-3.
- Ghonge NP, Gadanayak S, Rajakumari V. MDCT evaluation of potential living renal donor, prior to laparoscopic donor nephrectomy: what the transplant surgeon wants to know? *Indian J Radiol Imaging* 2014;24(4):367-78.
- Halpern EJ, Mitchell DG, Wechsler RJ, Outwater EK, Moritz MJ, Wilson GA. Preoperative evaluation of living renal donors: comparison of CT angiography and MR angiography. *Radiology* 2000;216(2):434-9.
- Tardo DT, Briggs C, Ahern G, Pitman A, Sinha S. Anatomical variations of the renal arterial vasculature: an Australian perspective. *J Med Imaging Radiat Oncol* 2017;61(5):643-9.
- Shakeri AB, Tubbs RS, Shoja MM, Pezeshk P, Farahani RM, Khaki AA, et al. Bipolar supernumerary renal artery. *Surg Radiol Anat* 2007;29(1):89-92.
- Satyapal KS, Haffjee AA, Singh B, Ramsaroop L, Robbs JV, Kalideen JM. Additional renal arteries: incidence and morphometry. *Surg Radiol Anat* 2001;23(1):33-8.
- Gümüş H, Bükte Y, Ozdemir E, Cetiçakmak MG, Tekbaş G, Ekici F, et al. Variations of renal artery in 820 patients using 64-detector CT-angiography. *Ren Fail* 2012;34(3):286-90.
- Hänninen EL, Denecke T, Stelter L, Pech M, Podrabsky P, Pratschke J, et al. Preoperative evaluation of living kidney donors using multirow detector computed tomography: comparison with digital subtraction angiography and intraoperative findings. *Transpl Int* 2005;18(10):1134-41.
- Osman Y, Shokeir A, Ali-el-Dein B, Tantawy M, Wafa EW, el-Dein AB, et al. Vascular complications after live donor renal transplantation: study of risk factors and effects on graft and patient survival. *J Urol* 2003;169(3):859-62.
- Benedetti E, Troppmann C, Gillingham K, Sutherland DE, Payne WD, Dunn DL, et al. Short- and long-term outcomes of kidney transplants with multiple renal arteries. *Ann Surg* 1995;221(4):406-14.
- Bia MJ, Ramos EL, Danovitch GM, Gaston RS, Harmon WE, Leichtman AB, et al. Evaluation of living renal donors. The current practice of US transplant centers. *Transplantation* 1995;60(4):322-7.
- Mandelbrot DA, Pavlakis M, Danovitch GM, Johnson SR, Karp SJ, Khwaja K, et al. The medical evaluation of living kidney donors: a survey of US transplant centers. *Am J Transplant* 2007;7(10):2333-43.
- Rydberg J, Kopecky KK, Tann M, Persohn SA, Leapman SB, Filo RS, et al. Evaluation of prospective living renal donors for laparoscopic nephrectomy with multisection CT: the marriage of minimally invasive imaging with minimally invasive surgery. *Radiographics* 2001;21 Spec No:S223-36.
- Falesch LA, Foley WD. Computed tomography angiography of the renal circulation. *Radiol Clin North Am* 2016;54(1):71-86.
- Kawamoto S, Montgomery RA, Lawler LP, Horton KM, Fishman EK. Multidetector CT angiography for preoperative evaluation of living laparoscopic kidney donors. *AJR Am J Roentgenol* 2003;180(6):1633-8.