

Plasma Homocysteine Levels in Patients with Pseudoexfoliation

Psödoeksfoliyasyonlu Olgularda Plazma Homosistein Düzeyleri

Arif Taylan ÖZTÜRK, MD,^a
Gül ARIKAN, MD,^b
Filiz KURALAY, MD,^c
Üzeyir GÜNENÇ, MD^b

^aClinic of Ophthalmology,
Dr. Behçet Uz Child's Diseases and Child
Surgery Education and Research Hospital,
Departments of
^bOphthalmology,
^cBiochemistry,
Dokuz Eylül University Faculty of Medicine,
İzmir

Geliş Tarihi/Received: 23.11.2010
Kabul Tarihi/Accepted: 14.03.2011

This study was presented as a poster at
6th International Glaucoma Symposium (I.G.S.),
28-31 March 2007, Greece.

Yazışma Adresi/Correspondence:
Arif Taylan ÖZTÜRK, MD
Dr. Behçet Uz Child's Diseases and Child
Surgery Education and Research Hospital,
Clinic of Ophthalmology, İzmir,
TÜRKİYE/TURKEY
ataylan6@yahoo.com

ABSTRACT Objective: To evaluate plasma homocysteine (Hcy) levels in patients with pseudoexfoliation syndrome, pseudoexfoliation glaucoma, primary open angle glaucoma and healthy control subjects. **Material and Methods:** Twenty patients with primary open angle glaucoma (POAG), twenty patients with pseudoexfoliation (PEX) glaucoma, twenty patients with PEX syndrome and twenty control subjects were enrolled. Mean plasma Hcy levels of four groups were determined using high-performance-liquid-chromatography and were compared. Then all participants were classified into two groups as subjects with or without PEX and were compared. Patients who had any history of a systemic disease known to be associated with high plasma Hcy levels and taking vitamin B supplements within the previous year were excluded. **Results:** Of the 80 patients, 43 were females (53.75%) and 37 were males (46.25%). Mean age was 69.11±8.53 years. Mean plasma Hcy levels were 19.02±10.66 µmol/l, 19.13±17.76 µmol/l, 10.58±3.50 µmol/l and 9.92±2.59 µmol/l in patients with PEX syndrome, PEX glaucoma, POAG and control subjects, respectively. Hcy levels in patients with PEX glaucoma were significantly higher when compared to POAG patients and the control group (p=0.025, p=0.004, respectively). Hcy levels in patients with PEX syndrome were also significantly higher when compared to POAG patients and the control group (p=0.001, p=0.000, respectively). Hcy levels in patients with POAG were not statistically different from the control group (p=0.365). When the patients were classified into two groups as subjects with or without PEX, mean plasma Hcy levels were found as 19.08±14.44 µmol/l and 10.25±3.06 µmol/l, respectively (p=0.000). **Conclusion:** Hcy levels were found to be significantly higher in PEX with or without glaucoma.

Key Words: Hyperhomocysteinemia; exfoliation syndrome; glaucoma

ÖZET Amaç: Psödoeksfoliyasyon sendromu, psödoeksfoliyasyon glokomu, primer açık açılı glokom ve sağlıklı kontrol olgularında plazma homosistein düzeylerini belirlemek. **Gereç ve Yöntemler:** Yirmi primer açık açılı glokomlu (PAAG), yirmi psödoeksfoliyasyon (PE) glokomlu, yirmi PE sendromlu olgu ve yirmi kontrol olgusu çalışmaya alındı. Yüksek performanslı sıvı kromatografisi kullanılarak dört grubun ortalama plazma homosistein düzeyleri belirlendi ve karşılaştırıldı. Daha sonra bütün çalışma grupları PE olan ve olmayan gruplar olarak ayrılarak karşılaştırıldı. Yüksek plazma homosistein düzeyleri ile ilişkili olduğu bilinen sistemik bir hastalık öyküsü olan hastalar ve vitamin B preparatlarından son bir yıl içinde kullandığı bilinenler çalışma dışında tutuldu. **Bulgular:** Seksen olgunun 43'ü (%53.75) kadın, 37'si (%46.25) erkekti. Hastaların yaş ortalaması 69.11±8.53 yıl idi. Ortalama plazma homosistein değeri PE sendromu, PE glokomu, PAAG ve kontrol grubunda, sırasıyla, 19.02±10.66 µmol/l, 19.13±17.76 µmol/l, 10.58±3.50 µmol/l and 9.92±2.59 µmol/l idi. PE glokomlu hastalarda plazma homosistein değerleri PAAG hastaları ve kontrol grubu ile karşılaştırıldığında anlamlı derecede yüksek bulundu (p=0.025, p=0.004, sırasıyla). PE sendromlu hastalarda plazma homosistein değerleri POAG hastaları ve kontrol olguları ile karşılaştırıldığında anlamlı derecede yüksek bulundu (p=0.001, p=0.000, sırasıyla). PAAG'lı hastaların plazma homosistein değerleri kontrol grubu ile karşılaştırıldığında anlamlı fark bulunmadı (p=0.365). Çalışma grupları PE'si olan ve olmayanlar olarak ikiye ayrıldıklarında ortalama plazma homosistein değerleri, sırasıyla, 19.08±14.44 µmol/l ve 10.25±3.06 µmol/l (p=0.000) olarak bulundu. **Sonuç:** Plazma homosistein değerleri eşlik eden glokomu olan ve olmayan PE'li olgularda daha yüksek bulundu.

Anahtar Kelimeler: Hiperhomosisteinemi; dökülme sendromu; glokom

doi:10.5336/medsci.2010-21924

Copyright © 2011 by Türkiye Klinikleri

Türkiye Klinikleri J Med Sci 2011;31(5):1204-10

Pseudoexfoliation (PEX) syndrome is an age-related disorder characterized by production and progressive accumulation of extracellular fibrillar material in various ocular tissues such as corneal endothelium, lens surface, trabecular meshwork, zonula, ciliary body, iris and anterior vitreous. This extracellular matrix material may also accumulate in the connective tissue portions of visceral organs and the skin. It is the most common identifiable cause of secondary open angle glaucoma and it is associated with an increased risk of complications during intraocular surgery. Although its pathogenic mechanism and clinical importance remain poorly understood, PEX material that contains the main components of elastic microfibrils such as elastin and fibrillin-I, is correlated with hypertension, angina, myocardial infarction and stroke.^{1,2} Strong correlation between elevated serum homocysteine (Hcy) levels and occlusive vascular disorders has been shown.¹⁻³ It promotes vascular endothelial injury, myointimal hyperplasia, hypertrophy, raised sulfated glycosaminoglycan deposition, collagen synthesis, fibrosis and calcification of atherosclerotic plaques.^{4,5}

Hyperhomocysteinemia is a well-known risk factor for retinal vascular disease including central retinal vein occlusion, central retinal artery occlusion and nonarteritic ischemic optic neuropathy.⁶⁻¹³ Apoptotic cell death of retinal ganglion cells induced by Hcy is a hypothetical risk factor for primary open angle glaucoma (POAG).¹⁴ Moreover, Hcy causes dysregulation of matrix metalloproteinases (especially MMP-2 and MMP-9) and their tissue inhibitors (TIMP-1 and TIMP-3 are increased, TIMP-4 is decreased by Hcy) that has been implicated in the pathogenesis of PEX glaucoma.¹⁵⁻¹⁷ Bleich et al., Leibovitch et al. and Clement et al. determined elevated plasma Hcy levels in patients with PEX glaucoma, however Vessani et al.¹⁸⁻²¹ noted significantly higher plasma Hcy levels in both glaucomatous and nonglaucomatous patients with PEX.

Abnormal plasma Hcy levels may be caused by genetical or nutritional factors. Deficiencies in the enzymes or the cofactors of them such as magnesium, folic acid, vitamin B₆ and B₁₂ that involve the

pathway of the metabolism of methionine via Hcy to cysteine are important determinants of elevated concentration of Hcy.²² Homozygous or heterozygous thermolabile methylene tetrahydrofolate reductase (MTHFR) 677 C-T polymorphism are the most common etiological factors to cause moderate hyperhomocysteinemia.^{7,10,20,23}

Our aim in this study is to evaluate plasma Hcy levels in patients with PEX syndrome, PEX glaucoma and POAG in Turkish population.

MATERIAL AND METHODS

This case-control study included 20 patients with PEX glaucoma, 20 with PEX syndrome, 20 with POAG along with 20 control subjects. All participants were examined at Ophthalmology Department of Dokuz Eylül University School of Medicine between June 2005 to June 2006. This study was conducted in accordance with the standards of the local Ethics Committee, the methods described adhered to tenets of the Declaration of Helsinki and all subjects gave their written informed consent prior to enrollment.

A detailed medical history was obtained to identify patients with systemic disorders such as diabetes mellitus, hypertension, cardiovascular disorders, cerebrovascular events, renal disease, endocrinological disorders and current drug therapy. The control group was selected from the subjects attending to Ophthalmology outpatient clinic who had similar gender and age with no ocular disease except refractive error, cataracts and strabismus. All participants were Turkish and underwent a complete eye examination including slit lamp biomicroscopy, testing for best corrected visual acuity, Goldmann applanation tonometry, gonioscopy, Humphrey visual field analysis with fundoscopic and optic nerve head examinations. None of the four study groups had any history of systemic disease known to be associated with high plasma Hcy levels (e.g. diabetes mellitus, recent myocardial infarction, malignancies, chronic renal failure, hypothyroidism). The patients treated with drugs which may affect the plasma Hcy level (methotrexate, fibrates, carbamazepine, phenytoin, postmenopausal hormone replacement therapies and

vitamin supplements especially include B₆, B₁₂ and folate) were also excluded.

To be included in the study, POAG patients had to have open angle on gonioscopy, elevated intraocular pressure (IOP > 21 mmHg) measured via a Goldmann applanation tonometry, characteristic glaucomatous optic nerve damage (including one or more of the following: excavation, notching, focal or diffuse atrophy of neuroretinal rim area, vertical cup-disc ratio more than 0.5, cup-disc asymmetry between fellow eyes greater than 0.2, or disc hemorrhage) and a glaucomatous visual field defect (including abnormal glaucoma hemifield test result and a pattern standard deviation (PSD) outside 95% of normal limits) in at least one eye on standart automated perimetry (full-threshold or Swedish Interactive Threshold Algorithm – SITA strategy, program 30-2, Humphrey Field Analyser). Diagnosis of PEX syndrome was based on the presence of typical exfoliation material on the pupillary margin or anterior lens capsule with peripupillary atrophy in one or both eyes with IOP < 22 mmHg, normal visual field and no evidence of glaucomatous change in optic nerve head. PEX glaucoma was diagnosed if the slit lamp examination revealed deposition of exfoliation material with the presence of typical glaucomatous optic nerve damage, elevated IOP (> 21 mmHg), an open angle in gonioscopic examination and glaucomatous visual field defect in at least one eye. Control healthy subjects had no history of ocular disease, normal IOP (< 22 mmHg), no exfoliative material on the anterior lens capsule or pupillary margin, normal visual fields and optic discs.

Venous blood samples were obtained from each participant into an evacuated tube containing heparin and placed on ice. After a maximum of two hours of collection, samples were centrifugated at 3500 rpm for six minutes and plasma supernatants had been stored into plastic Eppendorf tubes at -20°C up to seven days before plasma Hcy level analyses were performed. Hcy was measured using high-performance liquid chromatography (HPLC) with flourescent detection. A plasma Hcy level between 5 and 14 µmol/l was considered normal according to the manufacturer.

Plasma Hcy level, age and sex distrubition was compared among groups using Kruskal-Wallis test and Chi-Square test. The significance of difference for plasma Hcy levels among four groups was evaluated using Mann-Whitney U test. Afterall, the study population was divided into two subgroups with regard to the presence of pseudoexfoliation, and student t test was used to perform analysis between subgroup differences. A p-value less than 0.05 was considered statistically significant. Statistical analyses were performed using software SPSS version 15.0 (SPSS Inc., Chicago, Illinois, USA).

RESULTS

A total of 80 subjects were participated in this study, including 20 with PEX syndrome, 20 with PEX glaucoma, 20 with POAG and 20 controls. The mean age was 69.11±8.53 years (47-84); 43 of them were females (53.75%) and 37 of them were males (46.25%). There were no significant difference in gender distribution and age among the four study groups (p=0.815 and p=0.776, respectively). Demographic characteristics of the study patients are shown in table 1.

The mean plasma Hcy levels were 19.02±10.66 (median=16.95) µmol/l, 19.13±17.76 (median=14.85) µmol/l, 10.58±3.50 (median=10.00) µmol/l and 9.92±2.59 (median=9.50) µmol/l in patients with PEX syndrome, PEX glaucoma, POAG and control subjects, respectively. Figure 1 demonstrates the significant difference in plasma Hcy levels between the four groups (p=0.000). Mann-Whitney U test indicated that the mean plasma Hcy level was significantly higher in patients with PEX syndrome when compared to POAG patients and control subjects (p=0.001 and p=0.000, respectively). The mean plasma Hcy level was also significantly higher in PEX glaucoma group when compared to POAG and control groups (p=0.025 and p=0.004, respectively). There was no statistical difference between the mean plasma Hcy levels in POAG group and the controls (p=0.365). Mean plasma Hcy levels in patients with PEX syndrome did not show any statistically significant difference from those in PEX glaucoma either (p=0.402).

	PEXS (n=20)	PEXG (n=20)	POAG (n=20)	Controls (n=20)	p values
Age (years)	69.8±8.1	69.8±8.7	67.3±9.3	69.6±8.4	0.776
Gender					0.815
Female (%)	11 (55%)	9 (45%)	11 (55%)	12 (60%)	
Male (%)	9 (45%)	11 (55%)	9 (45%)	8 (40%)	
Mean plasma Hcy levels	19.02±10.66 µmol/l (median=16.95)	19.13±17.76 µmol/l (median=14.85)	10.58±3.50 µmol/l (median=10.00)	9.92±2.59 µmol/l (median=9.50)	0.000

PEXS: Pseudoexfoliation syndrome, PEXG: Pseudoexfoliation glaucoma, POAG: Primary open angle glaucoma, Hcy: Homocysteine.

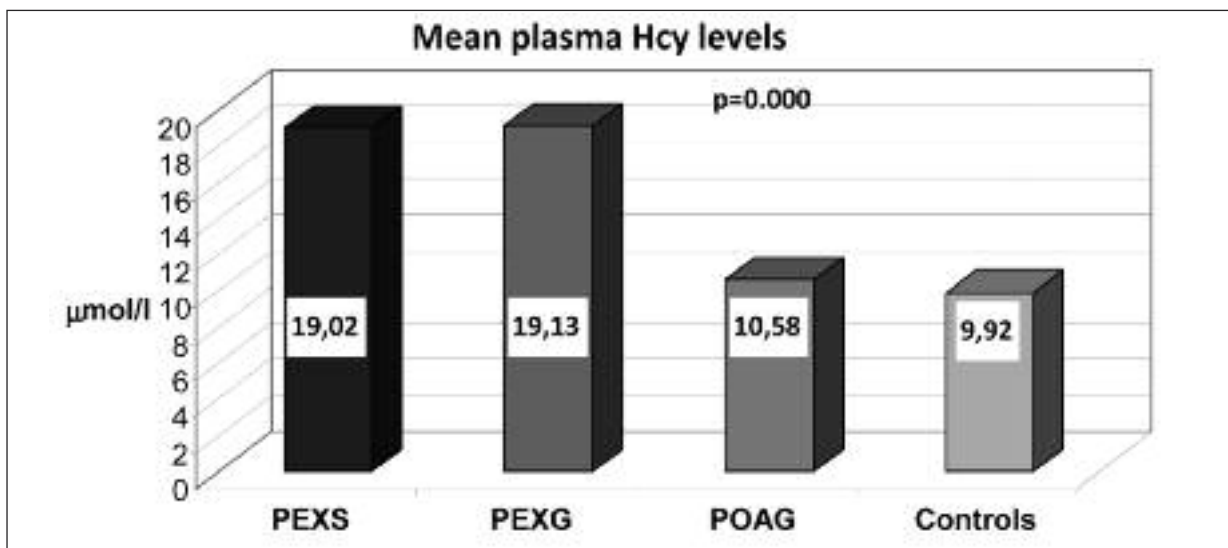


FIGURE 1: Mean plasma homocysteine levels of study subgroups (PEXS: Pseudoexfoliation syndrome, PEXG: Pseudoexfoliation glaucoma, POAG: Primary open angle glaucoma, Hcy: Homocysteine).

Table 2 demonstrates the differences of plasma Hcy levels among the study groups.

The mean plasma Hcy level in patients with PEX was 19.08±14.44 (median=15.95) µmol/l and 10.25±3.06 (median=9.60) µmol/l in the ones without PEX. When the study population was divided into two subgroups with regard to the presence of pseudoexfoliation, student t test indicated the mean plasma Hcy level was significantly elevated in patients with PEX ($p=0.000$), as shown in figure 2.

DISCUSSION

Pseudoexfoliation is an age-related condition caused by the production and accumulation of fibrillar material in the anterior segment of the eye,

the connective tissue portions of visceral organs and the skin. Extracellular fibrillar deposits were demonstrated by electron microscopy in autopsy specimens of liver, lung, heart, kidney, gall bladder, cerebral meninges and skin in patients with ocular PEX.^{24,25}

Hyperhomocysteinemia is a well known risk factor of systemic and ocular vascular disorders. Although its pathogenic mechanism and clinical importance remains poorly understood, current evidence suggests that elevated plasma Hcy levels may induce endothelial injury, smooth muscle proliferation, platelet activation and thrombogenesis.^{15,26-29} Hcy triggers overproduction of oxidative radicals that cause intimal damage and activate

	PEXS	PEXG	POAG	Controls
PEXS		0.402	0.001	0.000
PEXG			0.025	0.004
POAG				0.365
Controls				

PEXS: Pseudoexfoliation syndrome, PEXG: Pseudoexfoliation glaucoma, POAG: Primary open angle glaucoma.

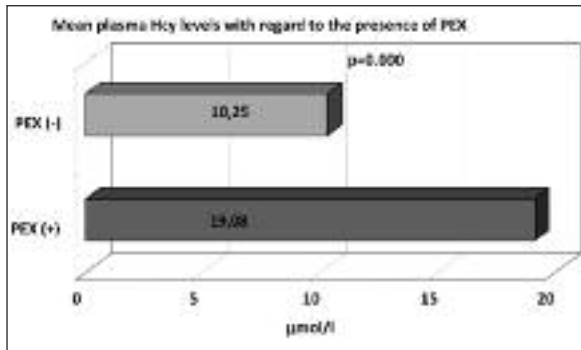


FIGURE 2: Mean plasma homocysteine levels with regard to the presence of pseudoexfoliation (PEX: Pseudoexfoliation / Hcy: Homocysteine).

serin elastase in arterial smooth muscle cells. Activation of matrix metalloproteinases and dysregulation of their inhibitors cause electrolysis of elastin and fibrillar collagen in arterial media. Chronic elevation of plasma Hcy impairs endothelium dependent vasodilatation via the inhibition of nitric oxide (NO) synthesis by asymmetric dimethyl-arginine (ADMA). Oxidative stress may explain the effect of Hcy in both systemic and ocular vascular disease. Sufficient dietary folic acid intake (0.5-5 mg/day) to scavenge oxygen radicals and improve endothelial function may reduce basal plasma Hcy levels by 25%.³⁰⁻³⁴

Chronic renal failure, systemic hypertension, diabetes mellitus, recent myocardial infarction, hypothyroidism, folic acid, cobalamin and vitamin B₆ deficiency, aging, gender, smoking, alcoholism, current medications as well as genetic disorders, especially point mutations in the methylene tetrahydrofolate reductase (MTHFR) gene may influence plasma Hcy levels.^{7,20,23,35-38} Elevated plasma Hcy level is suggested as an independent

risk factor for vascular disorders such as cardiovascular disease, stroke, vascular dementia, venous thrombosis and aortic aneurysms as well as ocular vascular disease including central retinal vein occlusion, central retinal artery occlusion, nonarteritic ischemic optic neuropathy and glaucomatous optic neuropathy.^{1-3,6-14,18-20,32-34}

Although mildly elevated plasma Hcy levels were measured in patients with POAG when compared to the controls, no statistically significant differences were revealed between these two groups in our study. In patients with POAG, Roedl et al.¹⁴ found elevated Hcy levels in both aqueous humor and plasma. Clement et al.²⁰ similarly found elevated plasma Hcy levels in patients with PEX glaucoma, POAG or normotensive glaucoma, and demonstrated the association of elevated plasma Hcy levels with glaucoma.

The results of our study demonstrated statistically significant higher plasma Hcy levels in patients with pseudoexfoliation when compared to the cases without PEX. Similar to our findings, elevated Hcy levels in patients with PEX were reported by Leibovitch et al.¹⁹ who suggested that the exfoliation material might be a product of Hcy-induced elastolysis of elastin and fibrillar collagen. The relationship between hyperhomocysteinemia and PEX was also found by Vessani et al.²¹ Cumurcu et al.³⁹ reported significantly higher plasma Hcy concentrations and lower serum folic acid levels in PEX glaucoma patients, however plasma B₁₂ concentrations did not alter. Bleich et al.¹⁸ and Pustjarvi et al.²² indicated elevated plasma and aqueous humour levels of Hcy in exfoliation syndrome. Although Turacı et al. reported no association between plasma Hcy levels and PEX in Turkish population, Sarıcaoglu et al. and Turgut et al. found a significant correlation between them.⁴⁰⁻⁴²

CONCLUSION

Hyperhomocysteinemia was found to be associated with pseudoexfoliation syndrome with or without glaucoma. We suggest routine measurement of plasma Hcy levels in patients with PEX for predicting the risk of vascular disease, although it is not clear whether Hcy is a causative factor or only

a marker for such vascular disorders. Several studies have shown that folic acid supplements, as well as vitamin B₆ and B₁₂ could reduce plasma Hcy lev-

els by 25%. Similar prospective trials will be needed to assess the correlation between hyperhomocysteinemia and pseudoexfoliation.

REFERENCES

- Ritch R, Schlötzer-Schrehardt U. Exfoliation syndrome. *Surv Ophthalmol* 2001;45(4):265-315.
- Lahners WJ, Samuelson TW. Pseudoexfoliative glaucoma. In: Yanoff M, Duker JS, eds. *Ophthalmology*. 2nd ed. St Louis: CV Mosby; 2004. p.1499-503.
- Palmberg PE, Wiggs JL. Mechanism of glaucoma. In: Yanoff M, Duker JS, eds. *Ophthalmology*. 2nd ed. St Louis: CV Mosby; 2004. p.1423-30.
- McCully KS. Homocysteine and vascular disease. *Nat Med* 1996;2(4):386-9.
- Finkelstein JD. The metabolism of homocysteine: pathways and regulation. *Eur J Pediatr* 1998;157(Suppl 2):S40-4.
- Sottolotta G, Oriana V, Latella C, Luise F, Piro-malli A, Ramirez F, et al. Role of hyperhomocysteinemia in retinal vascular occlusive disease. *Clin Appl Thromb Hemost* 2007;13(1):104-7.
- Boyd S, Owens D, Gin T, Bunce K, Sherafat H, Perry D, et al. Plasma homocysteine, methylene tetrahydrofolate reductase C677T and factor II G20210A polymorphism, factor VIII and VWF in central retinal vein occlusion. *Br J Ophthalmol* 2001;85(11):1313-5.
- Kuo JZ, Lai CC, Ong FS, Shih CP, Yeung L, Chen TL, et al. Central retinal vein occlusion in a young Chinese population: risk factors and associated morbidity and mortality. *Retina* 2010;30(3):479-84.
- Sodi A, Giambene B, Marcucci R, Sofi F, Bolli P, Abbate R, et al. Atherosclerotic and thrombophilic risk factors in patients with recurrent central retinal vein occlusion. *Eur J Ophthalmol* 2008;18(2):233-8.
- Cahill MT, Stinnett SS, Fekrat S. Meta-analysis of plasma homocysteine, serum folate, serum vitamin B(12), and thermolabile MTHFR genotype as risk factors for retinal vascular occlusive disease. *Am J Ophthalmol* 2003;136(6):1136-50.
- Stanger O, Weger M, Obeid R, Temmel W, Meinitzer A, Steinbrugger I, et al. Impairment of homocysteine metabolism in patients with retinal vascular occlusion and non-arteritic ischemic optic neuropathy. *Clin Chem Lab Med* 2005;43(10):1020-5.
- Pianka P, Almong Y, Man O, Goldstein M, Sela B, Loewenstein A. Hyperhomocysteinemia in patients with nonarteritic anterior ischemic optic neuropathy, central retinal artery occlusion, and central retinal vein occlusion. *Ophthalmology* 2000;107(8):1588-92.
- Muñoz-Negrete FJ, Casas-Lleras P, Pérez-López M, Rebolledo G. [Hypercoagulable workup in ophthalmology. When and what]. *Arch Soc Esp Oftalmol* 2009;84(7):325-32.
- Roedl JB, Bleich S, Reulbach U, von Ahsen N, Schlötzer-Schrehardt U, Rejdak R, et al. Homocysteine levels in aqueous humor and plasma of patients with primary open-angle glaucoma. *J Neural Transm* 2007;114(4):445-50.
- Mujumdar VS, Aru GM, Tyagi SC. Induction of oxidative stress by homocyst(e)ine impairs endothelial function. *J Cell Biochem* 2001;82(3):491-500.
- Schlötzer-Schrehardt U, Lommatzsch J, Küchle M, Konstas AG, Naumann GO. Matrix metalloproteinases and their inhibitors in aqueous humor of patients with pseudoexfoliation syndrome/glaucoma and primary open-angle glaucoma. *Invest Ophthalmol Vis Sci* 2003;44(3):1117-25.
- Shastri S, Tyagi N, Moshal KS, Lominadze D, Hayden MR, Tyagi SC. GABA receptors ameliorate Hcy-mediated integrin shedding and constrictive collagen remodeling in microvascular endothelial cells. *Cell Biochem Biophys* 2006;45(2):157-65.
- Bleich S, Roedl J, von Ahsen N, Schlötzer-Schrehardt U, Reulbach U, Beck G, et al. Elevated homocysteine levels in aqueous humor of patients with pseudoexfoliation glaucoma. *Am J Ophthalmol* 2004;138(1):162-4.
- Leibovitch I, Kurtz S, Shemesh G, Goldstein M, Sela BA, Lazar M, et al. Hyperhomocysteinemia in pseudoexfoliation glaucoma. *J Glaucoma* 2003;12(1):36-9.
- Clement CI, Goldberg I, Healey PR, Graham SL. Plasma homocysteine, MTHFR gene mutation, and open-angle glaucoma. *J Glaucoma* 2009;18(1):73-8.
- Vessani RM, Ritch R, Liebmann JM, Jofe M. Plasma homocysteine is elevated in patients with exfoliation syndrome. *Am J Ophthalmol* 2003;136(1):41-6.
- Puustjarvi T, Blomster H, Kontkanen M, Punnonen K, Terasvirta M. Plasma and aqueous humour levels of homocysteine in exfoliation syndrome. *Graefes Arch Clin Exp Ophthalmol* 2004;42(9):749-54.
- Rady PL, Szucs S, Grady J, Hudnall SD, Kellner LH, Nitowsky H, et al. Genetic polymorphisms of methylenetetrahydrofolate reductase (MTHFR) and methionine synthase reductase (MTRR) in ethnic populations in Texas; a report of a novel MTHFR polymorphic site, G1793A. *Am J Med Genet* 2002;107(2):162-8.
- Schlötzer-Schrehardt U, Koca MR, Naumann GO, Volkholz H. Pseudoexfoliation syndrome: ocular manifestations of a systemic disorder? *Arch Ophthalmol* 1992;110(12):1752-6.
- Streeten BW, Li ZY, Wallace RN. Pseudoexfoliative fibrilopathy in visceral organs of a patient with pseudoexfoliation syndrome. *Arch Ophthalmol* 1992;110(12):1757-62.
- Jiang C, Zhang H, Zhang W, Kong W, Zhu Y, Zhang H, et al. Homocysteine promotes vascular smooth muscle cell migration by induction of the adipokine resistin. *Am J Physiol Cell Physiol* 2009;297(6):1466-76.
- Hedayati N, Annambhotla S, Jiang J, Wang X, Chai H, Lin PH, et al. Growth hormone-releasing peptide ghrelin inhibits homocysteine-induced endothelial dysfunction in porcine coronary arteries and human endothelial cells. *J Vasc Surg* 2009;49(1):199-207.
- Undas A, Brozek J, Szczeklik A. Homocysteine and thrombosis: from basic science to clinical evidence. *Thromb Haemost* 2005;94(5):907-15.
- Köz C, Türkcü F, Gürbüz Köz Ö, Yokuşoğlu M, Baysan O, Yarangümel A, et al. [Endothelial function and novel vascular risk factors in pseudoexfoliation syndrome]. *Turkiye Klinikleri J Med Sci* 2009;29(6):1510-6.
- Rodionov RN, Dayoub H, Lynch CM, Wilson KM, Stevens JW, Murry DJ, et al. Overexpression of dimethylarginine dimethylaminohydrolase protects against cerebral vascular effects of hyperhomocysteinemia. *Circ Res* 2010;106(3):551-8.
- Sela BA. [ADMA (asymmetric dimethylarginine)--the inhibitor of nitric oxide (NO) synthesis: a new marker for vascular pathology]. *Harefuah* 2005;144(9):655-9, 675, 674.
- Tarkkanen A. Is exfoliation syndrome a sign of systemic vascular disease? *Acta Ophthalmol* 2008;86(8):832-6.

33. Arapoglou V, Kondi-Pafiti A, Rizos D, Kotsis T, Kalkandis C, Katsenis K. The influence of total plasma homocysteine and traditional atherosclerotic risk factors on degree of abdominal aortic aneurysm tissue inflammation. *Vasc Endovascular Surg* 2009;43(5):473-9.
34. Werder SF. Cobalamin deficiency, hyperhomocysteinemia, and dementia. *Neuropsychiatr Dis Treat* 2010;6:159-95.
35. Dominguez LJ, Galioto A, Pineo A, Ferlisi A, Ciaccio M, Putignano E, et al. Age, homocysteine, and oxidative stress: relation to hypertension and type 2 diabetes mellitus. *J Am Coll Nutr* 2010;29(1):1-6.
36. Turhan S, Sezer S, Erden G, Guctekin A, Ucar F, Ginis Z, et al. Plasma homocysteine concentrations and serum lipid profile as atherosclerotic risk factors in subclinical hypothyroidism. *Ann Saudi Med* 2008;28(2):96-101.
37. Sagheb MM, Ostovan MA, Sohrabi Z, Atabati E, Raisjalai GA, Roozbeh J. Hyperhomocysteinemia and cardiovascular risk in hemodialysis patients. *Saudi J Kidney Dis Transpl* 2010;21(5):863-6.
38. Ganji V, Kafai MR; Third National Health and Nutrition Examination Survey. Demographic, health, lifestyle, and blood vitamin determinants of serum total homocysteine concentrations in the third National Health and Nutrition Examination Survey, 1988-1994. *Am J Clin Nutr* 2003;77(4):826-33.
39. Cumurcu T, Sahin S, Aydin E. Serum homocysteine, vitamin B12 and folic acid levels in different types of glaucoma. *BMC Ophthalmol* 2006;6:6.
40. Turacli ME, Tekeli O, Ozdemir F, Akar N. Methylene tetrahydrofolate reductase 677 C-T and homocysteine levels in Turkish patients with pseudoexfoliation. *Clin Exp Ophthalmol* 2005;33(5):505-8.
41. Saricaoglu MS, Karakurt A, Sengun A, Hasi-ripi H. Plasma homocysteine levels and vitamin B status in patients with pseudoexfoliation syndrome. *Saudi Med J* 2006;27(6):833-7.
42. Turgut B, Kaya M, Arslan S, Demir T, Güler M, Kaya MK. Levels of circulating homocysteine, vitamin B6, vitamin B12, and folate in different types of open-angle glaucoma. *Clin Interv Aging* 2010;5:133-9.