

Ruptured Abdominal Aortic Aneurysm After Endovascular Repair of Abdominal Aortic Aneurysm: Original Image

Endovasküler Onarım Sonrası Rüptüre Abdominal Aort Anevrizması

Ufuk AYDIN,^a
Alper GÖRÜR,^a
Orhan FINDIK,^a
Cevdet Uğur KOCAOĞULLARI^a

^aDepartment of Cardiovascular Surgery,
Kocaeli Derince Training and
Research Hospital, Kocaeli

Geliş Tarihi/Received: 28.02.2012
Kabul Tarihi/Accepted: 17.05.2012

Yazışma Adresi/Correspondence:

Ufuk AYDIN
Kocaeli Derince Training and
Research Hospital,
Department of Cardiovascular Surgery,
Kocaeli,
TÜRKİYE/TURKEY
nesruf@isnet.net.tr

Key Words: Aortic
aneurysm, abdominal;
aneurysm, ruptured

Anahtar Kelimeler: Aort
anevrizması, abdominal;
anevrizma, rüptüre

**Türkiye Klinikleri J
Cardiovasc Sci 2012;24(2):187-9**

Copyright © 2012 by Türkiye Klinikleri

Abdominal aortic aneurysms may become life-threatening conditions if they remain untreated. Conventional open surgical repair with placement of an interposition graft is regarded as a definitive form of treatment, but is associated with considerable operative morbidity and mortality especially in high-risk patients.¹ In treating uncomplicated abdominal aortic aneurysm, endovascular aortic aneurysm repair (EVAR) has been employed as a good alternative to open repair with low perioperative morbidity and mortality. However, the aneurysm can enlarge or rupture even after EVAR as a result of device failure, endoleak, or graft migration.^{2,3}

A 63-year-old patient was admitted to our department 13 months after endovascular repair of an 75-milimeter infrarenal abdominal aortic aneurysm. There was neither endoleak nor aneurysm enlargement reported in the tomography which was done 6 months before. At admission he presented with severe abdominal pain and distension. On arrival at the emergency room, his blood pressure was 80/50 mmHg. He had histories of Diabetes mellitus and coronary artery disease. Computed tomography confirmed aneurysm rupture with a large hematoma in the extraperitoneal space, which was confirmed intra-operatively (Figure 1,2). He presented with severe abdominal pain and hypovolemic shock in the tomography room. The patient was transferred to the operating theatre. He was operated under emergency conditions. Through median laparotomy the abdominal aorta was dissected. Abdominal aorta was clamped below renal arteries, aneurysmal sac was opened and endovascular stent-grafts were removed (Figure 3,4). Peroperative evaluation of stent graft fixation proved migration of proximal extension implanted during the primary intervention due to endoleak. Aorta-biiliac bypass was performed using 18- 8mm polytetrafluoroethylene graft (Gore-Tex, USA) and retroperitoneal hematoma removed. He was transferred to the intensive care unit in a critical condition. During the postoperative course, he developed acute renal failure and continuous renal replacement therapy was performed. He stayed at the

intensive care unit for 12 days. The patient died from sepsis and multiorgan failure on the 25th postoperative day. In our opinion the cause of aneurysm rupture was reappearance of the endoleak type I due to distal dislocation of proximal stent-graft extension.

The aneurysm can enlarge or rupture even after EVAR as a result of device failure, endoleak, or graft migration. Incomplete initial graft expansion, inadequate proximal or distal seal zone, further arterial dilation, endograft migration, component separation, and tears within the graft fabric are all possible causes of endoleaks. From the introduction of EVAR there is a need of care-

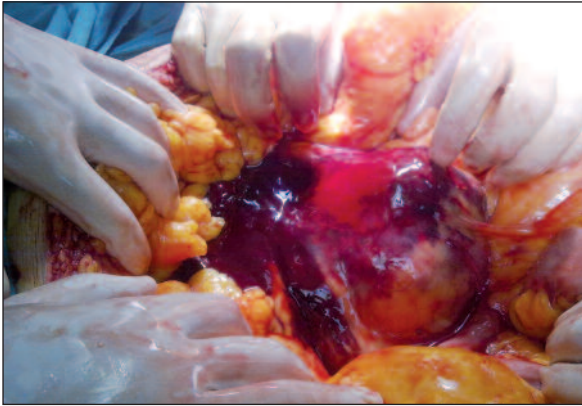

FIGURE 1: Intraoperative finding of a ruptured infrarenal abdominal aortic aneurysm.

(See for colored form <http://cardiovascular.turkiyeklinikleri.com/>)

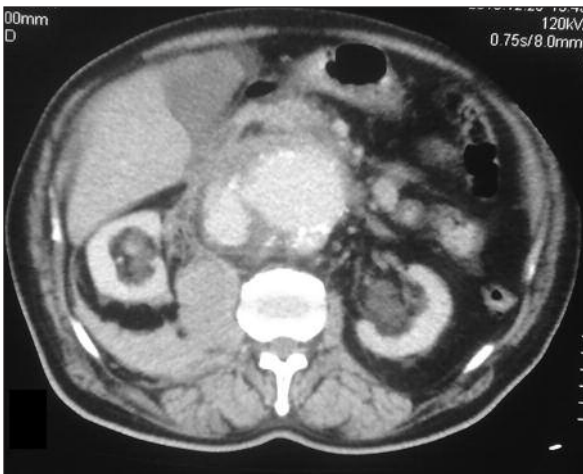


FIGURE 2: Abdominal CT showing the abdominal aortic aneurysm and retroperitoneal hematoma.

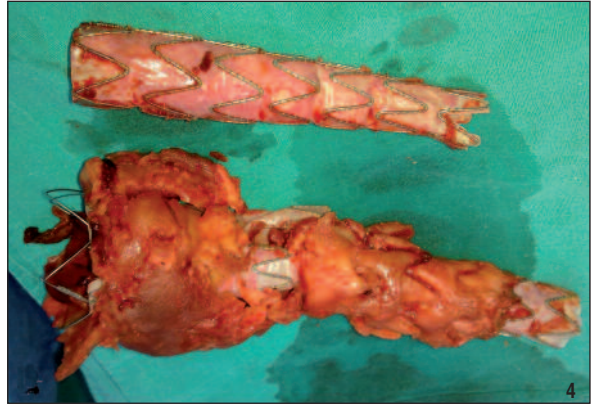
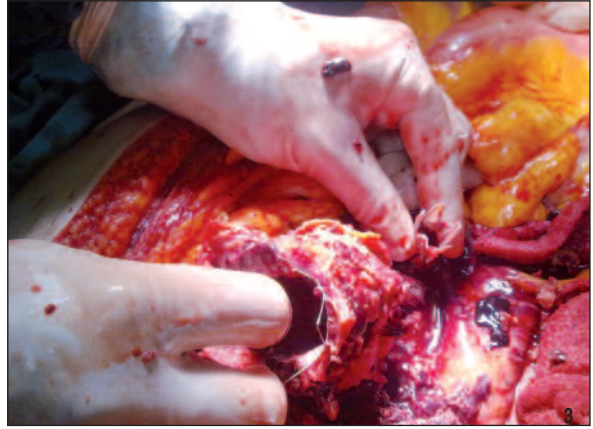

FIGURE 3, 4: Endovascular stent-graft was explanted during the operation.

(See for colored form <http://cardiovascular.turkiyeklinikleri.com/>)

ful postoperative surveillance for endoleak detection.²⁻⁴ Tube endografts should be limited to the rare patient with ideal anatomy, no other alternatives, and at high risk for standard open repair.³ In the last decade the EVAR became the best option for patients with high risk of open aneurysm repair. Introduction of this method significantly reduced mortality and morbidity caused by abdominal aortic aneurysm. Although the results of such aneurysm management modality are good, this method of treatment is not free from various complications.⁴ Although the risk of aneurysm rupture after EVAR is low, all patients treated endovascularly should be routinely monitored, even in late postoperative period, in order to diagnose the potential endoleaks or stent-graft migration which may lead to fatal complications. When rupture occurs open aneurysm repair is feasible, although it requires careful management in these high-risk patients.⁴

REFERENCES

1. Yaşa H, Bayrak S, Ali Gürbüz A. [Combined Surgical and Endovascular Repair for Abdominal Aortic Aneurysms]. *Türkiye Klinikleri J Cardiovasc Surg-Special Topics* 2011;3(1):52-60.
2. Lee CW, Chung SW, Kim JW, Kim S, Bae MJ, Kim CW. Ruptured abdominal aortic aneurysm after endovascular aortic aneurysm repair. *Korean J Thorac Cardiovasc Surg* 2011;44(1):68-71.
3. Karabay Ö. [Endovascular treatment of abdominal aortic pathologies]. *Türkiye Klinikleri J Cardiovasc Surg-Special Topics* 2009;2(1):46-54.
4. Szmidski J, Galazka Z, Rowinski O, Nazarewski S, Jakimowicz T, Pietrasik K, et al. Late aneurysm rupture after endovascular abdominal aneurysm repair. *Interact Cardiovasc Thorac Surg* 2007;6(4):490-4.