

Hypothenar Hammer Syndrome Leading to Carpal Tunnel Syndrome in the Same Hand in a Pediatric Patient: A Rare Case

Pediatric Bir Hastada Aynı Elde Karpal Tünel Sendromuna Yol Açan Hipotenar Çekiç Sendromu: Nadir Bir Olgu

Süleyman ÇEÇEN,^a
Burak ERSEN,^a
Selçuk AKIN,^a
Orhan TUNALI,^a
İsmail AKSU^a

^aDepartment of Plastic Aesthetic and
Reconstructive Surgery,
Uludağ University Faculty of Medicine,
Bursa

Geliş Tarihi/Received: 14.03.2015
Kabul Tarihi/Accepted: 15.05.2015

Yazışma Adresi/Correspondence:
Burak ERSEN
Uludağ University Faculty of Medicine,
Department of Plastic Aesthetic and
Reconstructive Surgery, Bursa,
TÜRKİYE/TURKEY
drburakersen@gmail.com

ABSTRACT Either a single blunt injury or repetitive trauma which associated with the work may lead to aneurysmatic dilatations of ulnar arterial wall in the Guyon space and cause Hypothenar hammer syndrome. A 17 years old male patient was referred to our clinic with 4 months of throbbing pain over right hand palm, pulsatile tender swelling in the right hypothenar eminence. He gave a single blunt injury history that happened with an explosion of mobile phone battery about 6 months ago. He has recognized increased sensitivity to cold at his right hand. The sensitivity was aberrant in cold days and was increasing in cold water. He was complaining about a slight numbness in his first, second and third fingers with thenar atrophy. Doppler ultrasonography and magnetic resonance imaging revealed presence of a 12x10x16 mm size pseudoaneurysm which was connected to the ulnar artery. The aneurysm was removed surgically and reconstruction was performed with a vein graft.

Key Words: Carpal Tunnel syndrome; ulnar artery; aneurysm

ÖZET İşle alakalı tek künt yaralanma ya da tekrarlayan travma Guyon boşluğunda ulnar arter çeperinde anevrizmatik dilatasyonlara yol açabilmektedir. On yedi yaşındaki erkek olgu, dört ay önceden başlayan sağ el avuç içinde zonklayıcı ağrı, sağ hipotenar kenarındaki pulsatil ve hassas şişlik nedeni ile kliniğimize başvurdu. Altı ay önce cep telefonu bataryasının patlaması sonucu oluşan tek künt yaralanma öyküsü mevcuttu. Sağ elinde özellikle soğuk günlerde ve soğuk suda belirginleşen soğuğa karşı aşırı hassasiyet tariflemekteydi. Birinci, ikinci ve üçüncü parmaklarında biraz hissizlik ve tenar atrofi mevcuttu. Doppler ultrason ve manyetik rezonans incelemelerde, ulnar arterde 12x10x16 mm'lik psödoanevrizma gözlemlendi. Anevrizma cerrahi olarak çıkarıldı ve ven grefti ile onarıldı.

Anahtar Kelimeler: Karpal Tünel sendromu; ulnar arter; anevrizma

Türkiye Klinikleri J Case Rep 2016;24(1):62-5

Hypothenar hammer syndrome (HHS) is an uncommon form of the secondary Reynaud phenomenon, occurring mainly in subjects who use the hypothenar part of the hand as a hammer. The hook of hamate strikes to superficial palmar branch of the ulnar artery in the Guyon space, leading to occlusion and/or aneurysm of the ulnar artery.¹ Either a single blunt injury or repetitive trauma which associated with the job may lead to aneurysmatic dilatations of arterial wall.² HHS was first described by von Rosen in 1934 and a term coined by Conn.^{3,4} Because of the anatomic configuration of the Guyon canal, the ulnar artery is particularly vulnerable to mechanical injury due to its entrapment between a

doi: 10.5336/caserep.2015-44981

Copyright © 2016 by Türkiye Klinikleri

hammer (external force) and an anvil (the hamate bone); in patients with HHS, the hook of the hamate bone indeed strikes the superficial palmar branch of the ulnar artery in the Guyon space, leading to the development of; an aneurysmal dilatation of ulnar artery with secondary downstream embolization and a local segmental occlusion of the ulnar artery.¹

In our case; we consider carpal tunnel syndrome secondary to an hypotenar hammer syndrome is a rare entity.

CASE REPORT

A 17 years old male patient was referred to our clinic with throbbing pain over right hand for 4 months that may caused by blunt injury to the right hand by an explosion of his mobile phone battery. He did not suffer from any systemic disease in his medical history and he was a high school student.

He suffered cold intolerance in right hand, a pulsatile mass in hypothenar eminence. He also has slight numbness in his first, second and third fingers of the right hand. He did not mention about digital ulcers, cyanosis, gangrene.

On physical examination; radial and ulnar pulses were palpable. The right hypotenar eminence was tender and a small expansile mass measuring about 1,8 cm in diameter was palpable. Allen test was normal at left hand, but at the right hand; there was a slightly late refill of palmar vasculature on the release of the ulnar artery. There was thenar atrophy on right hand for 4 months that he was aware of.

Doppler ultrasonography confirmed presence of an aneurysm that connected to the ulnar artery, it had a small lumen in it, and a thrombosis formation was visible peripherally in the lumen. Magnetic resonance imaging (MRI) scan demonstrated that pseudoaneurysm was at the radial side of ulnar artery with the size of 12x10 mm at the transverse plane and 16 mm at the vertical plane. An electroneuromyography (ENMG) test was also performed and the test results were compatible with moderate level carpal tunnel syndrome.

The patient had thenar atrophy for 4 months, in his medical history there wasn't anything that may explain this condition apart from a pulsatile mass in hypothenar eminence. Hypothenar atrophy was not existed neither any other symptoms related to ulnar nerve damage such as hypoesthesia in 4th and 5th fingers, lack of adduction of thumb, or atrophy of interosseoos muscles. It was suspected that the thenar atrophy may have happened due to progressively growing pseudoaneurysm that created increasing pressure to recurrent branch of the median nerve, so called million dollar nerve, in thenar eminence. Patient's ENMG demonstrated that the right hand's median nerve distal motor fibers were affected and leded to median nerve distal motor neuropathy with low motor amplitude. An angiography was performed pre-operatively. Interestingly patient's radial artery was smaller in diameter. It was considered that the radial artery was the non-dominant artery of the hand. Therefore aneurysm resection and reconstruction of the ulnar artery with a vein graft were performed in order to prevent vascular compromise.

A lazy S incision was planned at the hypothenar eminence in order to explore and demonstrate the bifurcation at the distal end of the pseudoaneurysm and the branches of superficial and the deep palmar arch (Figure 1). The pseudoaneurysm was removed surgically (Figure 2) and reconstruction with a saphenous vein graft was

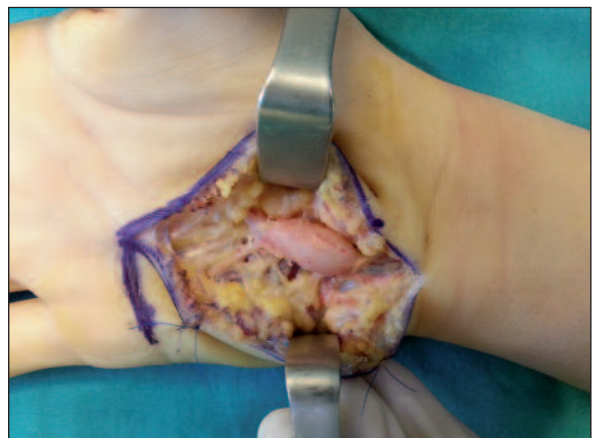


FIGURE 1: Aneurysm explored and demonstrated with a lazy s incision.

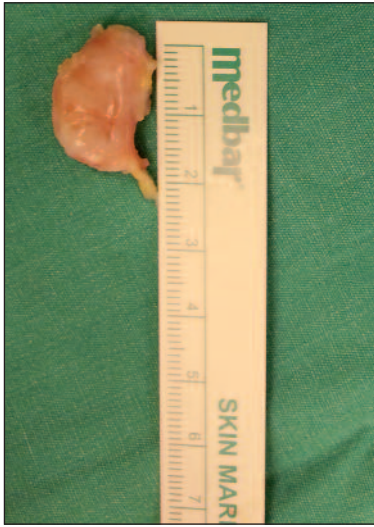

FIGURE 2: The resection of aneurysm was performed.

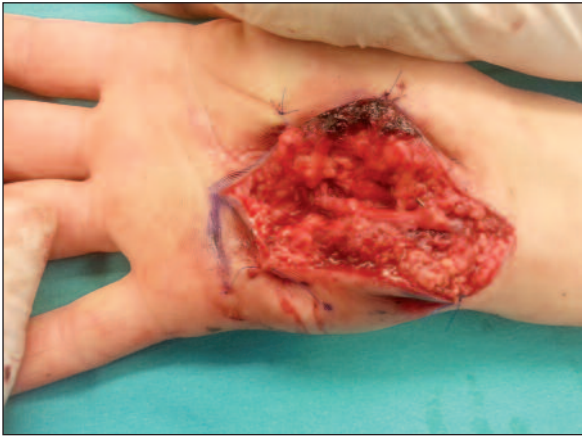


FIGURE 3: Ulnar artery was reconstructed with a vein graft.

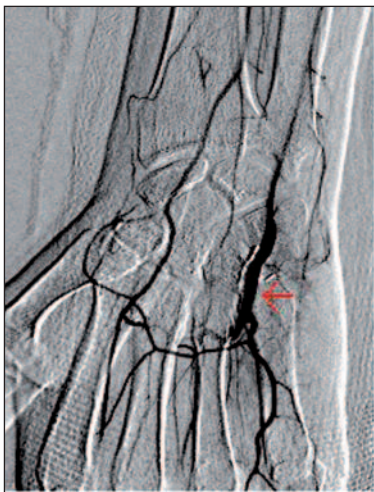

FIGURE 4: 6 week post operatively. Undisturbed arterial in-flow was seen. Red arrow points vein graft.

performed (Figure 3). Pathologic specimen was 2,1x1x1,5 cm in size and an organized thrombus in the pseudoaneurysm was diagnosed during histopathological examination. Six weeks after the reconstruction of the ulnar artery, an upper extremity arteriography was scanned in order to investigate arterial flow. Angiography proved there was no occlusion or thrombosis formation in graft anastomosis sites, and graft maintains blood through anastomosis to superficial and deep palmar arches (Figure 4).

In the post operative physical examination; the patient described the numbness of the first, second and third finger was refined completely. A control ENMG was performed in the 6th month after surgery. The ENMG demonstrated that the previous low motor amplitude of the median nerve fibers was significantly refined.

The written consent was given by the patient himself for the use of his images.

DISCUSSION

HHS describes signs and symptoms associated with aneurysm and decreased blood flow in ulnar artery that secondary to repetitive or single blunt trauma to the hypothenar eminence hammering the ulnar artery and superficial arch against the hook of the hamate. The hypothenar hammer syndrome most likely caused by repetitive occupational trauma or sport injuries. Most frequently, male laborers in their fifth decade of life are affected by ulnar artery thrombosis.⁵ Aneurysmatic dilatation of ulnar artery is rare in literature and true aneurysm is more rare, but especially there are case reports in pediatric population.⁶ The patient attended to our clinic was in pediatric age group and he was not a labor. The injury was an accidental mobile phone battery explosion, which was a rare entity.

Symptoms of hypothenar hammer syndrome are varied, but can be classified under two categories. First; symptoms that related to vascular insufficiency, especially like Reynaud phenomenon, digital necrosis and ischemia. Second; symptoms that were caused by aneurysm- pulsatile mass in

hypothenar area, possible pressure on the ulnar nerve.² In our case, due to the large size of the aneurysm, the mass was creating pressure on median nerve. Resection of the aneurysm reduced median nerve neuropathy symptoms.

Treatment options range from conservative measure to surgical intervention. Conservative measures include smoking cessation, calcium channel blockers, stellat ganglion blocks and maintenance of the hand in a warm environment. For patients with evidence of more advanced disease such as digital ulceration and chronic pain, surgical intervention may be considered. Surgical options can be divided into two basic groups: resection of involved arterial segment with ligation and vascular reconstruction with or without interposed graft.⁶ It is hard to claim there is an optimal treatment for hypothenar hammer syndrome. Isabelle et al. stated in their paper that there isn't any randomized and controlled studies evaluating non-surgical therapy in patients with HHS.¹ This is probably explained by the rarity of

HHS, which makes treatment comparisons almost impossible.

Preoperative assessment, especially in objective ways will help us to decide optimum surgical intervention for patients. We can use digital brachial index, pulse volume recording, laser doppler fluxmetry or even allen test for evaluation ulnar artery flow.

In our case; we chose to reconstruct the ulnar artery with a vein graft in order to prevent vascular compromise. Because, with the Allen test our patient impaired ulnar artery flow and arterography demonstrated that our patient's radial artery was non-dominant. Six months after surgery almost all symptoms were relieved, only thenar atrophy was the persisting feature.

A pediatric patient with hypothenar hammer syndrome leading to carpal tunnel syndrome due to the size of the aneurysm was a rare entity. Moreover the patient's initial radial artery was relatively small in caliber therefore a vein graft was used to reconstruct the ulnar artery.

REFERENCES

1. Marie I, Hervé F, Primard E, Cailleux N, Levesque H. Long term follow-up of hypothenar hammer syndrome, a series of 47 patient. *Medicine (Baltimore)* 2007;86(6):334-43.
2. Altinkaya S, Tunalı O, Ozgenel GY, Kahveci R. [Hypothenar hammer syndrome: case report]. *Turk Plast Surg* 2014;22(2)80-1.
3. von Rosen S. Ein Fall von Thrombose in der Arteria ulnaris Nach Ein wirkung von stumpfer Gewalt. *Acta Chir Scand* 1934;73: 500-6.
4. Conn JJr, Bergan JJ, Bell JL. Hypothenar hammer syndrome: posttraumatic digital ischemia. *Surgery* 1970;68(6):1122-8.
5. De Monaco D, Fritsche E, Rigoni G, Schlunke S, Von Wartburg U. Hypothenar hammer syndrome. *J Hand Surg Br* 1999;24(6):731-4.
6. Lifchez S, Higgins J. Long term results of surgical treatment for hypothenar hammer syndrome. *Plast Reconstr Surg* 2009;124(1): 210-6.