

Juvenile Xanthogranuloma: A Report of Three Cases

Juvenil Ksantogranülom: Üç Olgu Sunumu

İlkin ZİNDANCI, MD,^a
Mukaddes KAVALA, MD,^a
Burçe CAN, MD,^a
Emek KOCATÜRK, MD,^a
Ebru ZEMHERİ, MD,^b
Melek KOÇ, MD,^a
Zafer TÜRKÖĞLU, MD^a

Departments of ^aDermatology,
^bPathology Göztepe Educational
Hospital, İstanbul

Geliş Tarihi/Received: 28.11.2006
Kabul Tarihi/Accepted: 19.03.2007

Yazışma Adresi/Correspondence:
İlkin ZİNDANCI, MD
Goztepe Educational Hospital
Department of Dermatology,
İstanbul
TÜRKİYE/TURKEY
drilkinzindanci@yahoo.com

ABSTRACT Juvenile xanthogranuloma (JXG) is a common form of non-Langerhans cell histiocytosis, most often effecting infants, young children and occasionally adults. JXG is characterized by solitary or multiple yellowish cutaneous nodules, the two common clinical variants being a small nodular form and large nodular form, which frequently coexist. Lesions are often localized to the head and neck and occur less often on the trunk and the extensor surface of the extremities. Systemic involvement may occur. Many of them may go undiagnosed or misdiagnosed as other common skin tumors. The diagnosis is made base on histopathological findings. We report 3 children who are presented with multiple separating solitary lesions and rewiev of the literature.

Key Words: Xanthogranuloma, juvenile; histiocytosis

ÖZET Juvenil ksantogranülom non-Langerhans hücreli histiositozların sık görülen bir formudur. Genellikle çocuk ve genç erişkinler, nadiren de adultlar etkilenir. Soliter, sarımsı kutanöz nodüllerle karakterizedir. Klinik varyantları küçük nodüler ve büyük nodüler formlar şeklindedir ve sıklıkla birlikte görülür. Lezyonlar daha çok baş ve boyunda, nadiren de gövde ve ekstremitelerin ekstansör yüzlerinde lokalize olur. Sistemik tutulum görülebilir. Diğer sık görülen deri tümörleri ile karışabildiğinden sıklıkla yanlış tanı konur veya tanı konamaz. Tanı histopatolojik bulgularla konur. Burada multipl soliter lezyonlarla seyreden 3 çocuk olguyu sunduk ve literatürü gözden geçirdik.

Anahtar Kelimeler: Juvenil ksantogranülom; histiositoz

Türkiye Klinikleri J Med Sci 2008, 28:576-579

Juvenile xanthogranuloma (JXG) is a common form of non-Langerhans cell histiocytosis, most often involving infants, young children and occasionally adults. It is generally a benign self-limited disease and characterized by accumulation of lipid-laden macrophages.^{1,2} Although the term “xantho”- appears in the name, JXG is not associated with disorders of lipid metabolism.

We report three children who presented with single and multiple separating solitary lesions.

CASE 1

A 1-year-old girl presented with a 2-month history of an asymptomatic papule on her forehead. On examination, there was a 10 x 15 mm orange-red, dome shaped papule located on top of the glabella (Figure 1). A skin biopsy revealed macrophages, foamy cells, scattered lymphocytes with

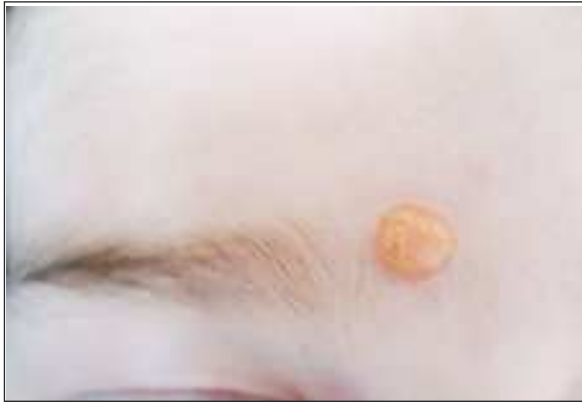

FIGURE 1: Orange-red, dome shaped papule located on the top of the glabella.

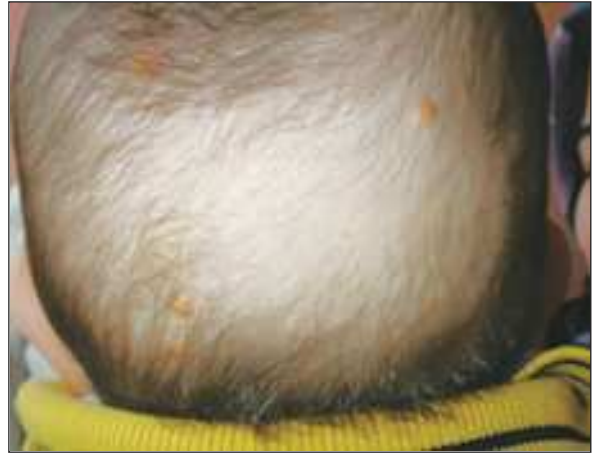

FIGURE 2: Yellow, dome-shaped nodular lesions on the scalp.

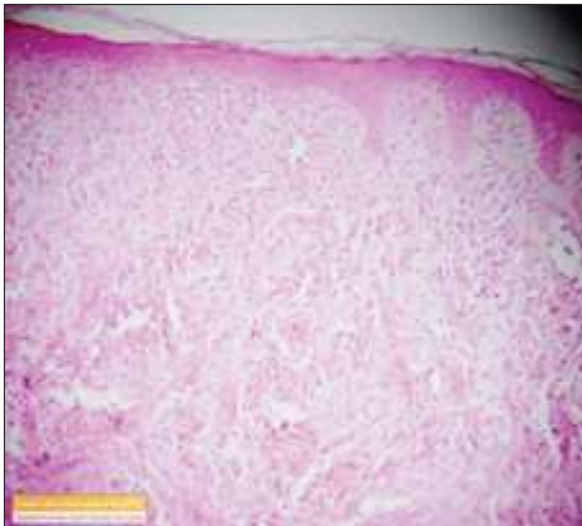


FIGURE 3: A lesion with cellular infiltrates rich from histiocytes filling the dermis, sparing the epidermis with grenz zone (HE x 100).

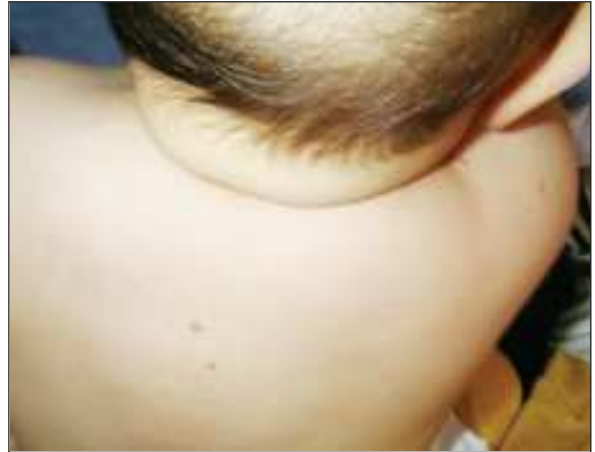

FIGURE 4: Shiny, yellowish papular lesions on the left side of upper back.

plasma cells and scattered eosinophils and prominent Touton giant cells. There was no systemic involvement.

CASE 2

A 7-month-old girl presented with a history of multiple swellings all over the body since 4 months old. There was no similar history in the family. General examination revealed multiple reddish yellow, dome-shaped nodular lesions varying in size from 2 to 20 mm (Figure 2). The lesions were distributed predominantly on the scalp and the extremities. Skin

biopsy showed widespread histiocytic infiltration of the dermis, which was consistent with JXG (Figure 3). There was no eye, lung, spleen, liver, and central nervous system involvement.

CASE 3

A 1-year-old boy presented with multiple swellings on the scalp and extremities. The lesions started on the scalp first when he was 3 months old and grew steadily over time. The child was otherwise healthy, with all immunizations completed. Examination revealed multiple nodular lesions varying

in size from 5 to 15 mm. They were distributed mainly on the scalp and the extremities. They were shiny, yellowish in color, rubbery and nontender (Figure 4). All other systems and laboratory findings were normal. The histopathological examination showed histiocytes, lymphocytes and occasional Touton cells. Diagnosis of JXG was made with the clinical and histopathological findings.

DISCUSSION

The first case of xanthogranuloma was reported in 1905 by Adamson who named the disorder "congenital xanthoma multiplex".³ The term JXG was suggested in 1954 based upon histologic findings of xanthomatous histiocytes and giant cells.⁴ Since multiple cases were reported with different names and many of them may go undiagnosed or misdiagnosed as other common skin tumors, the true incidence can not be estimated. In childhood there is a male predominance of approximately 1.5:1 and almost 75% of cases appear during the first year of life, over 15% being noted at birth.^{1,2} All of our patients were male, and all of the lesions occurred before the age of 1 year.

Although the cause of juvenile xanthoma is unknown, it is suggested that the condition is reactive with histiocytes possibly responding to a traumatic or infectious stimulus. However, the reason for the progressive lipidation of histiocytes in the absence of hyperlipidemia is not clear.¹ Some authors suggest that the dermal dendrocyte is the precursor cell for JXG and its variants, based on occasional Factor XIIIa positivity. Systemic involvement is one of the strongest arguments against the dermal dendrocyte being the precursor cell. Others have implicated the plasmacytoid dendritic cell.⁵ However, it is suggested that generalized eruptive histiocytoma, benign sephalic histiocytosis and JXG may represent different expressions of the same disorder.⁶

The lesions are smooth, firm, domeshaped papules and nodules initially pink or redbrown which rapidly turn to yellow. Two main clinical forms were described. A small nodular form (60%) and a large nodular form (40%). Both forms frequently coexist. Lesions are often localized to the

head and neck and occur less often on the trunk and the extensor surface of the extremities.^{1,2} Mucosal involvement is rare and presents as a solitary yellow nodule on the lateral aspect of the tongue. Unusual presentations include keratotic, pedunculated, subcutaneous, clustered, plaque-like and giant lesions.¹ In one of our patients, the clinical form was large nodular and the other two presented with the mixed form.

Extracutaneous lesions were reported in many organs, the eye being most commonly involved. Ocular involvement usually occurs before 2 years of age with multiple skin lesions and may cause blindness. Systemic involvement of the lung, spleen, liver, bone and a lethal form with aggressive nervous system involvement, hypertension and hydrocephalus was described.^{2,7} We did not establish a correlation between the number of lesions and systemic involvement. The combined occurrence of JXG and cafe aulait macules (Neurofibromatosis type 1) suggests an increased risk for myelomonocytic leukemia and it is called 'triple association'.^{2,8} In our patients, there was no systemic involvement and association with other diseases. Longterm follow-up was planned for all cases.

A biopsy material typically demonstrates, as in our patients, well-demarcated dense infiltration of histiocytes in the dermis. In mature lesions the histiocytes develop lipid in their cytoplasm creating a foamy "xanthomatous" appearance. Touton giant cells are characteristic findings.¹

Clinical differential diagnosis must be made with other Langerhans or non-Langerhans cell histiocytosis, xanthoma disseminatum and other skin tumors; the diagnosis should be verified by histopathological examination.

JXG usually runs a quite benign course with spontaneous regression occurring over 3 to 6 years. Pigmentary alteration, atrophy, or anetoderma-like changes may persist in areas of prior skin involvement.²

In conclusion, JXG occasionally may be underestimated and may go misdiagnosed as other common skin tumors. Histopatological examination must be made for the true diagnosis and systemic involvement must be investigated.

REFERENCES

1. Goodman WT, Barret TL. Histiocytoses. In: Bologna JL, Jorizzo J, Rapini R, eds. Vol.1. *Dermatology*. 1st ed. Edinburgh: Mosby; 2003. p. 1429-45.
2. Cambazard F, Stephan JL. Langerhans'cell and non langerhans'cell histiocytosis. In: Harper J, Oranje A, Prose N, eds. Vol. 2. *Text Book of Pediatric Dermatology*. 2nd ed. Oxford: Blackwell Publishing; 2002.p. 1415-32.
3. Adamson NF. Congenital xanthogranuloma multiplex in a child. *Br J Dermatol* 1905;17:222-3.
4. Helwig EB, Hackney VC. Juvenile xanthogranuloma (nevoxanthoendothelioma). *Am J Surg Pathol* 1954;30:625-6.
5. Wollina U, Burgdorf WH, Haroske G Disseminated juvenile xanthogranuloma. *J Dtsch Dermatol Ges* 2006;4:45-8.
6. Gianotti R, Alessi E, Caputo R.. Benign cephalic histiocytosis: a distinct entity or a part of a wide spectrum of histiocytic proliferative disorders of children? A histopathological study. *Am J Dermatopathol* 1993;15:315-9.
7. Flach DB, Winkelmann RK.. Juvenile xanthogranuloma with central nervous system lesions *J Am Acad Dermatol* 1986;14:405-11.
8. Zvulunov A, Barak Y, Metzker A. Juvenile xanthogranuloma, neurofibromatosis, and juvenile chronic myelogenous leukemia. World statistical analysis *Arch Dermatol* 1995;131:904-8.