

# Primary Angioplasty in Very Old Patients with Acute Myocardial Infarction: Report of Two Cases and Review of the Literature

## Akut Miyokard İnfarktüsü Çok Yaşlı Hastalarda Primer Anjiyoplasti: İki Olgu Sunumu ve Literatürün Gözden Geçirilmesi

Recai ALEMDAR,<sup>a</sup>  
Onur CAĞLAR,<sup>a</sup>  
Hakan ÖZHAN,<sup>a</sup>  
Cengiz BAŞAR,<sup>a</sup>  
İsmail ERDEN,<sup>a</sup>  
Mesut AYDIN,<sup>a</sup>  
Hayati KANDIŞ<sup>b</sup>

Departments of  
<sup>a</sup>Cardiology,  
<sup>b</sup>Emergency Medicine,  
Düzce University Faculty of Medicine,  
Düzce

Geliş Tarihi/Received: 04.03.2010  
Kabul Tarihi/Accepted: 04.08.2010

Yazışma Adresi/Correspondence:  
Hakan ÖZHAN  
Düzce University Faculty of Medicine,  
Department of Cardiology, Düzce,  
TÜRKİYE/TURKEY  
ozhanhakan@yahoo.com

**ABSTRACT** There is limited data regarding treatment of acute myocardial infarction in very old patients. The very elderly population has complex co-morbidities, worse left ventricular function, poor functional status, increased risk, and reduced benefit from treatment. Contraindications to lytic therapy are common in the elderly, and the incidence of hemorrhagic stroke after thrombolytic therapy is strictly associated with age. Primary percutaneous coronary angioplasty results were also limited in octogenarians and nonagenarians. We report here two patients in 89 and 93 years who were admitted to the cardiology department with the diagnosis of acute myocardial infarction and subsequently treated with percutaneous intervention. The results of primary coronary angioplasty in old patients were also discussed in light of the literature.

**Key Words:** Angioplasty, transluminal, percutaneous coronary; myocardial infarction

**ÖZET** Çok yaşlı hastalarda miyokard infarktüsü tedavisi ile ilgili sınırlı sayıda çalışma mevcuttur. Bu olgularda eşlik eden hastalıklar sıklıkla, sol ventrikül fonksiyonları kötüdür, fonksiyonel kapasite düşük, risk yüksek ve tedaviden elde edilecek yarar fazla değildir. Ayrıca trombolitik tedavi kontrendikasyonları bu grupta yaygın olup trombolitik tedavi sonrası hemorajik inme yaşla sıkı bir ilişki göstermektedir. Seksen ve doksan yaş üzeri hastalarda primer perkütan koroner anjiyoplasti konusunda da veriler yetersizdir. Burada 89 ve 93 yaşlarında, akut miyokard infarktüsü ile kardiyo- yoloji servisine yatırılan ve primer perkütan işlemlerle tedavi edilen iki hasta sunulmaktadır. Çok yaşlı hastalarda primer anjiyoplasti sonuçları literatür ışığında tartışılmıştır.

**Anahtar Kelimeler:** Anjiyoplasti, translüminal, perkütan koroner; miyokard infarktüsü

**Türkiye Klinikleri J Cardiovasc Sci 2012;24(2):144-7**

The elderly population has been steadily increasing. The prevalence of coronary heart disease increases depend on age. The rapid growth of the elderly population will cause an increase in the number of the elderly persons being referred and considered for percutaneous coronary revascularization. Most randomized studies that show a benefit from coronary revascularization, have usually selected patients who are under the age of seventy five. Evidence-based data guiding coronary revascularization in the elderly particularly in the very elderly have been limited to randomized clinical trials.<sup>1,2</sup>

The very elderly population has complex co-morbidities, worse left ventricular (LV) function, poor functional status, increased risk, and reduced benefit from treatment.<sup>3,4</sup> Contraindications to lytic therapy are com-

mon in the elderly, and the incidence of hemorrhagic stroke after thrombolytic therapy is strictly associated with age.<sup>5,6</sup> Primary coronary balloon angioplasty has been shown to be beneficial in high-risk patient groups.<sup>7</sup> We present a case of primary angioplasty to the right coronary artery in two very old patients who presented with myocardial infarction.

## CASE REPORT

### CASE 1

A 89 years old woman presented to emergency department with acute onset crushing chest pain for the last 2 hours. Her history revealed hypertension. Her blood pressure was 110/60 mmHg and heart rate was 75/min. The electrocardiogram showed acute inferoposterolateral myocardial infarction with atrial fibrillation (Figure 1). Inferior and posterior wall hypokinesia was confirmed with echocardiographic assessment. Aspirin and clopidogrel were administered and immediately transferred to catheter lab for primary percutaneous coronary intervention. Coronary angiogram revealed 100% occlusion of the dominant right coronary artery (RCA) in the proximal part, with normal left circumflex and left anterior descending artery (Figure 2). Thrombolysis in myocardial infarction (TIMI) III flow was achieved after stenting of the culprit lesion (Figure 3). The procedure was completed without any complications and ECG after the intervention showed significant restoration of the ST waves (Figure 4). She was discharged after a week and was doing well at her first month visit.

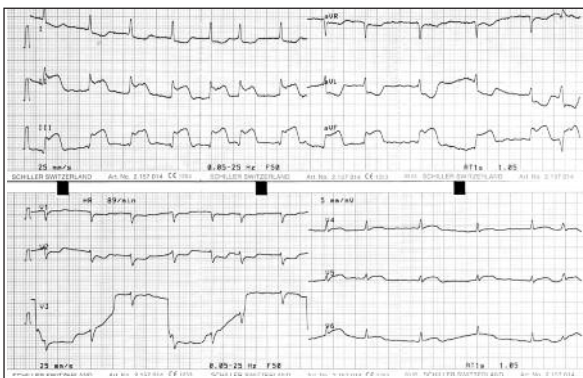


FIGURE 1: First case's ECG on admission.

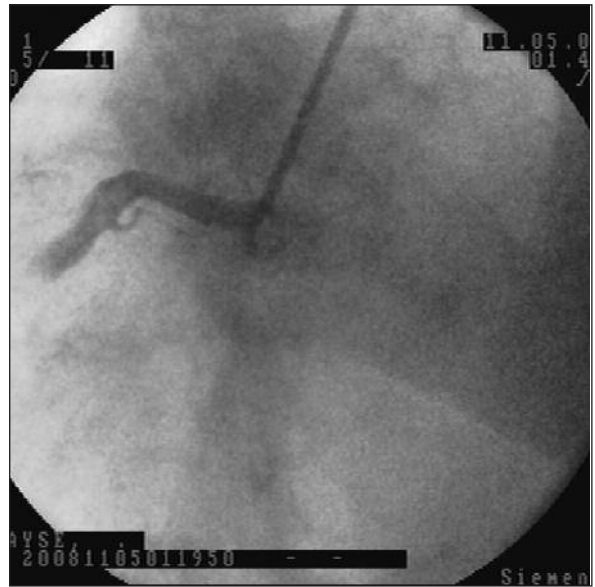


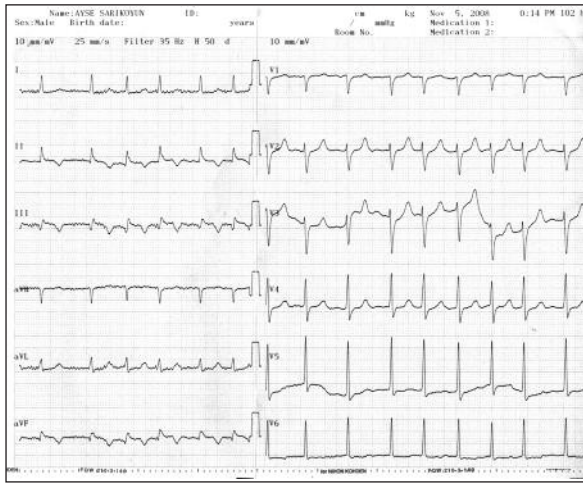
FIGURE 2: The coronary angiogram revealed 100% occlusion of the right coronary artery in the first case.

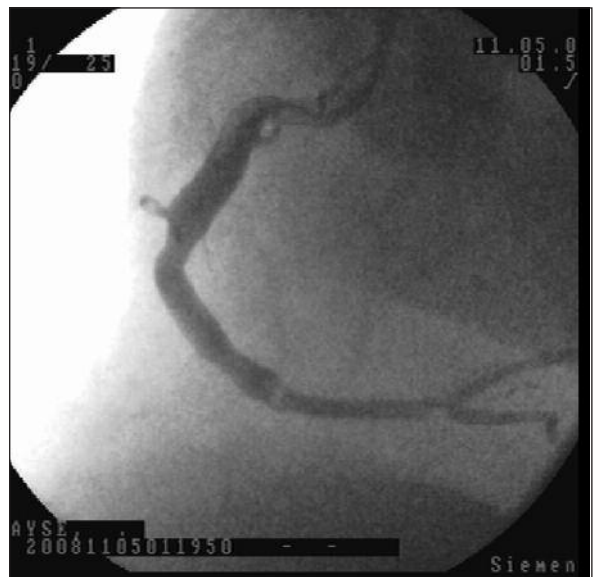

FIGURE 3: Primary percutaneous intervention restored TIMI III flow in the first case.

### CASE 2

A 93 years old man presented to emergency department with acute onset crushing chest pain for the last 1 hour. History was unremarkable. His blood pressure was 90/60 mmHg and heart rate was 105/min. The electrocardiogram showed acute anterior myocardial infarction. Aspirin and clopidogrel were administered and the patient was transferred to catheter lab for primary percuta-



**FIGURE 4:** First case's ECG after primary coronary angioplasty showing reperfusion.

neous coronary intervention. Coronary angiogram revealed 100% occlusion of the left anterior descending (LAD) artery. The culprit lesion was stented and a final TIMI 1-2 flow was achieved. Due to lack of the catheter, intraaortic balloon pump could not be inserted. After admission to the coronary care unit, the patient had a cardiac arrest and died after unsuccessful resuscitation.

## DISCUSSION

The management of STEMI in patients over 75 years old is of growing importance since life expectancy of the population is gradually increasing, especially in industrialized countries. Controlled trials showed superiority of primary percutaneous coronary intervention (PCI) over thrombolysis in both younger and elderly patients.<sup>8</sup> However adverse comorbid conditions of the elderly causes prolonged hospital stay, greater adverse ischemic and noncardiac events, and increased early and late mortality compared with their younger counterparts.<sup>9,10</sup>

There is limited data regarding treatment of acute myocardial infarction in octogenarians.<sup>11-14</sup> The elderly patients usually have more severe symptoms, they frequently present with acute coronary syndrome, multiple-vessel diseases are more frequent, they have more calcification on the coronary lesions and they have more co-morbid conditions.<sup>12</sup> When octogenarians were compared

with younger patients regarding complications of PCI, several studies showed lower success rates.<sup>13,14</sup>

Nonagenarians on the other hand, are almost entirely absent from randomized clinical trials. The first case series reported by Wu et al showed basic features, including symptoms, number of diseased coronary arteries, heart function, coronary calcification and co-morbidity are comparable to previous reports of patients with ages under 89 years. The success rate in the mentioned series was also high. The only drawback recorded was the hospitalization duration after the procedure which was very long (a mean of 14 days).<sup>15</sup> Another study by Lee et al. showed that with careful patient selection, PCI can be performed in nonagenarians. While an operator might be concerned about excessive calcification and tortuosity or severe diffuse disease, in this series, procedural success was 100%. They also showed that use of Drug eluting stent (DES) is reasonable in nonagenarians and age itself should not be an exclusion criterion. The final and important clue of their study is that biological age and chronological age should be handled as different entities while assessing individual patients.<sup>16</sup> Parikh et al showed that hypotension and low ejection fraction correlated with in-hospital mortality and worst clinical outcome in 32 consecutive nonagenarian patients undergoing PCI.<sup>17</sup> Teplitzky et al also showed that in their cohort consisting of 65 nonagenarians, cumulative mortality at 6 month was 0% in patients with stable angina and 23% in emergent PCI scenario (STEMI or NSTEMI).<sup>18</sup> Even with careful patient selection it seems that age remains a powerful risk factor for complications that may frighten away physicians from performing procedures on high risk patients. When major complications occur, the very elderly patient is unlikely to have the resiliency to recover.<sup>19</sup>

The results of the presented cases were in concordant with the literature. The oldest patient presented with cardiogenic shock and beside the successful PCI died several hours after the intervention. The first case on the other hand, was successfully treated with primary PCI and discharged without any complications.

Taking into account that nonagenarians may have very tortuous and complex lesions, interventional cardiologists may have to use special equipment for crossing the lesion. The Venture catheter has previously been documented for use in tortuous vessels, chronic total occlusion and in cases of complex interventions.<sup>20</sup> Initial attempts to cross the lesions should be made with soft guidewires in order to prevent dissection. However hydrophilic-coated 0.014" guidewires such as the BMW (Guidant Corp., Santa Clara, CA, USA) and the Choice PT2 (Boston Scientific., Natick, MA, USA) may be better selections and can be used with caution.<sup>21</sup> Stent selection is also important. Longitudinal flexibility is an important property of coronary stents, facilitating de-

livery and allowing the expanded stent to conform to vessel contour. Comparison of 13 stents showed that Multilink was the most flexible stent.<sup>22</sup> Enoxaparin dosage should also be maintained according to the glomerular filtration rate (GFR). After four loading doses of 1 X mg kg<sup>-1</sup> X body weight/12 hours, the dose should be reduced 10% by every increment of 10 ml/min in GFR.<sup>23</sup>

In conclusion, age itself is not a limitation for adapting primary PCI to treat the elderly, octogenarians and nonagenarians in strict speaking. In the future, larger prospective studies of nonagenarians managed medically or percutaneously should be performed to characterize further their outcomes.

## REFERENCES

- Graham MM, Norris CM, Galbraith PD, Knudtson ML, Ghali WA; APPROACH Investigators. Quality of life after coronary revascularization in the elderly. *Eur Heart J* 2006;27(14):1690-8.
- Cohen HA, Williams DO, Holmes DR Jr, Selzer F, Kip KE, Johnston JM, et al; NHLBI Dynamic Registry. Impact of age on procedural and 1-year outcome in percutaneous transluminal coronary angioplasty: a report from the NHLBI Dynamic Registry. *Am Heart J* 2003;146(3):513-9.
- Moreno R, Salazar A, Bañuelos C, Hernández R, Alfonso F, Sabatè M, et al. Effectiveness of percutaneous coronary interventions in nonagenarians. *Am J Cardiol* 2004;94(8):1058-60.
- Hassani SE, Wolfram RM, Kuchulakanti PK, Xue Z, Gevorkian N, Suddath WO, et al. Percutaneous coronary intervention with drug-eluting stents in octogenarians: characteristics, clinical presentation, and outcomes. *Catheter Cardiovasc Interv* 2006;68(1):36-43.
- Kaplan KL, Fitzpatrick P, Cox C, Shammas NW, Marder VJ. Use of thrombolytic therapy for acute myocardial infarction: effects of gender and age on treatment rates. *J Thromb Thrombolysis* 2002;13(1):21-6.
- Lichtman JH, Krumholz HM, Wang Y, Radford MJ, Brass LM. Risk and predictors of stroke after myocardial infarction among the elderly. *Circulation* 2002;105(9):1082-7.
- Berger AK, Schulman KA, Gersh BJ, Pirzada S, Breall JA, Johnson AE, et al. Primary coronary angioplasty vs thrombolysis for the management of acute myocardial infarction in elderly patients. *JAMA* 1999;282(4):341-8.
- Antoniucci D, Valenti R, Santoro GM, Bolognese L, Moschi G, Trapani M, et al. Systematic primary angioplasty in octogenarian and older patients. *Am Heart J* 1999;138(4Pt1):670-4.
- Batchelor WB, Anstrom KJ, Muhlbaier LH, Grosswald R, Weintraub WS, O'Neill WW, et al. Contemporary outcome trends in the elderly undergoing percutaneous coronary interventions: results in 7,472 octogenarians. *J Am Coll Cardiol* 2000;36(3):723-30.
- Graham MM, Ghali WA, Faris PD, Galbraith PD, Norris CM, Knudtson ML; for the Alberta Provincial Project for Outcomes Assessment in Coronary Heart Disease (APPROACH) Investigators. Survival after coronary revascularization in the elderly. *Circulation* 2002;105(20):2378-84.
- Jeroudi MO, Kleiman NS, Minor ST, Hess KR, Lewis JM, Winters WL Jr, et al. Percutaneous transluminal coronary angioplasty in octogenarians. *Ann Intern Med* 1990;113(6):423-8.
- Myler RK, Webb JG, Nguyen KP, Shaw RE, Anwar A, Schechtman NS, et al. Coronary angioplasty in octogenarians: comparisons to coronary bypass surgery. *Cathet Cardiovasc Diagn* 1991;23(1):3-9.
- Santana JO, Haft JI, LaMarche NS, Goldstein JE. Coronary angioplasty in patients eighty years of age or older. *Am Heart J* 1992;124(1):13-8.
- Klein LW, Block P, Brindis RG, McKay CR, McCallister BD, Wolk M, et al. Percutaneous coronary interventions in octogenarians in the American College of Cardiology-National Cardiovascular Data Registry: development of a nomogram predictive of in-hospital mortality. *J Am Coll Cardiol* 2002;40(3):394-402.
- Wu YJ, Hou CJY, Chou YS, Tsai CH. Percutaneous coronary intervention in nonagenarians. *Acta Cardiol Sin* 2004;20(1):73-82.
- Lee MS, Zimmer R, Pesseguero A, Jurewitz D, Tobis J. Outcomes of nonagenarians who undergo percutaneous coronary intervention with drug-eluting stents. *Catheter Cardiovasc Interv* 2008;71(4):526-30.
- Parikh R, Chennareddy S, Debari V, Hamdan A, Konlian D, Shamoon F, et al. Percutaneous coronary interventions in nonagenarians: in-hospital mortality and outcome at one year follow-up. *Clin Cardiol* 2009;32(12):E16-21.
- Teplitzky I, Assali A, Lev E, Brosh D, Vaknin-Assa H, Kornowski R. Results of percutaneous coronary interventions in patients > or =90 years of age. *Catheter Cardiovasc Interv* 2007;70(7):937-43.
- Bhatt DL. Percutaneous coronary intervention in nonagenarians: age before beauty? *Catheter Cardiovasc Interv* 2008;71(4):531-2.
- McClure SJ, Wahr DW, Webb JG. Venture wire control catheter. *Catheter Cardiovasc Interv* 2005;66(3):346-50.
- Ikeno F, Yeung AC. Equipment for PCI. In: Spencer B, King III, Yeung AC, eds. *Interventional Cardiology*. 1sted. China: The McGraw-Hill Companies; 2007. p.79-85.
- Ormiston JA, Dixon SR, Webster MW, Ruygrok PN, Stewart JT, Minchington I, et al. Stent longitudinal flexibility: a comparison of 13 stent designs before and after balloon expansion. *Catheter Cardiovasc Interv* 2000;50(1):120-4.
- Green B, Greenwood M, Saltissi D, Westhuyzen J, Klaver L, Rowell J, et al. Dosing strategy for enoxaparin in patients with renal impairment presenting with acute coronary syndromes. *Br J Clin Pharmacol* 2005;59(3):281-90.