

Hydrotic Ectodermal Dysplasia Associated with A Rib Anomaly

KOSTA KEMİĞİ ANOMALİSİ İLE BİRLİKTE GÖRÜLEN BİR HİDROTİK EKTODERMAL DİSPLAZİ OLGUSU

Mustafa ÖZDEMİR, MD,^a Burhan ENGİN, MD,^a İbrahim BAYSAL, MD^a

^aDepartment of Dermatology, Selçuk University Meram Faculty of Medicine, KONYA

Abstract

Ectodermal dysplasias are a heterogeneous group of disorders comprising different clinical conditions. Hydrotic ectodermal dysplasia is an autosomal dominant disorder characterized by hair anomalies, nail dystrophy and palmoplantar keratoderma. We report a 15-year-old boy having characteristic findings of hydrotic ectodermal dysplasia with a rib anomaly.

Key Words: Ectodermal dysplasia; abnormalities

Türkiye Klinikleri J Dermatol 2007, 17:205-209

Özet

Ektodermal displaziler farklı klinik durumları içeren heterojen bir grup hastalıktır. Hidrotik ektodermal displazi otozomal dominant geçişli bir bozukluk olup saç anomalileri, tırnak distrofisi ve palmoplantar keratoderma ile karakterizedir. Burada hidrotik ektodermal displazinin karakteristik özelliklerini gösteren ve kosta kemiği anomalisi olan 15 yaşında bir erkek olgu sunuyoruz.

Anahtar Kelimeler: Ektodermal displazi; anomali

Ectodermal dysplasias can affect only ectodermal tissues, or comprise part of a syndrome. Hydrotic ectodermal dysplasia is a rare autosomal dominant epidermal disorder characterized by primary disorders in at least 2 ectodermal structures such as dystrophic to hypoplastic nails, alopecia, atrichosis and palmoplantar keratoderma.^{1,2} Here, we demonstrate a new feature of this syndrome.

Case Report

A 15-year-old boy presented with palmoplantar keratoderma and congenital universal alopecia (atrachia congenita) (Figure 1). There was no hair on his scalp at birth and his palmoplantar surfaces were normal at the first 2 years of life. At the age

of three, keratosis started to appear on both his soles and then on the palms. Painful fissures developed on the keratotic lesions with time. He was not born to consanguineous parents and was the first of 4 siblings. His other family members did not manifest similar lesions but a younger brother had psoriasis vulgaris.

On clinical examination, the patient had congenital universal alopecia and he ever had any hair in any body location such as eyelashes, eyebrows, arms, legs, axilla and groin. There were symmetric, hard, tender and thick keratotic plaques on the palms and soles (Figure 2). These keratotic plaques with dirty yellow-brown coloration were well demarcated with an erythematous rim and were fissured. The lesions had extended onto the dorsa of the distal part of the fingers and lateral surfaces of the hands and feet with time. The keratotic lesions did not lead to flexion contracture of the fingers, and full extension of the fingers was possible. In addition to mild scrotal tongue, hypertrophy of the papillae filiformes was present on the tongue.

Geliş Tarihi/Received: 06.07.2006 Kabul Tarihi/Accepted: 06.12.2006

Yazışma Adresi/Correspondence: Mustafa ÖZDEMİR, MD
Selçuk University Meram Faculty of Medicine,
Department of Dermatology, KONYA
mustafaozdemir@yahoo.com

Copyright © 2007 by Türkiye Klinikleri

Türkiye Klinikleri J Dermatol 2007, 17



Figure 1. Congenital universal alopecia and keratoderma on the palms.

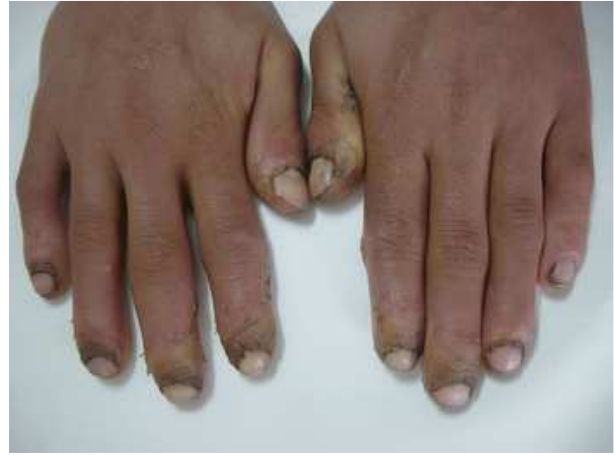

Figure 3. Periungual keratoderma and shortened nails.

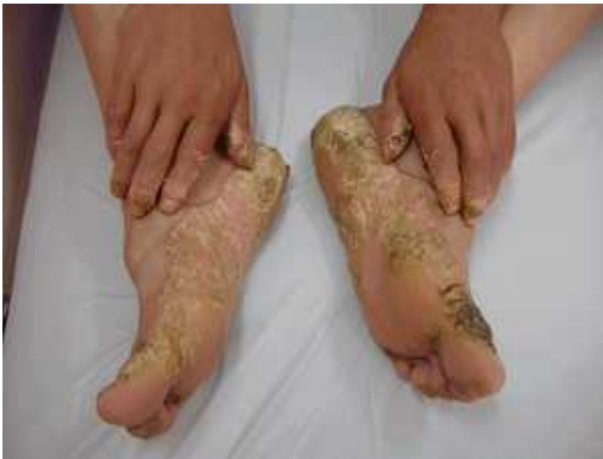

Figure 2. The keratoderma on the soles.

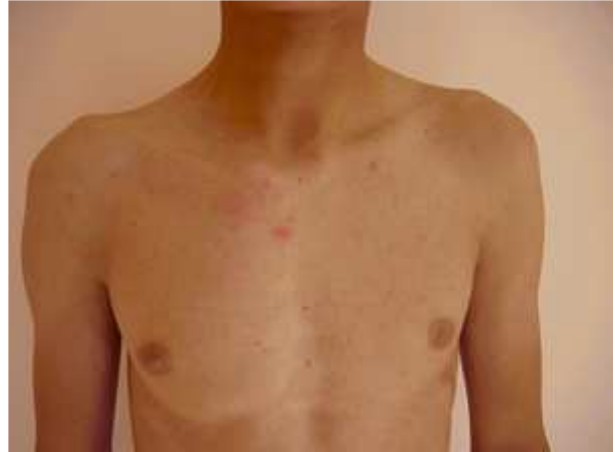

Figure 4. Prominent right hemithorax.

Clubbing-like appearance and shortened nail plate, loss of the cuticle, distal onycholysis, mild-moderate subungual debris and longitudinal striations were detected as nail dystrophy (Figure 3). The periorificial regions such as perioral, perianal and periurethral, in addition to scrotum, inguinal, popliteal and axillary areas were not involved. He had normal intelligence. Mild sensorineural and mixt type hearing loss were detected in the left and right ear (-37 dB, -40 dB respectively). There was no dental, ophthalmologic, neurological, urogenital and cardiovascular anomaly. His right hemithorax was more prominent than left hemithorax (Figure 4). It was stated that the prominent hemithorax might be resulted from the first right rib anomaly,

which was detected by chest X-ray in an orthopedic consultation. The first right rib was shorter and thinner than the first left rib (Figure 5). Radiographic examination of the skull, hands and feet were normal.

Laboratory examinations, including sedimentation rate, complete blood examination, liver enzymes, kidney function tests, urine analysis, electrolyte levels and thyroid function tests, were all normal. And also serum zinc level was within the normal limits. Except for the rib anomaly, chest roentgenogram and total abdominal ultrasonography were normal. In the biopsy of the keratotic lesion from the palmar region, there was a prominent papillomatosis with hyperkeratotic stratum

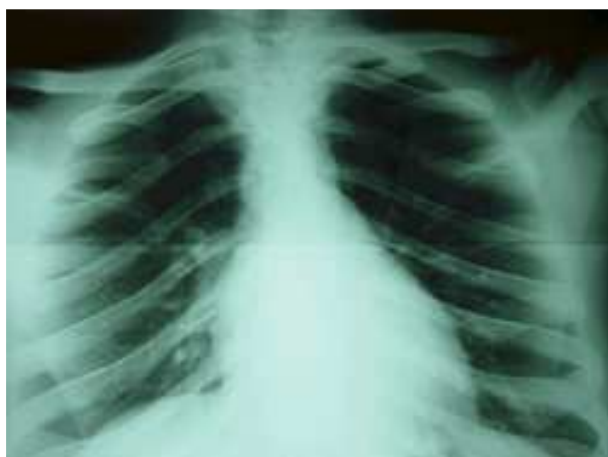

Figure 5. Radiograph showing the first right rib anomaly.

corneum. Orthokeratotic hyperkeratosis and a thick granular layer were detected in the involved epidermis. There was an increase of vascularity and a mild perivascular mononuclear inflammatory cell infiltration in the upper dermis (Figure 6).

A keratolytic agent [salicylic acid (10%) and carbamide (10%)] and topical retinoic acid 0.1% were used for 2 months. Mechanical removal of the thickened epidermis was performed occasionally by a blade. Good result was obtained by this therapeutic approach on the palms but there was only a partial improvement on the soles.

Discussion

Ectodermal dysplasias are a large group of disorders showing a variety of distinct defects of

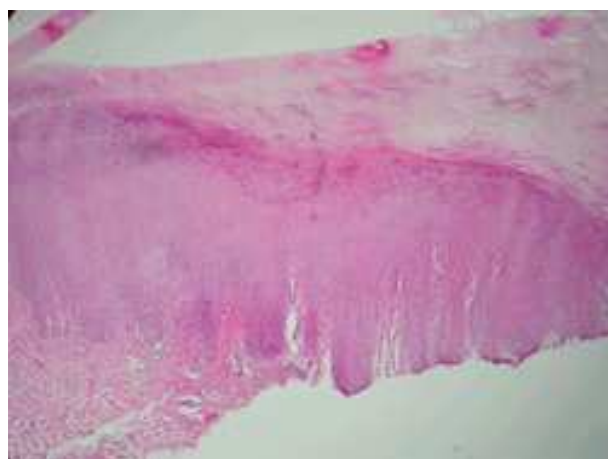


Figure 6. Orthokeratotic hyperkeratosis and a thick granular layer (haematoxylin and eosin; X 10).

ectoderm-derived tissues. These defects can include anomalies in hair, teeth, nails and sweat glands and also they can include anomalies in other organs and systems.¹⁻⁴ According to the most commonly used classification of ectodermal dysplasias: '1' indicates hair dysplasia, '2' dental dysplasia, '3' nail dysplasia and '4' sweat gland dysplasia.² Due to the presence or absence of these features different subgroups were identified based on various combinations of these defects.^{2,5} Freire-Maia and Pinheiro proposed two main groups classified as A and B. Group A disorders have dysplasias in at least two of the four above-mentioned structures whereas group B disorders have dysplasias in only one structure.⁶ Based on this classification, our patient would be considered to have an isolated 1, 3 ectodermal dysplasia which is an autosomal dominant condition. The parents of our case were clinically unaffected, suggesting either autosomal recessive inheritance or a *de novo* autosomal dominant mutation.

The major features of hidrotic ectodermal dysplasia are nail and hair changes and palmoplantar keratoderma.⁷ Dystrophy of the nails is the key feature of the disease.^{8,9} The nails show a wide variety of abnormalities. In our case clubbing-like appearance and shortened nail plate, loss of the cuticle, distal onycholysis, mild-moderate subungual debris and longitudinal striations were detected as nail dystrophy. Besides, the skin was thickened beneath the free edges of the nails. In patients with hidrotic ectodermal dysplasia diffuse hyperkeratosis of the palms and soles may be severe and fissuring is sometimes troublesome.^{1,9} In our patient there were symmetric, hard, tender and thick keratotic plaques on the palms and soles. These keratotic plaques with dirty yellow-brown coloration were fissured and well demarcated with an erythematous rim. The scalp hair of this subgroup of ectodermal dysplasia may be sparse, brittle or completely absent. The eyebrows are thinned or absent, the lashes are few and short, and pubic and axillary hair are sparse or absent.^{1,9} Our patient had congenital universal alopecia and he ever had any hair in any body location such as eyelashes, eyebrows, arms, legs, axilla and groin.

In our case general physical development was normal. There weren't any neurologic, urogenital and cardiovascular anomalies. The teeth didn't show any characteristic defect. On ophthalmologic examination premature cataract wasn't detected. Mental development of the patient was normal. Hearing impairment was reported in various ectodermal dysplasias including keratitis-ichthyosis-deafness (KID) syndrome, ectrodactyly, ectodermal dysplasia and clefting (EEC) syndrome and Johanson-Blizzard syndrome.^{6,10,11} The Clouston syndrome is associated with mutations in *GJB6* (connexin 30). A phenotype resembling the Clouston syndrome with sensorineural deafness was showed with a same mutation. On physical examination mild scalp hypotrichosis, erythematous plaques and 20-nail dystrophy were recorded in this syndrome.¹² In our patient nonprogressive mild sensorineural and mixt type hearing loss were detected in the left and right ear, respectively. In comparison with the phenotype resembling the Clouston syndrome, we reported congenital universal alopecia and nail dystrophy as shortened nail plate, loss of the cuticle, distal onycholysis, mild-moderate subungual debris and longitudinal striations. In addition these findings, we detected palmoplantar keratoderma and short rib anomaly in our patient as different features.

As a different finding from those of the previously reported cases, we detected a rib anomaly. The short rib-polydactyly syndrome (SRPS) group is manifested by short-limb short stature, short ribs with thoracic hypoplasia, and polydactyly. This heterogeneous group of recessively inherited disorders may be accompanied by ectodermal dysplasia.¹³ Our patient had only the first right rib anomaly that let to a right prominent hemithorax. And also patient's feet and hands were normal.

Osseous anomaly was reported in some ectodermal dysplasias. For instance EEC syndrome is characterized by ectrodactyly, ectodermal dysplasia and cleft lip/cleft palate. Syndactyly may be a manifestation of this syndrome also. AEC syndrome shares the ectodermal dysplasia and clefting with EEC syndrome. Limb involvement in AEC syndrome is minimal or absent.^{14,15} Osseous

anomalies reported in these ectodermal dysplasias were different from our patient's. We didn't detect a cleft lip/cleft palate or a syndactyly. Martinez et al¹⁶ described a case with cleft lip and palate, syndactyly and other findings. Zlotogora-Ogür syndrome is considered to have disorders such as ectodermal dysplasia, cleft lip and palate, mental retardation, syndactyly of fingers, accessory nipples and ear anomalies. Moreover in a recently described multiple malformation syndrome, frontal bossing, maxillary hypoplasia, osseous syndactyly and broad metacarpals, hypoplastic toes and absent distal phalanges were reported.^{16,17} In our case, we detected the first right rib anomaly that was shorter and thinner than the left one and this osseous anomaly may be a new finding of ectodermal dysplasias.

REFERENCES

1. Lamartine J. Towards a new classification of ectodermal dysplasias. *Clin Exp Dermatol* 2003;28:351-5.
2. Harrison S, Sinclair R. Hypotrichosis and nail dysplasia: A novel hidrotic ectodermal dysplasia. *Australas J Dermatol* 2004;45:103-5.
3. Priolo M, Laganà C. Ectodermal dysplasias: a new clinical-genetic classification. *J Med Genet* 2001;38:579-85.
4. Priolo M, Silengo M, Lerone M, Ravazzolo R. Ectodermal dysplasias: not only 'skin' deep. *Clin Genet* 2000;58:415-30.
5. Pinheiro M, Freire-Maia N. Ectodermal dysplasias: a clinical classification and a causal review. *Am J Med Genet* 1994;53:153-62.
6. Itin PH, Fistarol SF. Ectodermal dysplasias. *Am J Med Genet C Semin Med Genet* 2004;131:45-51.
7. Tan E, Tay Y-K. What syndrome is this? Hidrotic ectodermal dysplasia (Clouston syndrome). *Pediatr Dermatol* 2000;17:65-7.
8. Rogers M. Nail manifestations of some important genetic disorders in children. *Dermatol Therapy* 2002;15:111-20.
9. Lamartine J, Laoudj D, Blanchet-Bardon C, et al. Refined localization of the gene for Clouston syndrome (hidrotic ectodermal dysplasia) in a large French family. *Br J Dermatol* 2000;142:248-52.
10. Gorio R, Haas R, Jaimovich L. Ectodactyly, ectodermal dysplasia and clefting (EEC) syndrome. *J Eur Acad Dermatol* 2003;17:348-72.
11. Vieira MW, Lopes VL, Teruya H, Guimaraes-Lamonato L, Oliveira LC, Costa CD. Johanson-Blizzard syndrome: the importance of differential diagnostic in pediatrics. *J Pediatr (Rio J)* 2002;78:433-6.
12. van Steensel MA, Steijlen PM, Bladergroen RS, Hoefsloot EH, van Ravenswaaij-Arts CM, van Geel M. A phenotype resembling the Clouston syndrome with deafness is associated with a novel missense *GJB2* mutation. *J Invest Dermatol* 2004;123:291-3.

13. Elcioglu NH, Hall CM. Diagnostic dilemmas in the short rib-polydactyly syndrome group. *Am J Med Genet* 2002;111:392-400.
14. Mansur AT, Aydingoz IE, Kocaayan N. A case of EEC syndrome with peri/intraoral papillomatosis and widespread freckling. *J Dermatol* 2006;33:225-6.
15. Brunner HG, Hamel BC, Van Bokhoven H. The p63 gene in EEC and other syndromes. *J Med Genet* 2002;39:377-81.
16. Freihofer HPM, Walji S, Brunner HG. Ectodermal dysplasia, cleft lip/palate, and severe cutaneous and osseous syndactyly in a mentally retarded girl: A new multiple malformation syndrome. *Am J Med Genet* 1997;70:211-5.
17. Zlotogora J, Zilberman Y, Tenenbaum A, Wexler MR. Cleft lip and palate, pili torti, malformed ears, partial syndactyly of fingers and toes, and mental retardation: A new syndrome? *J Med Genet* 1987;24:291-3.