

# Atypical Cogan's Syndrome: Case Report

## Atipik Cogan Sendromu

Cemal ÇAVDARLI,<sup>a</sup>  
Soner KESKİN,<sup>b</sup>  
Mehmet Numan ALP,<sup>a</sup>  
Handan AKIL<sup>c</sup>

<sup>a</sup>Clinic of Ophthalmology,  
Ankara Numune Training and  
Research Hospital, Ankara

<sup>b</sup>Clinic of Ophthalmology,  
Aydın Atatürk State Hospital, Aydın

<sup>c</sup>Clinic of Ophthalmology,  
Giresun Op. Dr. Ergun Özdemiş Görele  
State Hospital, Giresun

Geliş Tarihi/Received: 04.09.2013  
Kabul Tarihi/Accepted: 21.12.2013

*This study was presented as a poster at  
Congress of 46<sup>th</sup> Turkish Ophthalmology  
Association, 17-21 October, Turkey, Antalya.*

Yazışma Adresi/Correspondence:  
Cemal ÇAVDARLI  
Ankara Numune Training and  
Research Hospital,  
Clinic of Ophthalmology, Ankara,  
TÜRKİYE/TURKEY  
ccavdarli@gmail.com

**ABSTRACT** Cogan's Syndrome is an uncommon autoimmune disease that seem with ocular and auditar findings. A 70 year old woman admitted with a history of blurred vision, redness, tumescence in both eyes for over a month. Her recent auditive problem was diagnosed as sensorineural hearing loss. Best corrected Snellen visual acuity was 20/100 at the right and 20/200 at the left eye. She had bilateral conjunctival hyperemia, chemosis with left ophthalmoplegia. Fundus examination revealed intraretinal hemorrhages and exudates at the macula in the right eye, exudative retinal detachment in the left eye. Ocular B-scan ultrasound was performed and bilateral 'T-sign' was detected, associated with posterior scleritis. Blood tests revealed increased erythrocytes sedimentation rate and high C Reactive Protein levels. Systemic and topical steroid therapy was given that resulted with improved vision and regression at conjunctival hyperemia, chemosis, ophthalmoplegia and retinal exudates. But the sensorineural hearing loss didn't recover. The variable presentation of this rare syndrome, delay in diagnosis is common and can lead visual and auditory disorders. Prognosis is better when it is remembered at multisystemic symptoms and atypical findings.

**Key Words:** Cogan Syndrome; scleritis; hearing loss, sensorineural; retinal detachment; ophthalmoplegia

**ÖZET** Cogan Sendromu görsel ve işitsel bulgularla seyreden otoimmün kaynaklı nadir bir hastalıktır. Yetmiş yaşında kadın hasta son bir aydır süren her iki gözde bulanık görme, kızarıklık ve şişlik şikayetiyle başvurdu. Son dönemde görsel şikayetlere sensörinöral tipte işitme kaybının da eklendiği öğrenildi. Düzeltilmiş en iyi görme keskinliği sağda 20/100, solda 20/200 olup, her iki gözünde konjonktiva hiperemisi, kemozis ve solda oftalmopleji mevcuttu. Göz dibi incelemesinde sağda retina içi kanamalar ve makülada eksudaların yanısıra solda eksudatif retina dekolmanı mevcuttu. B-mod ultrason muayenesinde arka skleritle uyumlu bilateral 'T-bulgusu' saptandı. Eritrosit sedimentasyon hızı ve C-reaktif protein düzeyi artmış bulundu. Sistemik ve topikal steroid tedavisi sonrasında her iki gözde görme keskinlikleri arttı, konjonktiva hiperemisi, kemozis, oftalmopleji ve retinal eksudalar geriledi ancak işitsel bulgularda değişiklik olmadı. Cogan Sendromu'nun nadir görülmesi ve ortaya çıkış bulgularındaki değişkenlik tedavide gecikmeye neden olabileceği için görsel ve işitsel komplikasyonlarla sonuçlanabilir. Birden fazla sistemi ilgilendiren belirtiy ve tipik olmayan bulgularla seyreden olgularda hastalığın akla getirilmesi morbiditeyi azaltacaktır.

**Anahtar Kelimeler:** Cogan Sendromu; sklerit; işitme kaybı, sensörinöral; retina dekolmanı; oftalmopleji

**Türkiye Klinikleri J Ophthalmol 2014;23(2):128-32**

**Dr.** David G. Cogan, an ophthalmologist at the Massachusetts Eye and Ear Infirmary, reported details of a syndrome of non-syphilitic interstitial keratitis (IK), iritis or subconjunctival

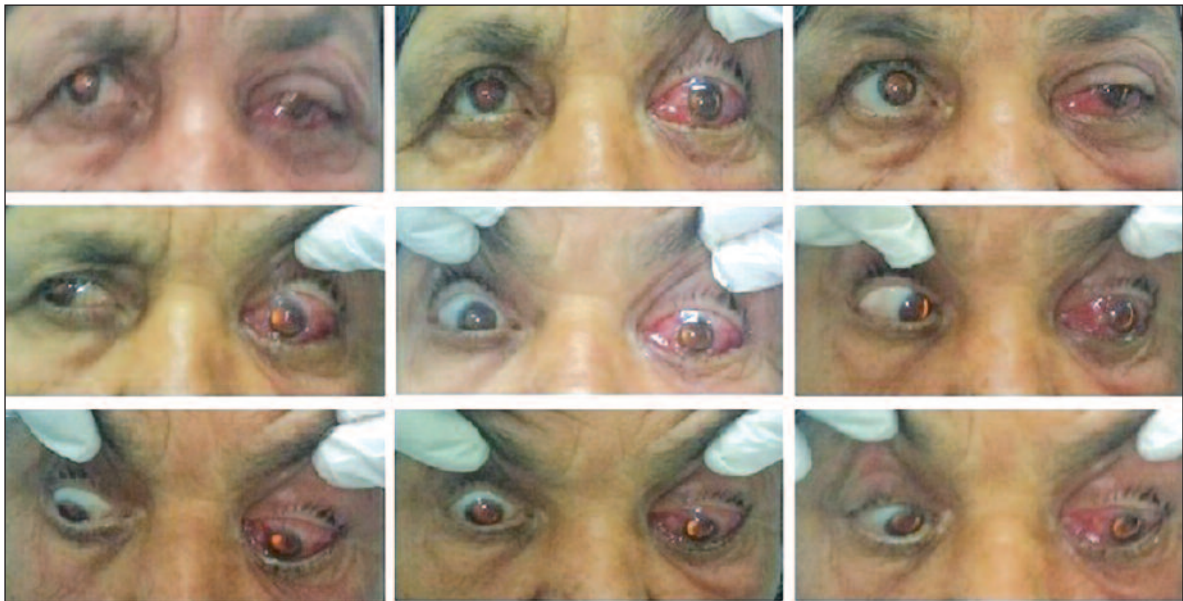bleeding and Menier's like vestibuloauditory symptoms associated with sensorineural hearing loss in 1945.<sup>1</sup> Fever, fatigue and weight loss may be present as well. Rarely, patients may have enlarged lymph nodes, rash, chest or abdominal pain, night sweats, cardiac involvement and shortness of breath.<sup>2</sup> Atypical Cogan's syndrome encompasses other ocular or vestibuloauditory symptoms like episcleritis, scleritis, posterior scleritis, retinal artery occlusion, choroiditis, retinal vasculitis, and optic disc oedema with or without IK.<sup>3</sup> The auditory symptoms can precede or follow eye disease, usually within a short period of time. If the audio-vestibular symptoms were not similar to Meniere's disease or occurred more than 2 years before or after the onset of eye symptoms, the patient was again considered to have atypical Cogan's syndrome.<sup>3</sup> Cogan's syndrome is uncommon and thus most reports deal with individual cases.<sup>4</sup> The majority of cases reported in the literature are Caucasians of either sex.<sup>5,6</sup> The etiology is unclear but an upper respiratory tract infection is frequently reported.<sup>7</sup>

We report a case of atypical Cogan's syndrome in which chemosis, episcleritis, posterior scleritis, ophthalmoplegia, exudative retinal detachment

and sensorineural hearing loss were the main features. Written informed consent was obtained from the patient for publication of this case report.

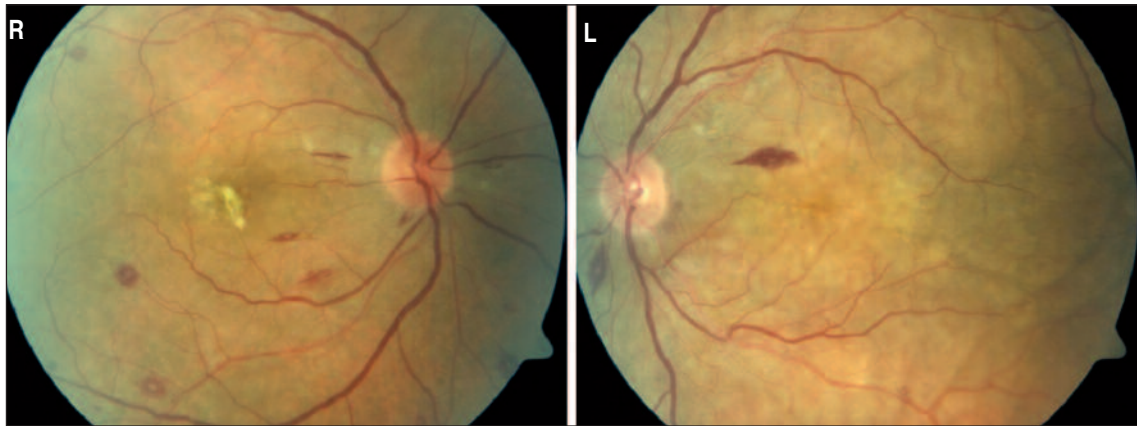
## CASE REPORT

A 70 year old woman presented to eye casualty with a history of blurred vision, redness, tumescence in both eyes for over a month. She also had bilateral hearing loss and intermittent fever for over two months. She was examined by otorhinolaryngology clinic for her auditive problem. Audiogram had been performed and diagnosed as sensorineural hearing loss. There wasn't any significant pathology at the temporal bone high resolution computed tomography She had diabetes mellitus type 2 for over 10 years under control with insulin. Best corrected Snellen visual acuity was 20/100 at the right and 20/200 at the left eye. She had bilateral conjunctival hyperemia, chemosis and mild injection with left ophthalmoplegia (Figure 1). There was no associated inflammation in the anterior chambers and corneal sensations was normal. She had bilateral mild nuclear cataract. Intraocular pressures were in normal range in both eyes. Fundus examination revealed intra-



**FIGURE 1:** Left conjunctival hyperemia, chemosis and ophthalmoplegia seems during the examination of eye movements.

(See color figure at <http://www.turkiyeklinikleri.com/journal/oftalmoloji-dergisi/1300-0365/>)



**FIGURE 2:** Intraretinal hemorrhages and exudates in the right eye (R) and exudative retinal detachment in the left eye (L).

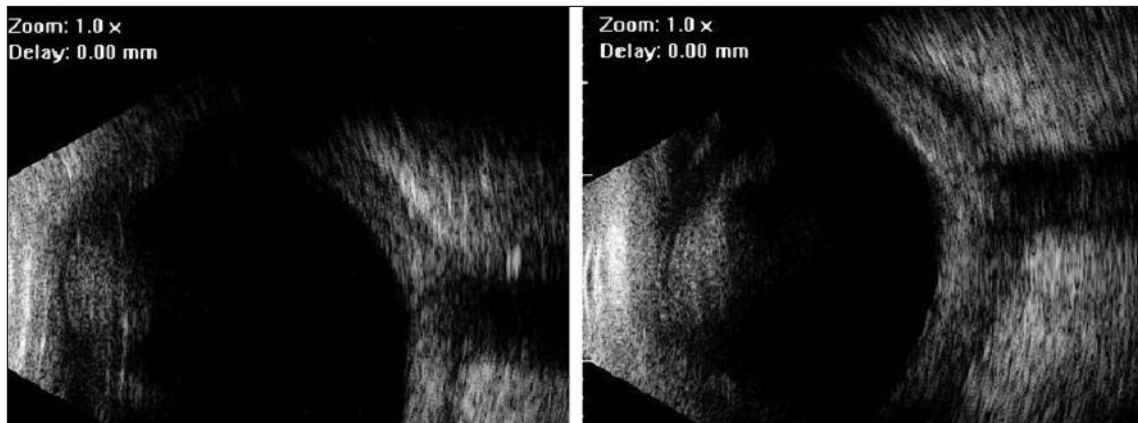
(See color figure at <http://www.turkiyeklinikleri.com/journal/oftalmoloji-dergisi/1300-0365/>)

retinal hemorrhages and exudates at the macula in the right eye, exudative retinal detachment in the left eye (Figure 2). Ocular B-scan ultrasound was performed and bilateral 'T-sign' was detected, associated with posterior scleritis (Figure 3). Blood tests showed increased erythrocytes sedimentation rate (120 mm at 1 hour) and high C Reactive Protein (CRP 20 mg/L) levels. Anti Nuclear Antibody, Anti-Neutrophil Cytoplasmic Antibody and Peripheral Antineutrophil Cytoplasmic Antibody were negative. Serum ACE was within normal limits, no antibodies were found against *Brucella*, *Treponema Pallidum* and *Borrelia burgdorferi*. During her hospitalisation, blood glucose levels were checked four times a day and were all under 180 mg/dL. Her neurologic evaluation was normal,

as were temporal bone high resolution computed tomography.

Under endocrinology observation, systemic steroid treatment first 3 days consecutive intra venous (4x250 mg methyl prednisolon), continued with oral (1 mg/kg methyl prednisolon) were given. Also bilateral topical steroids (dexamethason 0.1 mg/mL) given 5 times a day. On the 7<sup>th</sup> day, rheumatology recommended methotrexate (10 mg/week) supplementary to the therapy.

During the daily visits her vision gradually improved and conjunctival hyperemia, chemosis, vascular injection, ophthalmoplegia and retinal exudates regressed. Result Snellen visual acuity was 5/10 on right eye and 3/10 on left eye.



**FIGURE 3:** Ocular B-scan ultrasound examination shows bilateral 'T- sign' associated with posterior scleritis.

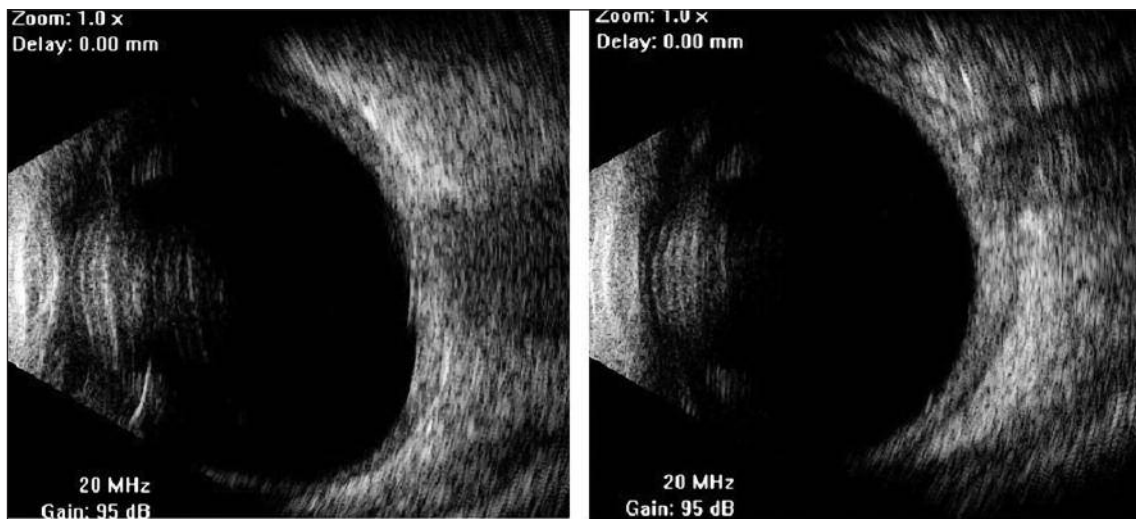


FIGURE 4: 'T-sign' disappeared in control ocular B-scan ultrasound examination after treatment.

Control ocular ultrasound performed and retinal color images taken to consider with the initial findings. We noticed that previous T-sign on ultrasound disappeared and retinal lesions regressed (Figure 4) but the sensorineural hearing loss didn't recover.

## CONCLUSION

Cogan's syndrome is generally considered an autoimmune disease but the pathogenesis of the disease is not clear. Autoimmun basis has been supported by the positive transformation of the lymphoblastic test on cochlear antigen stimulation and the demonstration of antibodies against corneal and inner ear tissue. Association with antineutrophil cytoplasmic antibodies have been reported.<sup>8</sup> However diagnosis is based on clinical findings and history.

The variability of presentation of this rare syndrome delay in diagnosis is common and can lead visual and auditory disorders. Corticosteroids are the first line of treatment and if given early in the disease course can aid recovery of the hearing. Methotrexate, azathioprine, cyclosporine, mycophenolate mofetil and cyclophosphamide have all been tried with varying degree of success.<sup>9-12</sup>

Standard autoantibody tests were all negative in this patient but in the early future, specific autoantibodies against inner ear and ocular antigens might be useful for diagnosis and prognosis.<sup>13</sup>

The ocular involvement is variable, usually bilateral and can cause moderate to severe visual loss. Vollersten et al. reported blindness in 8 out of 156 eyes, with bilateral vision loss in 2 patients.<sup>14</sup> The patient's ocular findings regressed after corticosteroid treatment and vision improved bilaterally but there was not any improvement in her auditive problem and may be related with the delay of corticosteroid therapy.

Cogan's syndrome is a multisystem disease and the patients need close cooperation of ophthalmology, rheumatology, otorhinolaryngology and physician. Today, the patient is in remission by the follow up of the related departments.

In conclusion, there are limited cases in the literature so the knowledge is inadequate. Advanced microbiological and immunological studies need to determine the pathogenesis of the disease. Multi-central clinical researches with adequate number of patients and follow up period will be guide for common understanding.

## REFERENCES

1. Cogan DG. Syndrome of nonsyphilitic interstitial keratitis and vestibuloauditory symptoms. *Arch Ophthalmol* 1945;33(2):144-9.
2. Zulian F, Sari M, de Filippis C. Otolaryngological manifestations of rheumatic diseases in children. *Int J Pediatr Otorhinolaryngol* 2009; 73(Suppl 1):S56-60.
3. Haynes BF, Kaiser-Kupfer MI, Mason P, Fauci AS. Cogan syndrome: studies in thirteen patients, long-term follow-up, and a review of the literature. *Medicine (Baltimore)* 1980;59(6): 426-41.
4. García Berrocal JR, Vargas JA, Vaquero M, Ramón y Cajal S, Ramírez-Camacho RA. Cogan's syndrome: an oculo-audiovestibular disease. *Postgrad Med J* 1999;75(883):262-4.
5. Chynn EW, Jakobiec FA. Cogan's syndrome: ophthalmic, audiovestibular, and systemic manifestations and therapy. *Int Ophthalmol Clin* 1996;36(1):61-72.
6. Kasapçopur O, Ashraf M, Caliskan S, Aktuglu C, Aslan OS, Oz F, et al. Cogan's syndrome: a rare vasculitis in childhood. *J Rheumatol* 2000;27(7):1824-5.
7. Darougar S, John AC, Viswalingam M, Cornell L, Jones BR. Isolation of *Chlamydia psittaci* from a patient with interstitial keratitis and uveitis associated with otological and cardiovascular lesions. *Br J Ophthalmol* 1978;62 (10):709-14.
8. Yamanishi Y, Ishioka S, Takeda M, Maeda H, Yamakido M. Atypical Cogan's syndrome associated with antineutrophil cytoplasmic autoantibodies. *Br J Rheumatol* 1996;35(6):601-3.
9. Allen NB, Cox CC, Cobo M, Kisslo J, Jacobs MR, McCallum RM, et al. Use of immunosuppressive agents in the treatment of severe ocular and vascular manifestations of Cogan's syndrome. *Am J Med* 1990;88(3):296-301.
10. Richardson B. Methotrexate therapy for hearing loss in Cogan's syndrome. *Arthritis Rheum* 1994;37(10):1559-61.
11. Riente L, Taglione E, Berrettini S. Efficacy of methotrexate in Cogan's syndrome. *J Rheumatol* 1996;23(10):1830-1.
12. Roat MI, Thoft RA, Thomson AW, Jain A, Fung JJ, Starzl TE. Treatment of Cogan's syndrome with FK 506: a case report. *Transplant Proc* 1991;23(6):3347.
13. Lunardi C, Bason C, Leandri M, Navone R, Lestani M, Millo E, et al. Autoantibodies to inner ear and endothelial antigens in Cogan's syndrome. *Lancet* 2002;360(9337):915-21.
14. Vollertsen RS, McDonald TJ, Younge BR, Banks PM, Stanson AW, Ilstrup DM. Cogan's syndrome: 18 cases and a review of the literature. *Mayo Clin Proc* 1986;61(5):344-61.