






Bilateral Hydronephrosis After Hypospadias Surgery

Hipospadias Cerrahisi Sonrası Gelişen Bilateral Hidronefroz

-  Cumhuri YEŞİLDAL,^a
 Furkan DURSUN,^a
 Ahmet Tevfik ALBAYRAK,^a
 Nihat TÜRKMEN,^a
 Sinan Levent KİREÇÇİ^a

^aDepartment of Urology,
Health Sciences University
Şişli Hamidiye Etfal Training and
Research Hospital,
İstanbul

Received: 29.03.2018
Received in revised form: 02.07.2018
Accepted: 03.07.2018
Available online: 14.09.2018

Correspondence:
Ahmet Tevfik ALBAYRAK
Health Sciences University
Şişli Hamidiye Etfal Training and
Research Hospital,
Department of Urology, İstanbul,
TÜRKİYE/TURKEY

ABSTRACT Hypospadias is the most common congenital penile anomaly and occurs in 1/300 live births. Surgical treatment is considered difficult as the complications, and unfavorable results are typical. New techniques have significantly decreased the complication rates. However unfavorable results are still disturbing. We report a case of hypospadias surgery complication; meatal stricture caused bilateral hydronephrosis.

Keywords: Hypospadias; hydronephrosis; stenosis

ÖZET Hipospadias en sık görülen doğuştan penil anomalisidir ve 1/300 canlı doğumda görülür. Komplikasyonlar ve elverişsiz sonuçlar yaygın olduğundan cerrahi tedavi zor kabul edilir. Her ne kadar yeni teknikler komplikasyon oranlarını önemli ölçüde azaltmış olsa da olumsuz sonuçlar hala rahatsız edicidir. Bu yazımızda hipospadias cerrahisi sonrası gelişen bir komplikasyon vakası sunduk; Meatal striktüre bağlı gelişen bilateral hidronefroz.

Anahtar Kelimeler: Hipospadias; hidronefroz; stenoz

Hypospadias is the most common congenital penile anomaly and occurs in 1/300 live births. Although many surgical technics are on the field, it still considered difficult because of the complications. However new techniques have significantly decreased the complication rates, unfavorable results are still disturbing. In this paper we present a complication of hypospadias surgery; meatal stricture caused bilateral hydronephrosis.

CASE REPORT

The patient was a 14-year-old boy. He was complaining about decreased voiding stream, painful voiding and back pain. In his history, 6 months before he had been applied subcoronal hypospadias surgery in another hospital with no complications. In the physical examination, stenosed meatus was seen (Figure 1). In an outpatient procedure, it cannot be calibrated with a 6f nelaton catheter. In the bedside ultrasonography (USG) bilateral grade I hydronephrosis was seen. His urine analysis, blood analysis, and kidney, ureter, bladder (KUB) x-ray were normal. Then we applied meatotomy (Figure 2).

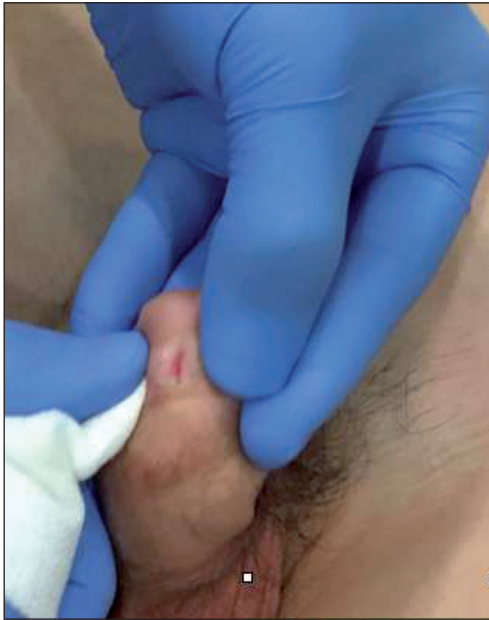

FIGURE 1: In the physical examination, stenosed meatus was seen.

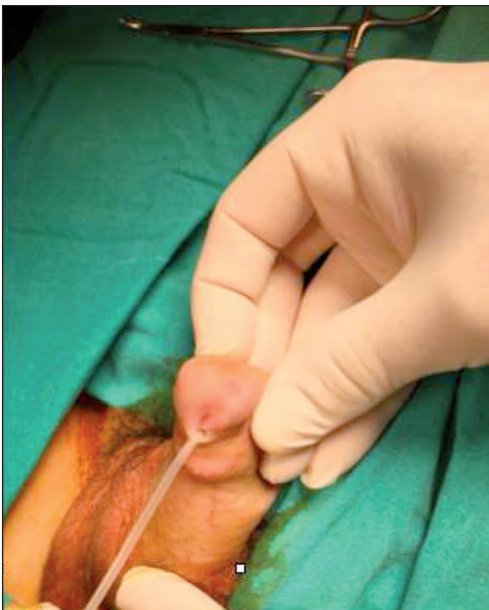

FIGURE 2: Meotomy was performed.

After the operation 14f nelaton foley catheter inserted and left for 1 week (Figure 3). One week later topical corticosteroid treatment (3 months) and urethral dilatation planned. Ten days after removing the foley catheter dilatation was started. First weekly and then every 15 days, using the smallest sounds (6f) and then larger sounds from the set were gradually introduced to a maximum of 14f.

At present, 3 months after the operation, the patient is well, and he can normally void. At his bedside, USG hydronephrosis was resolved (Figure 4).

DISCUSSION

Tubularized incised plate urethroplasty (TIPU) was described by Snodgrass in 1994. It's the method of choice for distal and mid penile hypospadias surgery¹. The advance of new techniques decreases complication rates, but they still concern surgeons. The urethrocutaneous fistula was the most common (21%) complication. It's followed by meatal stenosis (14%) and narrow neourethra (14%).² Meatal stenosis is an avoidable unfavorable complication. Generally, it occurs due to an attempt to reconstruct the urethra too distally and trying to create a cosmetically circular opening. Also, suture dehiscence can cause subsequent contraction and scar.^{3,4}

Although meatal stenosis is the second common complication of the hypospadias surgery, the management of this complication is still a dilemma.⁵ Some authors recommend surgical intervention with dorsal meotomy. Some authors recommend regular calibration/dilatation initially. Also combining corticosteroids increases scar elasticity

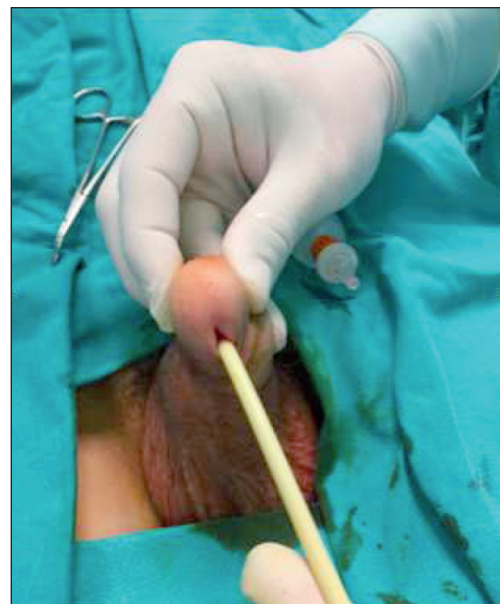


FIGURE 3: After the operation 14f nelaton foley catheter inserted and left for 1 week.

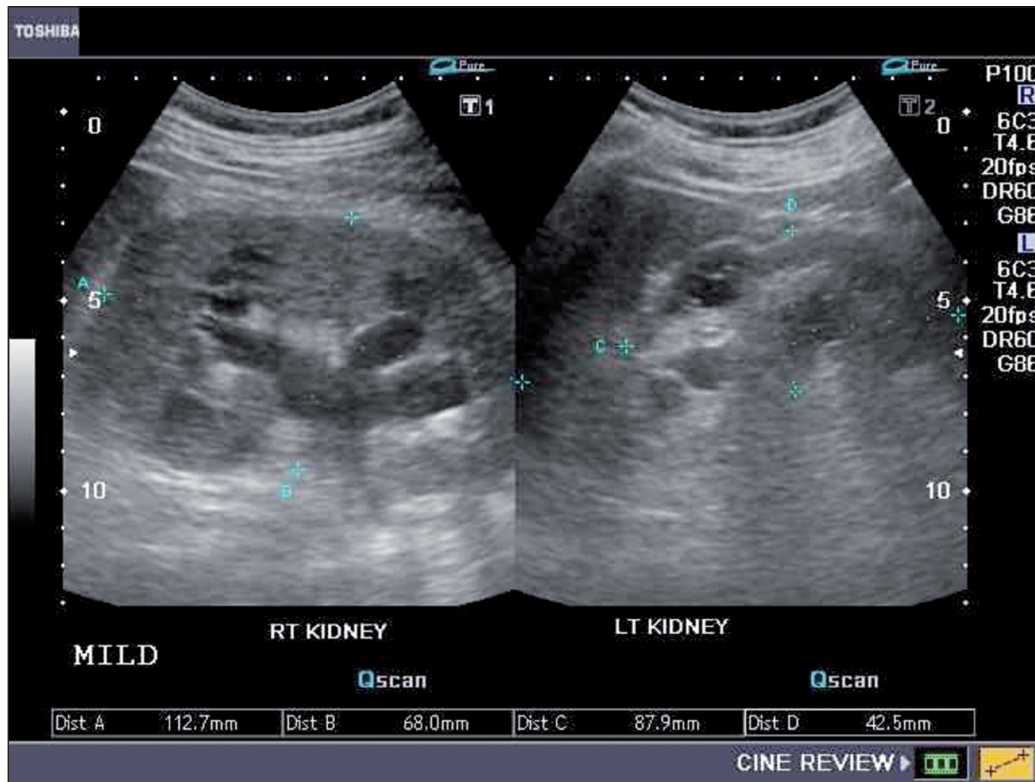


FIGURE 4: USG images of the bilateral hydronephrosis.

and facilitates dilatation.^{6,7} If the stenosis is too long, it needs to be reopened, and full thickness graft FTG may be required.^{8,9}

After hypospadias surgery, long-term follow-up is necessary to detect late complications like urethral stricture, meatal stenosis, voiding dysfunctions and recurrent penile curvatures. As in our case, meatal stenosis can cause bilateral hydronephrosis due to lower urinary tract obstruction and need of a second operation occurs. If these complications do not treat properly, they can cause irreversible and fatal problems.

In conclusion, secondary hypospadias surgery is a complex condition due to its nature, and it should be handled by an experienced pediatric urologist with great care.

Source of Finance

During this study, no financial or spiritual support was received neither from any pharmaceutical company that has a

direct connection with the research subject, nor from a company that provides or produces medical instruments and materials which may negatively affect the evaluation process of this study.

Conflict of Interest

No conflicts of interest between the authors and / or family members of the scientific and medical committee members or members of the potential conflicts of interest, counseling, expertise, working conditions, share holding and similar situations in any firm.

Authorship Contributions

Opinion/Concept: Sinan Levent Kireççi; **Design:** Cumhur Yeşildal; **Inspection / Consultancy:** Sinan Levent Kireççi, Ahmet Tevfik Albayrak; **Data Collection and/or Processing:** Furkan Dursun, Ahmet Tevfik Albayrak; **Analysis and/or Comment:** Nihat Türkmen, Cumhur Yeşildal; **Resource Screen:** Ahmet Tevfik Albayrak; **Article Writing:** Cumhur Yeşildal, Ahmet Tevfik Albayrak, Sinan Levent Kireççi; **Critical Investigation:** Ahmet Tevfik Albayrak; **Providing Resources and Funds:** Sinan Levent Kireççi.

REFERENCES

1. Snodgrass W. Tubularized, incised plate urethroplasty for distal hypospadias. *J Urol* 1994;151(2):464-5.
2. Morera AM, Valmalle AF, Asensio MJ, Chossegras L, Chauvin MA, Durand P, et al. A study of risk factors for hypospadias in the Rhône-Alpes region (France). *J Pediatric Urol* 2006;2(3):169-77.
3. Spinoit AF, Poelaert F, Groen LA, Van Laecke E, Hoebeke P. Hypospadias repair at a tertiary care center: long-term follow up is mandatory to determine the real complication rate. *J Urol* 2013;189(6):2276-81.
4. Agrawal K, Misra A. Unfavorable results in hypospadias. *Indian J Plast Surg* 2013;46(2):419-27.
5. Fredell L, Kockum I, Hansson E, Holmner S, Lundquist L, Läckgren G, et al. Heredity of hypospadias and the significance of low birth weight. *J Urol* 2002;167(3):1423-7.
6. Golubovic Z, Milanovic D, Vukadinovic V, Rakic I, Perovic S. The conservative treatment of phimosis in boys. *Br J Urol* 1996;78(5):786-8.
7. Lund L, Wai KH, Mui LM, Yeung CK. Effect of topical steroid on non-retractile prepubertal foreskin by a prospective, randomized, double-blind study. *Scand J Urol Nephrol* 2000;34(4):267-9.
8. Brannen GE. Meatal reconstruction. *J Urol* 1976;116(3):319-21.
9. Elbakry A. Tubularized-incised urethral plate urethroplasty: is regular dilatation necessary for success? *BJU Int* 1999;84(6):683-8.