

Cranial Subdural Hematoma Following Spinal Anesthesia: Case Report

Spinal Anestezi Sonrası Gelişen Kranial Subdural Hematom

Mehmet GÜL,^a
Mustafa Kürşat AYRANCI,^a
Hakan GÜNER,^a
Mohamed Refik MEDNI,^a
Başar CANDER^a

^aDepartment of Emergency,
Konya Necmettin Erbakan University
Meram Faculty of Medicine,
Konya

Geliş Tarihi/Received: 21.03.2017
Kabul Tarihi/Accepted: 20.04.2017

Yazışma Adresi/Correspondence:
Mustafa Kürşat AYRANCI
Konya Necmettin Erbakan University
Meram Faculty of Medicine,
Department of Emergency, Konya,
TURKEY/TÜRKİYE
mka_157@hotmail.com

ABSTRACT Although post dural puncture headache is the most common complication of spinal anesthesia, subdural hematoma is a rare complication. The mortality would be high if untreated. In this case, a patient of 28 years old presented to our emergency department with headache after cesarean section performed with spinal anesthesia 20 days prior. She had received analgesic drug treatment for post dural puncture headache. Despite treatment, she presented to our emergency department for unresolved headache. A subdural hematoma was detected using a brain computed tomography (CT) because of complaint of double vision accompanied by headache. For headache occurring after spinal anesthesia without response to medical therapy, subdural hematoma should be considered.

Keywords: Anesthesia, spinal; post-dural puncture headache; hematoma, subdural

ÖZET Post dural ponksiyon başağrısı spinal anestezinin en sık komplikasyonu olmasına karşın subdural hematom nadir görülen bir komplikasyondur. Tedavi edilmediği takdirde mortalitesi oldukça yüksek seyredebilir. Bu yazıda 20 gün önce spinal anestezi ile sezaryen ameliyatı yapıldıktan sonra başağrısı şikayeti ile acil servisimize başvuran 28 yaşında bir olgu sunuldu. Post dural başağrısı için analjezik ilaç almıştı. Hasta almış olduğu analjezik ilaç tedavisine rağmen dinmeyen başağrısı şikayeti ile acil servisimize başvurdu. Başağrısına çift görme şikayetinin eklenmesi nedeniyle yapılan beyin bilgisayarlı tomografi görüntülemesinde subdural hematom tespit edildi. Spinal anestezi sonrası ortaya çıkan başağrısında tıbbi tedaviye cevaba bakmaksızın bu hastalarda mutlaka subdural hematom akıldaki tutulmalıdır.

Anahtar Kelimeler: Spinal anestezi; post dural ponksiyon başağrısı; hematom, subdural

Post dural puncture headache (PDPH) is a frequent complication of spinal anesthesia. Conservative treatment may generally be ineffective. Headache developing after dural puncture may be due to many clinical conditions including pregnancy-related hypertension, meningitis, and sinus venous thrombosis. Subdural hematoma (SDH) after spinal anesthesia is rare but can potentially be life-threatening. Symptoms include sudden and localized headache, altered consciousness, sensorimotor deficits, diplopia, personality change and aphasia.¹ This paper presents a case of a patient suspected of a PDPH who continued experiencing symptoms after medical treatment with oral analgesic medication, and was later diagnosed with SDH.

CASE REPORT

A 28-year-old female patient underwent a cesarean section with spinal anesthesia 20 days prior to presentation. Twenty days after her discharge from the gynecology service, the patient presented to the emergency department with complaints of persistent headache. The evaluation in the emergency department revealed that she was experiencing persistent headache and three days of diplopia. Although her pain was occasionally relieved with rest, fluid intake and use of analgesics, there was no complete resolution. She had no history of a known disease or medication use. In the single shot spinal anesthesia performed in another medical centre, a 25 G Quincke-tipped needle was used via L3-L4 level. There was no complication during and after the spinal anesthesia. There was no report of head trauma, use of acetylsalicylic acid or any anticoagulants in the 20 day period since the spinal anesthesia. The physical examination revealed a well-appearing, conscious and cooperative female. Her neurological examination revealed diplopia with no evidence of meningeal irritation. Laboratory findings (complete blood count, glucose, sodium, potassium, blood urea nitrogen, creatinine, C-reactive protein), Chest Radiograph and Electrocardiogram were normal. Headache was localized in the left parietal area. Uncontrasted brain CT was obtained because of new neurological findings. An emergency Cranial Computerized Tomography (CCT) scan revealed subdural hematoma in the left frontoparietal region with midline shift (Figure 1). Neurosurgery service was consulted and the patient underwent emergency burr-hole opening on the left parietal side. The vital signs recorded shortly before the operation showed a blood pressure of 110/65 mmHg and a pulse rate of 100/min. There was no significant hemodynamic change during the operation. An CCT scan conducted after the operation revealed regression of the hematoma and midline shift (Figure 2). On post-operative day 10, the patient had no neurological deficit, and was discharged with clinical recovery.

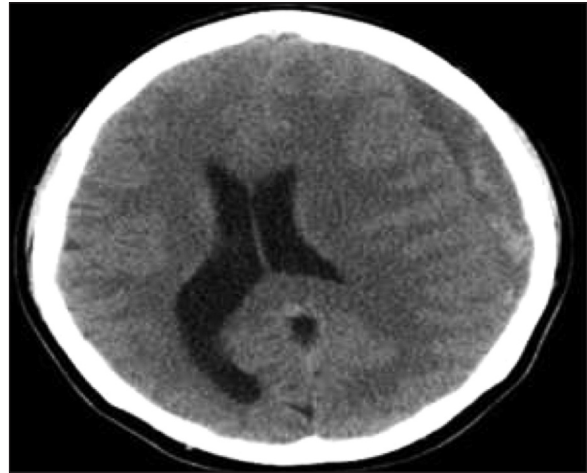


FIGURE 1: CCT scan showing subdural hematoma in the left frontoparietal region.

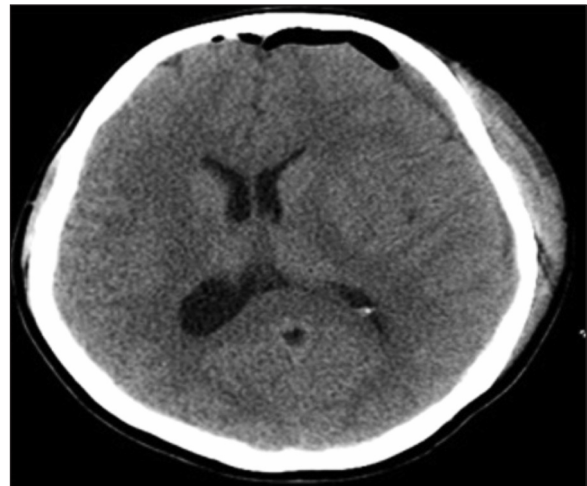


FIGURE 2: CCT scan showing regression of bleeding and shift on CT scan on post-operative day 1. The air seen in the radiograph is secondary to the craniotomy.

DISCUSSION

The complications of spinal anesthesia include headache, hypotension, low back pain, infective complications, and intracranial hemorrhage.² Any dural damage after intervention may cause headache. PDPH usually resolves within a couple of days using oral analgesic therapy, oral or intravenous fluid hydration along with bed rest.

PDPH frequently occurs at frontal and occipital sites, with a possible radiation to shoulders. It is aggravated by the upright position and sudden

movement, but is usually alleviated with bed rest. Nausea, vomiting, depressive mood and anorexia may accompany pain. It is more common among young women.³

Initially, PDPH was considered to be the most likely cause of the patients headache in this case as there were no neurological signs and the pain responded intermittently to treatment. However, upon obtaining further history and progression of symptoms and findings of diplopia on neurological examination led to a broader differential diagnosis and further testing uncovered an intracranial hemorrhage.

SDH after spinal anesthesia is a rare anesthetic complication which may be accompanied by headache and neurological findings. Any prolonged or unresolved headache due to dural irritation, alteration in pain profile, and development of new neurological findings may all indicate SDH or other intracranial hemorrhage.^{4,5} Dural damage and leakage of cerebrospinal fluid may also arise along with intracranial SDH after rupture of veins between cortical and dural sinuses based on stress.⁶

CT or MRI can be used for diagnosis. Small SDH in the late subacute phase may be missed as it is likely to be observed as isodense areas in CT. In such cases, MRI may yield the definite diagnosis.

Diagnosis could be made in our case during the subacute phase, followed by discharge after recovery. Therefore, intracranial hemorrhage, with its high mortality rates, should be considered in any patient with prolonged and unresolved headache after spinal anesthesia despite medical therapy. Patients with PDPH after spinal anesthesia should be monitored for neurologic signs and symptoms that could herald SDH.

Conflict of Interest

Authors declared no conflict of interest or financial support.

Authorship Contributions

Concept: Mehmet Gül; **Design:** Mustafa Kürşat Ayrancı; **Supervision:** Başar Cander; **Data Collection and/or Processing:** Hakan Güner; **Analysis and/or Interpretation:** Mohamed Refik Medni; **Writing:** Mustafa Kürşat Ayrancı; **Critical Review:** Başar Cander; **Revision of the Manuscript:** Hakan Güner, Mohamed Refik Medni.

REFERENCES

1. Wind JJ, Leiphart JW. Bilateral subacute subdural hematomas. *N Engl J Med* 2009;360(17):e23.
2. Dogru S, Kaya Z, Yılmaz Dogru H. Complications of spinal anaesthesia. *J Contemp Med* 2012;2(2):127-34.
3. Ozdemir O, Calisaneller T, Yildirim E, Altınors N. Acute intracranial subdural hematoma after epidural steroid injection: a case report. *J Manipulative Physiol Ther* 2007;30(7):536-8.
4. Lai TH, Fuh JL, Lirng JF, Tsai PH, Wang SJ. Subdural haematoma in patients with spontaneous intracranial hypotension. *Cephalalgia* 2007;27(2):133-8.
5. Xu R, Bydon M, Gokaslan ZL, Wolinsk, JP, Witham TF, Bydon A. Epidural steroid injection resulting in epidural hematoma in a patient despite strict adherence to anticoagulation guidelines: case report. *J Neurosurg Spine* 2009;11(3):358-64.
6. Park IB, Moon SY, Kim YY, Kwon YE, Lee JH. Acute-on-chronic subdural hematoma by spinal anesthesia in a patient with undiagnosed chronic subdural hematoma-A case report. *Korean J Anesthesiol* 2011;61(1):75-8.