

Prosthodontic Rehabilitation with Conventional Partial Dentures for Mandibulectomy Patient: A Case Report

MANDİBULEKTOMİ GEÇİRMİŞ HASTANIN GELENEKSEL BÖLÜMLÜ PROTEZLERLE REHABİLİTASYONU

Ediz KALE, MD,^a Remzi NİĞİZ, Dt^a

^aDepartment of Prosthodontics, Dicle University Faculty of Dentistry, DİYARBAKIR

Abstract

Objective: Denture fabrication for mandibulectomy patients is a challenging issue. Especially, when patients cannot afford preprosthetic reconstructive surgery or fabrication of implant-assisted overdentures, which may improve denture retention and stability, prosthetic management becomes extremely difficult. Properly fabricated conventional dentures may provide comfort and sufficient function in these patients.

Case Report: This report describes the prosthetic treatment of a young man with a mandibular defect occurred as a result of a gunshot accident. It also discusses some issues about impression making of resilient oral structure involved in the prosthetic management of tooth-tissue-supported removable partial dentures and presents patient's therapy compliance up to 6 months after the treatment.

Key Words: At the end of the treatment, properly designed and constructed removable partial denture, showed to be a satisfactory therapeutic alternative for segmental mandibulectomy patients.

Key Words: Acquired jaw defect, removable partial denture, mandibulectomy, functional impression

Türkiye Klinikleri J Dental Sci 2006, 12:62-67

Özet

Amaç: Mandibulektomi geçirmiş hastaların protetik tedavileri zordur. Hastaların preprotetik rekonstrüktif cerrahi ve protezlere destek olabilecek implant uygulamaları gibi işlemleri karşılayacak durumları olmadığında, protetik rehabilitasyon daha da güçleşmektedir. Düzgün yapılmış geleneksel protezler, bu tür hastalarda yeterli bir fonksiyon sağlayabilir ve hastanın rahat etmesine katkıda bulunabilirler.

Olgu Sunumu: Bu olgu raporunda, kaza eseri ateşli silah yaralanmasına maruz kalmış ve mandibula defekti edinmiş genç bir erkek hastanın protetik rehabilitasyonu anlatılmakta, diş-mukoza destekli hareketli bölümlü protez yapımında yumuşak doku reziliensine bağlı olarak seçilecek ölçü yöntemi tartışılmakta ve hastanın 6 aya kadar olan tedaviye uyumu sunulmaktadır.

Sonuç: Tedavinin sonunda, mandibulektomi geçirmiş hastaların düzgün planlanmış ve yapılmış geleneksel protezlerle de yeterli bir rehabilitasyona kavuşabilecekleri ortaya konmuştur.

Anahtar Kelimeler: Edinilmiş çene defekti, hareketli bölümlü protez, mandibulektomi, fonksiyonel ölçü

Acquired jaw defects may be pathologic, traumatic, or developmental in origin. Defects as a result of trauma to the

face, may damage cranial nerves, muscles, bones, and blood vessels and may be life-threatening. Patients experienced trauma may become disfigured and handicapped. Prosthetic therapy may be needed to restore anatomy, function and esthetics.¹

Ideally, any anatomic defect should be surgically constructed.¹ Reconstructive plastic surgery may provide a suitable tissue foundation for an acceptable mandibular denture.² Attaining of implant-assisted overdentures may improve den-

Geliş Tarihi/Received: 24.06.2005 Kabul Tarihi/Accepted: 08.02.2006

This report took place as a poster presentation at The I International Dental Symposium of Süleyman Demirel University Dental Faculty held on 28-30 May 2004 in Isparta.

Yazışma Adresi/Correspondence: Ediz KALE, MD
Dicle University Faculty of Dentistry,
Department of Prosthodontics, DİYARBAKIR
dtedizkale@yahoo.com

Copyright © 2006 by Türkiye Klinikleri

ture retention and stability. However, some patients cannot afford this treatment and prosthetic rehabilitation becomes a challenge for clinicians.

Prognosis for edentulous segmental mandibulectomy patients is well described in the literature.³⁻⁶ Existence of remaining teeth may be favorable for such patients, if conventional removable denture is to be fabricated. However, the construction of mandibular removable partial dentures (RPDs) with dual nature of support presents a unique problem in attaining maximum stability.⁷

This article describes the fabrication of conventional RPDs and other prosthodontic management for a left segmental mandibulectomy patient.

Case Report

A 29-year-old man was referred to the Dicle University Faculty of Dentistry, Diyarbakır, Turkey for prosthodontic assessment of a mandibular defect. The defect had occurred 10 years earlier, consequently an accidental gunshot from behind the right angle of the mandibula and extended from retromolar region to the symphysis. Right after the accident, with an interval of a few months the patient had undergone three surgical procedures in a cooperation of a maxillofacial surgeon and an otolaryngologist. First two had been performed in Dicle University Hospital and the third in Ankara University Department of Maxillofacial Surgery, Ankara, Turkey. No further rehabilitation had been able to be performed because of the patient's non-responding to the appointments scheduled.

Clinical and radiographic examination of the patient revealed partial edentulism and some teeth with root fractures (Figure 1). Severely altered right alveolar ridge line was at the mouth floor level but the tongue volume and mobility were not handicapped. There was obvious limitation in oral opening and reduced tissue flexibil-

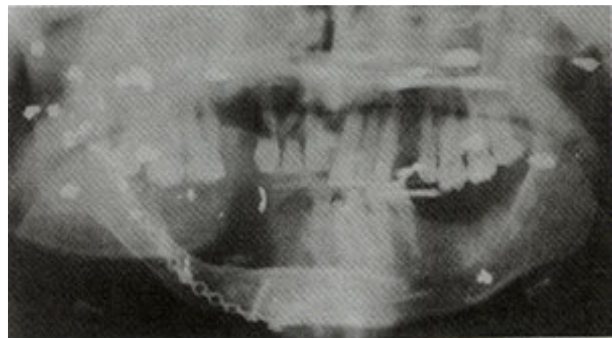


Figure 1. Panoramic view shows right mandibular defect reconstructed with metal plate, and remaining pellets in soft and hard tissue. Maxillary right incisors and canine had to be extracted because were fractured. Mandibular left second incisor had insufficient bone support and second premolar had a periapical lesion and mobility because of periodontal disease. These teeth had to be extracted, too.

ity. The lip closure was also severely impaired, thus the mouth always remained open (Figure 2). The patient had an impaired speech, too, but his chief complaint was that he could not eat solid food and had negatively affected facial appearance.

Fabrication of conventional fixed and removable partial prostheses with functional impression procedures was planned after the routine preprosthetic preparations were completed. No additional surgery to improve the oral opening and lip closure or to obtain proper stability and retention for the prostheses was planned because these kinds of procedures were unaffordable by the patient.

After the extraction of fractured teeth and those with insufficient alveolar bone support and the periodontal treatment, left mandibular canine and first premolar were splint-restored with porcelain-fused-to-metal fixed prostheses using routine clinical and laboratory procedures. Because of the antero-medial position of these teeth regarding maxillary dental arch the canine was given a form of a second incisor and the premolar a canine form (Figure 3). Fixed partial denture was fabricated for the maxillary left ca-

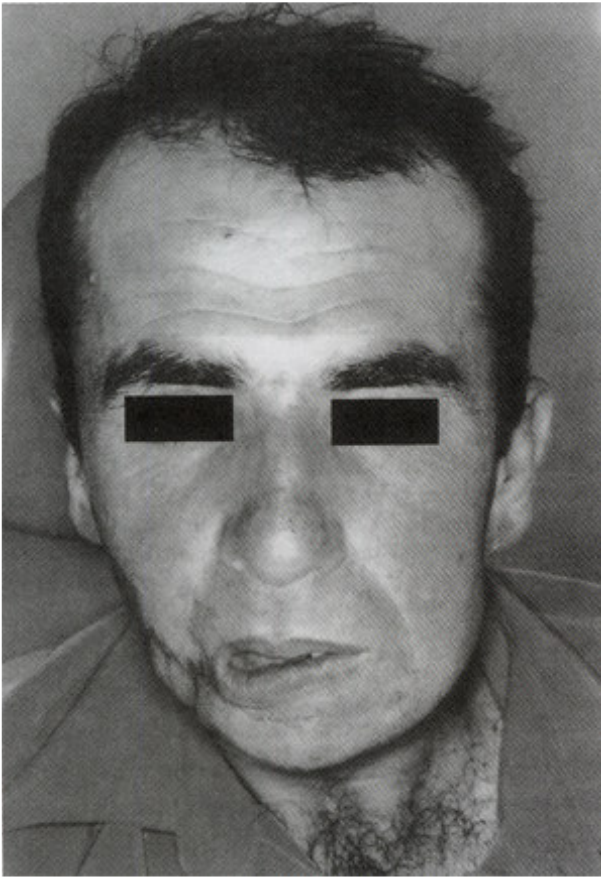


Figure 2. Frontal view of the patient and defect, extraorally. Lip seal is severely impaired and tongue can be easily seen through the gap between the lips. Note the scar on the right and deviation of the mandibula.

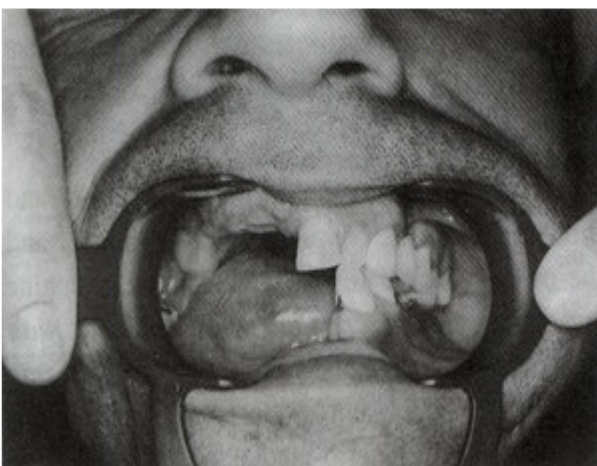


Figure 3. Intraoral frontal view of the patient after restoration with fixed prostheses. Note loss of alveolar ridge on the right side of the mandibula and maxilla.

nine, first and second premolar, too. Sufficient time period was supplied for bone and soft tissue healing before preliminary impressions were made. Type II hydrocolloid impression material (Cavex CA37; Cavex Holland BV, Haarlem, Holland) and stock trays were used for the maxillary and mandibular preliminary impressions. No difficulties were experienced with the impression procedures of the maxilla but the defect region at the mandibula had to be captured in a functional position since the mucosa was highly resilient and easily affected by the movements of the tongue and cheek. Casts were poured with the preliminary impressions and custom trays were fabricated using autopolymerizing acrylic resin (Imicryl S.C.; Imicryl Dental Materials Inc., Konya, Turkey). The maxillary final impression was made in conventional manner but the final impression of the mandibula was performed in correlation with the functional impression technique proposed by Rapuano⁸, thus the custom tray used had a special design (Figure 4). After border molding of the special tray using modeling plastic compound (Green Compound Sticks; Kerr Italia S.p.A., Salerno, Italy), functional final impression of the edentulous parts of the mandibula was made using eugenol free zinc oxide impression material (Cavex Outline Impression Paste; Cavex Holland BV, Haarlem, Holland). Once the impression

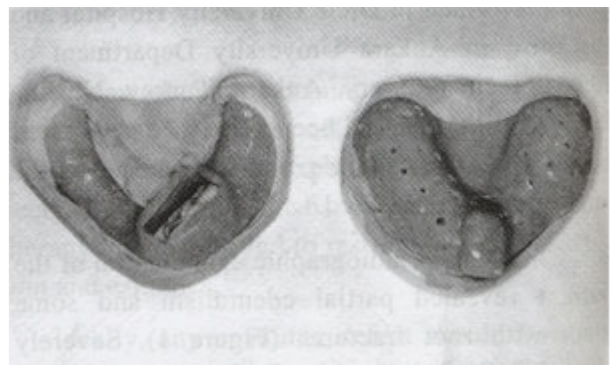


Figure 4. View of custom trays used for the final impressions. Note the design of the mandibular tray at the part surrounding teeth.

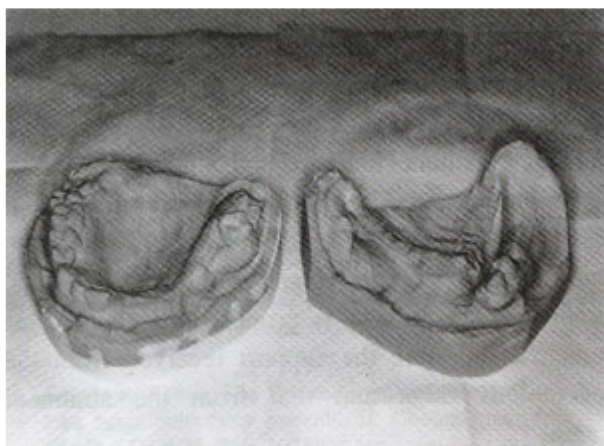


Figure 5. Working casts made of dental stone. Note altered alveolar ridge contour on the right of the mandibula.

material was muscle trimmed and set, the tray was carefully removed to visually inspect for accuracy. Excessive tissue coverage and bulk were trimmed back using a scalpel and the tray was inserted back into the mouth in order to complete the full arch impression. As the custom tray was held in place under slight finger pressure, the anatomic impression of the teeth and the adjacent gingival region was made injecting light bodied polysiloxane impression material (Lastic Xtra; Kettenbach Dental, Eschenburg, Germany) into the acrylic box of the tray. Boxing method was applied to the mandibular impression and working casts were poured in hard dental stone (Giludur Synthetic Dental Stone; BK Giulini Chemie GmbH&Co., Ludwigshafen, Germany) (Figure 5). Using artificial teeth narrow in bucco-lingual dimension and arranging shortened dental arch excluding the second molar tooth at the defect region was the planned design for the mandibular removable denture (Figure 6). The maxillary and mandibular dentures were fabricated using conventional clinical and laboratory procedures.

At the insertion appointment the patient was instructed in the insertion and removal of the prostheses. Oral hygiene instruction was reinforced and routine follow-up appointments

were scheduled. At the 1-week-follow-up appointment the patient stated to feel pain on the right retromolar region of the mandibula during mastication. Clinical examination revealed excess pressure right on the soft tissue over the metal plate used for the reconstruction of the defect region. Trimming and polishing was performed at the questionable part of the denture. At the 1-month-follow-up appointment, the patient was pleased with his facial appearance but still had problems with managing the function of the mandibular denture (Figures 7 and 8). At the 6-month-follow-up, he revealed

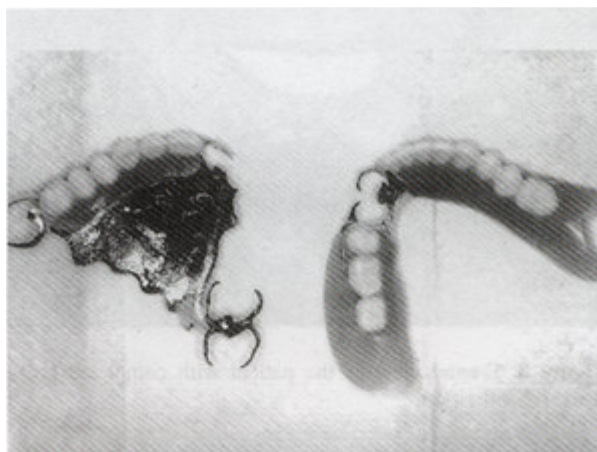


Figure 6. Occlusal view of completed removable partial dentures.

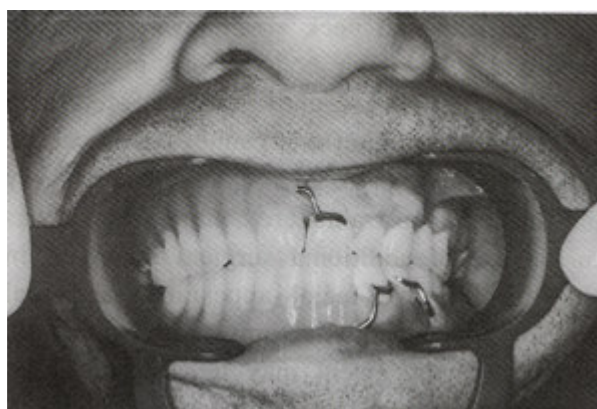


Figure 7. Intraoral frontal view of fixed and removable partial dentures in situ.

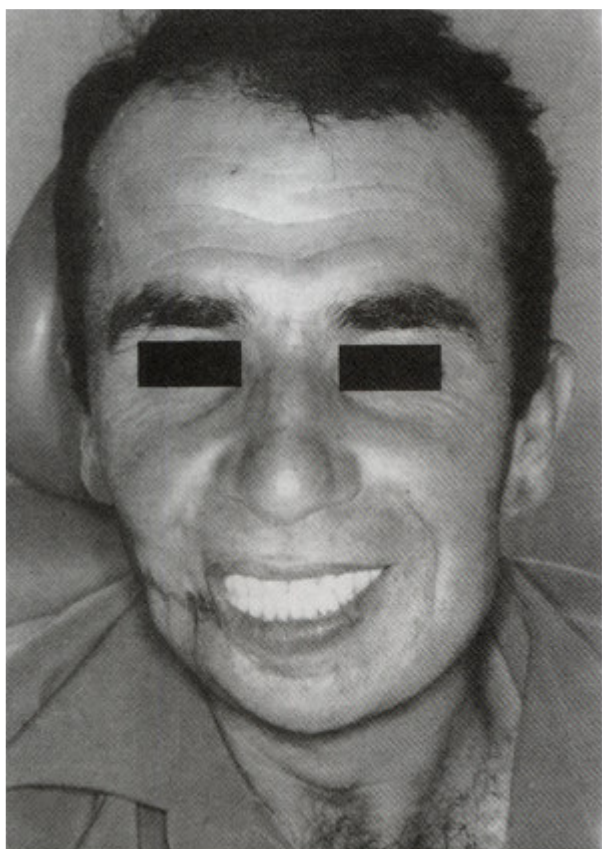


Figure 8. Frontal view of the patient with completed prosthetic rehabilitation.

chewing the food just on the left side but feeling comfortable and pleased.

Discussion

The head and neck area plays a critically important role in our body image, much more than we can expect until it is defaced with therapeutic mutilation that cannot be concealed. However, previous history of undergone surgery and financial constraints are common limitations on the use of additional surgical therapies, in order to improve facial appearance and oral function of mandibulectomy patients. Only, prosthetic management may be acceptable for the patients in some situations.

A widely accepted axiom of removable partial prosthodontics is that the prostheses should be

designed and constructed to preserve the oral structures as well as to restore function. In patients with tooth-tissue-supported RPDs, support is derived from combination of relatively rigid teeth and of resilient mucosa and underlying bone, which are covered by the free-end denture base. If the partial denture is made incorrectly, the teeth will loosen, and the ridges will resorb. A dual impression technique is proposed to equalize as much as possible the support received from the edentulous ridge and that from the abutment teeth.^{7,8}

The functional impression technique used for partially edentulous distal-extension mandibulectomy patient in this report, is a single-tray dual-impression technique, performed under slight finger pressure. Although, the results of functional impression techniques made under closing pressure are mentioned to be more satisfactory⁷, the impression was not made under closing pressure, because the underlying mucosa at the defect region was highly resilient, thus it was difficult to obtain a proper vertical position for the custom tray. Besides, it was doubtful that the patient could regulate the biting force of his masticatory muscles. Border molding helped to establish optimal extension of the denture base and peripheral seal while preventing functional interference with the oral musculature. Proper border extension of the denture and correct denture polishing surface contours were important for denture stability (Figure 6). The patient felt confident right after the insertion appointment and was pleased with his facial appearance. Time was needed to properly function with his mandibular denture. The patient deliberately chose not to chew on the resected side in order to avoid denture instability, which is in accordance with the treatment of previously reported segmental mandibulectomy patient.⁹ Properly designed and constructed RPDs, showed to be a satisfactory therapeutic alternative for segmental mandibulectomy patients.

REFERENCES

1. Adisman IK: Prosthesis serviceability for acquired jaw defects. *Dent Clin North Am* 34: 265, 1990
2. Martin JW, Lemon JC, King GE: Maxillofacial restoration after tumor ablation. *Clin Plast Surg* 21: 87, 1994
3. Academy of Prosthodontics: Principles, concepts, and practices in prosthodontics-1994. *J Prosthet Dent* 73: 73, 1995
4. Desjardins RP: Occlusal considerations for the partial mandibulectomy patient. *J Prosthet Dent* 41: 308, 1979
5. Cantor R, Curtis TA: Prosthetic management of edentulous mandibulectomy patients. II. Clinical procedures. *J Prosthet Dent* 25: 546, 1971
6. Cantor R, Curtis TA: Prosthetic management of edentulous mandibulectomy patient. I. Anatomic, physiologic, and psychologic considerations. *J Prosthet Dent* 25: 446, 1971
7. Ulusoy M, Can G, Aydın AK, Türköz Y, Akgök V: Relationship between various functional impression techniques and different operators. *J Marmara Univ Dent Fac* 2: 540, 1996
8. Rapuano JA: Single-tray dual-impression technique for distal extension partial dentures. *J Prosthet Dent* 24: 41, 1970
9. Mou SH, Chai T, Shiau YY, Wang JS: Fabrication of conventional complete dentures for a left segmental mandibulectomy patient: A clinical report. *J Prosthet Dent* 86: 582, 2001