

Intraocular Telescope Surgery in Patients with Age Related Macular Degeneration and Cataract

Katarakt ve Yaşa Bağlı Makula Dejeneresansı Birlikteliğinde İntraoküler Teleskop Cerrahisi

Murat ERBEZCİ,^a
Eser PAŞA^b

^aPrivate Practitioner, İzmir

^bAdagöz Eye Medical Center, Aydın

Geliş Tarihi/Received: 22.05.2016

Kabul Tarihi/Accepted: 28.09.2016

Yazışma Adresi/Correspondence:

Murat ERBEZCİ

Private Practitioner, İzmir,

TURKEY/TÜRKİYE

murat@muraterbezci.com

ABSTRACT Objective: Cataract and Age-related Macular Degeneration (ARMD) often coexist in elderly patients. The loss in functional vision has a serious impact in their quality of life. The purpose of this article is to share the results of the intraocular telescope surgery (Lenspecial, Soleko, Italy) on eight patients' 10 eyes. **Material and Methods:** 8 patients with cataract and ARMD were enrolled for IOL-Vip Revolution surgery, using special software and the simulator designed for this procedure. The Preferred Retinal Locus (PRL) of all cases was localized by a Scanning Laser Ophthalmoscope (SLO). Two weeks of computerised PRL rehabilitation was carried out before the operation. Then, the phacoemulsification surgery with implantation of IOL-Vip Revolution intraocular telescopes was realized for a total of 10 eyes in 8 patients. The PRL rehabilitation programme was repeated for 4 weeks following the operation. Visual Function Questionnaire-25 (VFQ-25) tests were given to the patients. Five of the patients returned the questionnaire at the 1-month post-op visit. **Results:** Intraocular telescopic IOL implantation and phacoemulsification surgeries realized for 10 eyes of 8 patients-5 male and 3 female. The average age of the patients was 81.3 ± 5.15 years. The visual acuities and VFQ-25 scores of patients were tested before and 1 month after surgery. The mean pre-operative visual acuity was 1.35 logMAR units and the mean pre-operative VFQ-25 score was 36.92/100 points. The post-operative scores were 0.86 logMAR units and 57.78/100 points respectively. **Conclusion:** The IOL-Vip Revolution implantation and the accompanying computerised vision rehabilitation system improved the vision and were well tolerated in the observed patients. In the cases of cataract and ARMD, the implantation of an intraocular telescopic IOL should be considered as a viable option. However, more comprehensive, prospective studies with larger number of patients need to be conducted on this subject.

Keywords: Macular degeneration; cataract; telescopes; lens implantation, intraocular

ÖZET Amaç: Katarakt ve Yaşa Bağlı Makula Dejeneresansı (YBMD) birlikteliğine ileri yaşlarda sıklıkla rastlanır. Hastaların fonksiyonel görmelerinde oluşan kayıp, yaşam kalitesini önemli ölçüde azaltmaktadır. Bu makalenin amacı 8 hastanın 10 gözünde gerçekleştirilen IOL Vip Revolution intraoküler teleskop (Lenspecial, Soleko, Italy) cerrahisi sonuçlarını paylaşmaktır. **Gereç ve Yöntemler:** Bu yöntemin uygulanabilmesi için tasarlanan özel yazılım ve simülatör ile katarakt ve YBMD birlikteliği gösteren 8 olgu cerrahi için uygun olarak seçilmiştir. Bu olgularda Lazer Oftalmoskop (Scanning Laser Ophthalmoscope;SLO) ile Tercihli Retina Alanı (TERA) tespiti yapılmıştır. Daha sonra, operasyondan önce 2 hafta süre ile TERA rehabilitasyonu gerçekleştirilmiştir. Sekiz hastanın 10 gözüne fakoemülsiyon yöntemi ile katarakt cerrahisi ve intraoküler teleskopik mercek (İOL-Vip Revolution) implantasyonu, cerrahiden sonra 4 hafta süreyle de yeniden TERA rehabilitasyonu uygulanmıştır. Hastalara Görsel Fonksiyon Anketi-25 (GFA-25) testi verilmiş pre-op ve post-op 1. ayda doldurup, geri getirmeleri istenmiştir. Sadece 5 hasta post-op 1. ayda anketi doldurup getirmiştir. **Bulgular:** 5 erkek, 3 kadın toplam 8 hastanın 10 gözüne fakoemülsifikasyon yöntemi ile katarakt cerrahisi ve intraoküler teleskopik göz içi lensi implantasyonu uygulanmıştır. Hastaların ortalama yaşı 81.3 ± 5.15 yıldır. Hastaların operasyon öncesinde ve 1 ay sonraki kontrollerinde görme keskinliği değerleri ve GFA-25 testi sonuçları saptanmıştır. Ameliyat öncesi hastaların ortalama görme keskinliği 1.35 logMAR ünitesi, GFA-25 skorları ise 36.92/100 puan olarak belirlenmiştir. Cerrahi sonrası 1.ayda ise sırasıyla 0.86 logMAR ünitesi ve 57.78/100 puan olarak gözlenmiştir. **Sonuç:** IOL-Vip intraoküler teleskop cerrahisi ve birlikte uygulanan rehabilitasyon sistemi olguların tümünde görme keskinliklerinde artmaya neden olmuş ve iyi tolere edilmiştir. İntraoküler teleskop cerrahisi katarakt ve YBMD birlikteliğinde bir seçenek olarak dikkate alınmalıdır. Bu konuda, daha geniş seriler içeren kontrollü ve prospektif çalışmalara gereksinim vardır.

In the United States, Age-Related Macular Degeneration (ARMD) is observed among 1.47% of persons above the age of 40; this ratio further increases to approximately 30% among persons above the age of 75 years.¹ ARMD and cataract -which is also frequently observed among persons of these age groups- represent the two most common eye pathologies that result in visual impairment.^{2,3}

Macular scar that develops in advanced-stage ARMD cases leads to the formation of a central scotoma, which in turn results in considerable visual impairment that significantly affects the daily life of patients. Due to their loss of vision, patients become unable to perform many basic activities such as reading, watching television, and recognizing the faces of others. As a result of their visual impairment, advanced-stage ARMD patients become more and more dependent on other persons for performing their daily tasks, while also experiencing a higher incidence of accidents and depression.⁴⁻⁶

Following the formation of the macular scar, further medical treatment is not recommended for these patients.

In these cases, the aim of vision rehabilitation is to assist the formation of a more stable preferred retinal locus (PRL) with better localization and functions (such as initiating saccades), such that the patients would be able to regain a good functional vision.⁷ Another low vision aid tool is the optic/electronic magnifier, such as telescopes. They have many known disadvantages, including the significant reduction of the patient's visual field.^{8,9}

One of the options that have been developed to overcome the difficulties associated with the use of telescopes mounted on glasses or used in hand is the implantation of these telescopes inside the eye. A number of different implants have been developed to this end. The most important advantages of intraocular telescopes over head-mounted and electronic telescope systems include better control of scanning eye movements within the visual field, better head movements and vestibular effects, and a better sense of monocular depth.¹⁰

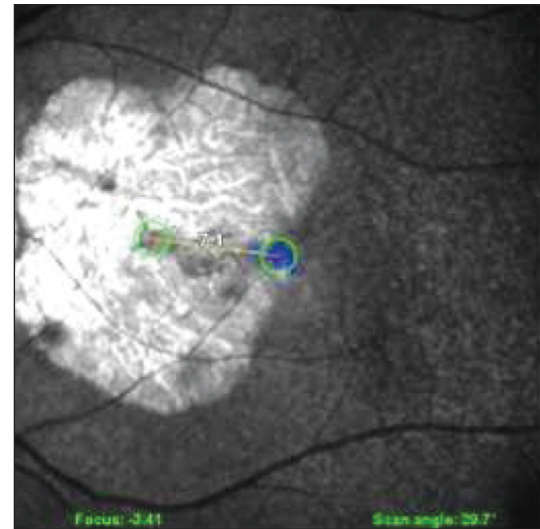


FIGURE 1: Localization of the preferred retinal locus.

The purpose of this article is to share the effect of the intraocular telescope surgery (IOL Vip Revolution, Lenspecial, Soleko, Italy) on eight patients' visual acuities and Visual Function Questionnaire-25 (VFQ-25) scores.

MATERIAL AND METHODS

In our study, cases with coexisting cataract and ARMD were first evaluated using a specially-designed SAVA Plus software (Lenspecial, Italy). The best-corrected residual visual acuity of the cases was determined using the optotype of the software, and the positions of the PRLs were then identified using a Scanning Laser Ophthalmoscope (SLO-OCT, Optos) (Figure 1).

After assessing the distance of the PRL to the macula, the potential visual acuity was estimated based on the Fonda scheme for the eccentricity of fixation. Functional vision was then evaluated using the IOL VIP prismatic intraocular telescope simulator. We were thus able to simulate the magnification and prismatic effect that would be obtained following implantation. A case was considered as being suitable for implantation in case the simulation indicated a minimum two-fold increase in visual acuity. Surgery was planned for dry type ARMD patients, and also for wet type ARMD patients who had completed their treatment.

All cases took part in a six-week computer-based PRL rehabilitation, beginning two weeks before the surgery, and ending in the fourth postoperative week. The PRL rehabilitation was performed using NeWinFlash software (Lenspecial, Italy). In addition to stimulating and increasing the stability of the PRL, this rehabilitation program also aimed to carry/move the PRL towards a more central position that enabled better reading, so that the cases would be able to perform reading activities at increasingly higher levels of difficulty. To this end, the cases were sequentially shown increasingly longer words of gradually smaller sizes in the form of flashes. The flash method was particularly preferred to prevent the cases' eyes from performing searching movements, and to promote quick glancing.

Before the procedure, the patients were informed about the risks and possible complications about the surgery and they were asked to sign an informed consent. All operations were performed as outpatient (same-day) surgeries under local anesthesia (topical + subconjunctival). A larger capsulorhexis was initially performed compared to standard phacoemulsification surgery (recommended size 7 mm), through a small incision. Following this, routine phacoemulsification surgery procedures were applied.

The IOL VIP Revolution intraocular telescope system consists of two polymethyl methacrylate (PMMA) intraocular lenses (IOLs) and a ring - called a SAL Ring- that is placed inside the capsular bag. Two intraocular lenses, one of which is a high negative value (-46 D) biconcave intraocular lens, while the other is a high positive value (+55 D, on average) biconvex intraocular lens, are placed inside this ring, forming a Galilean telescope.

Due to the differing lengths of the biconcave lens' haptics, the two lenses are positioned in an off-centered way, creating a prismatic effect. This allows the image to be directed towards the PRL, rather than the macula. This telescopic lens system is reported to provide a 1.3-fold magnification by the manufacturer.

After the SAL Ring was placed inside the capsule, the incision was widened to 6.5 mm. The lenses were also positioned inside the capsule, with the biconcave lens being placed first. The incision was then closed using 10-0 cornea sutures. After surgery, a treatment protocol involving corticosteroid and antibiotic eye drops for a period of approximately one month was administered.

All the pre-operative and post-operative evaluations were realized by the same physician (ME), the surgeries were realized by two surgeons (ME and EP).

The exclusion criteria for the surgery were the absence of visual acuity improvement with the simulator, previous eye surgeries, glaucoma and any other known ocular pathologies. Neither did we realize the surgery on high-risk cataract patients i.e. mature cataracts, pseudo-exfoliation syndrome etc.

In addition, the cases were also administered with a Turkish translation of the VFQ-25 test before the surgery and in the postoperative first month. Only 5 patients returned the completed questionnaire at the end of 1 month. The mean preoperative test score was determined as 36.92/100 points.

RESULTS

Ten eyes of eight cases were considered to be suitable for IOL Vip intraocular telescope surgery. All patients had clinically significant cataracts. Five of these cases were male, while three were female. The mean age of patients were 81.3 years, ranging between 69 to 87. All cases had cataracts coexisting with macular atrophy or scars. The mean pre-operative visual acuity of these cases was determined as 1.35 logMAR units (range: 1.70-0.85) (Table 1).

The mean pre-operative VFQ-25 score was 36.92/100 points.

Following surgery, an increase was observed in the visual acuity of all cases. The post-operative mean best-corrected visual acuity of the cases was 0.86 logMAR units and varied between 1.30 and 0.36. This improvement was statistically significant

TABLE 1: Cases: pre and postoperative values.

No.	Name	Age, years	Sex	Eye	Pre Op		Post Op		Follow Up
					Pre Op VFQ	Post Op VFQ	Visual Acuity logMAR	Visual Acuity logMAR	
1	A.U.	87	M	RE			1.52	1.09	30 months
2	N.S.	86	F	RE	32.5	59.75	0.96	0.36	26 months
3	H.T.	69	M	RE	44.6	78.28	0.85	0.48	19 months
4	F.K.	77	M	RE			1.7	1.3	18 months
5	A.U.	87	M	LE			1.52	1.3	17 months
6	M.E.	80	M	LE	38.8	61.74	1.3	0.82	15 months
7	O.O.	79	M	LE	43.95	47.40	1.7	1.0	15 months
8	S.Ş.	80	F	LE	24.77	31.75	1.0	0.39	13 months
9	H.B.	79	F	RE			1.3	0.92	7 months
10	O.O.	79	M	RE			1.7	1.0	6 months

RE: Right eye; LE: Left eye.

($p < 0.05$) and also associated with an increase in the VFQ-25 scores. The mean VFQ-25 score in the first postoperative month was determined as 57.78 points (Table 1). This improvement of the VFQ-25 scores was not statistically significant. ($p > 0.05$)

The VFQ-25 scores were obtained after the surgery of 5 eyes of 5 different patients. For the patients who had binocular implants, we included the VFQ scores only after the first eye surgery. We did not repeat the test after the second eye surgery.

Binocular telescope surgery was applied to two of the cases. No compatibility-related problems were observed in cases receiving binocular and monocular implants. The cases were able to tolerate quite well the magnification and prismatic effect associated with the intraocular telescope system, with none of the cases reporting any subjective complaints regarding their field of vision.

DISCUSSION

All of our eight patients had bilateral cataracts and ARMD that severely affected their visual acuity and the activities of daily life. Among elderly patients, the increase in the incidence of ARMD above the age of 65 years, generally leads to a reduction of their functional vision, often coupled by cataract. This, in turn, affects negatively the patients' quality of life. The combination of these conditions also leads to the development of psychological problems in a significant portion of these patients.^{3,7}

We decided to perform a cataract surgery with an implantation of an intraocular telescope to improve the functional vision of these patients and to ameliorate their quality of life. An increasingly large number of studies have recently reported that there is no evidence supporting the view that cataract surgery causes ARMD to worsen. A systemic screening and meta-analysis published by Kessel et al. in 2015 evaluated previous publications investigating the ratio of progression, as well as conversion to the exudative type, among ARMD cases after cataract surgery.¹¹ Based on the results of their study, they declared that cataract surgery had a positive effect on the cases' functional vision, and that the surgery did not increase the risk of ARMD progression. The use of telescopic IOL instead of standard IOLs following surgery has already been previously evaluated among ARMD cases with planned cataract surgeries. We believe that this method is a good choice and an alternative for patients having difficulties in using their telescope for distance acuity.¹²⁻¹⁵

We observed an increase of best-corrected visual acuities of all patients, from the mean 1.86 logMAR units pre-operatively, to 0.86 logMAR units post-operatively ($p < 0.05$).

In the literature we can find many articles evaluating the efficacy of the intra-ocular telescope surgery with different implants. Our results are consistent with other findings that indicate an increase in the visual acuities and the quality of life of

the patients. Hudson et al. published the first year results of an implantable miniature telescope (IMT; VisionCare Ophthalmic Technologies, Saratoga, CA) in a prospective study.¹³ They have also concluded that the implantation of an intraocular telescope improves the vision and the quality of life of the patients. Singer et al., in their review article on the evaluation of the intraocular telescopic implants also concluded that these implants help to increase the quality of life in low vision patients.¹⁰

Kaşkaloğlu et al. published an article in 2001 summarizing their experiences with IMT intraocular telescopes with three cases.¹⁵ In one of these cases, an iritis that developed after surgery was resolved with topical medication, while explantation was required in another case due to bubbles forming inside the telescope. Despite these inconveniences, a certain level of improvement was noted in the cases' distance and near acuity. However, this improvement was not significant enough to have a positive impact on their quality of life.

Orzalesi et al. previously published a study on the IOL VIP, which is the preceding model of the intraocular telescope we have used in this study.¹⁶ With this model, the biconcave IOL is placed inside the capsule, while the biconvex IOL is placed in the anterior chamber. They reported positive functional results with this IOL system. The patients were also evaluated for all possible complications associated with IOLs implanted in the anterior chamber, such as endothelial damage, glaucoma, etc. Although Orzalesi et al. did not describe any significant complication associated with the IOL VIP, the more advanced IOL VIP Revolution model featuring two lenses positioned in the capsular bag was eventually developed. We have used this intra-capsular model.

In our study, the dual IOL system placed in the posterior chamber did not lead to any problems in the cases' prognosis following surgery. All of the cases demonstrated the usual postoperative prognosis observed following standard phacoemulsification surgery.

The most frequently encountered problem in cases undergoing intraocular telescope surgery is

the fairly low level of patient satisfaction due to the narrowing of the visual field as a result of magnification and the difficulties associated with binocular vision. For this reason, binocular telescopic implants are often not considered as suitable, and a lengthy training period is generally required for patients using these systems. The lower magnification of the IOL VIP system, on the other hand, does not result in a significant loss of visual field, while also enabling it to be better tolerated by patients when implanted in both eyes.^{10,16} All of our cases tolerated this system quite well, with none of the cases requiring explantation. Two of our cases reported subjective satisfaction with the binocular implantation. In addition, the patients were able to perform the rehabilitation process at home by themselves using their own computer.

The Visual Function Questionnaire (VFQ-25) score increased in all of our cases. However, this augmentation of the visual function quality score was not statistically significant ($p>0.05$). With this questionnaire, an increase of 5 points is generally considered as clinically significant.¹⁶ In four of our five cases assessed with the VFQ-25, the increase in VFQ-25 score was considerably higher than 5 points. One of the cases demonstrated an increase in VFQ-25 score of 3.45; the visual acuity of this case increased from 1.70 to 1.0 logMAR units after surgery. In assessing the effects of low vision rehabilitation and aids, these types of questionnaires evaluating functional vision are considered more meaningful and valuable than the visual acuity criterion. Reading and the reading rate can also be utilized as criteria of functional vision.^{17,18}

All cases whose preoperative simulations showed an increase in visual acuity also demonstrated an increase in their postoperative visual acuity. This improvement is certainly associated with the positive effect of cataract removal on visual acuity. For this reason, certain cases with significant opacity in their lenses experienced an increase in visual acuity that was higher than the level of increase estimated by the simulation.

As the study group is small, it is difficult to make a clear distinction between the effect of the

cataractous lens removal and the intraocular telescope itself on the visual acuity improvement. Moreover, it is likely that there is a positive effect of the rehabilitation procedure.

Larger prospective studies with control groups should be realized to evaluate the efficacy of the intraocular telescopic implants.

In all of these cases, adjustments of distance glasses and reading glasses were performed one month after the surgery. We observed that the level of magnification required for close reading had especially decreased as stated in many articles with different telescopic implants.^{10,13,16} Among cases using high-addition reading glasses, the distance from the eye necessary for effective reading had increased, enabling them to read more comfortably. In addition, the level of magnification required by cases reading with optical or electronic magnifiers had decreased. Optical adjustments/corrections were performed by taking residual refractive errors into account.

In conclusion, intraocular telescopic lenses should be considered as an important choice and

alternative for cases with coexisting cataract and ARMD. The use of telescopic IOLs instead of standard IOLs is reported to improve the functional vision and quality of life of patients. This view is supported by the lack of significant complications during the perioperative and postoperative periods of our study, as well as the increase we observed in the visual acuity and VFQ-25 scores of the cases. It is, however, necessary to bear in mind that more comprehensive studies need to be conducted on this subject.

Acknowledgment

The authors declare financial interest with Turkish distributor of the implant.

Financial Support

Authors declared no financial support.

Conflict of Interest

The authors declare financial interest with Turkish distributor of the implant.

Authorship Contributions

Author contributions equal.

REFERENCES

- Friedman DS, O'Colmain BJ, Muñoz B, Tomany SC, McCarty C, de Jong PT, et al; The Eye Diseases Prevalence Research Group. Prevalence of age-related macular degeneration in the United States. *Arch Ophthalmol* 2004;122(4):564-72.
- Klaver CC, Wolfs RC, Vingerling JR, Hofman A, de Jong PT. Age-specific prevalence and causes of blindness and visual impairment in older population: the Rotterdam Study. *Arch Ophthalmol* 1998;116(5):653-8.
- Buch H, Vinding T, La Cour M, Appleyard M, Jensen GB, Nielsen NV. Prevalence and causes of visual impairment and blindness among 9980 Scandinavian adults: the Copenhagen City Eye Study. *Ophthalmology* 2004;111(1):53-61.
- Williams RA, Brody BL, Thomas RG, Kaplan RM, Brown SI. The psychosocial impact of macular degeneration. *Arch Ophthalmol* 1998;116(4):514-20.
- Casten RJ, Rovner BW, Tasman W. Age-related macular degeneration and depression: a review of recent research. *Curr Opin Ophthalmol* 2004;15(3):181-3.
- Brown MM, Brown GC, Sharma S, Kistler J, Brown H. Utility values associated with blindness in an adult population. *Br J Ophthalmol* 2001;85(3):327-31.
- Erbezci M. [Central scotoma and reading]. *Turkiye Klinikleri J Ophthalmol-Special Topics* 2015;8(1):136-42.
- Nguyen A, Nguyen AT, Hemenger RP, Williams DR. Resolution, field of view, and retinal illuminance of miniaturized of bioptics telescopes and their clinical significance. *J Vis Rehab* 1993;7:5-9.
- Bailey IL. Critical view of an ocular telephoto system. *CLAO J* 1987;13(4):217-21.
- Singer MA, Amir N, Herro A, Porbandarwalla SS, Pollard J. Improving quality of life in patients with end-stage age-related macular degeneration: focus on miniature ocular implants. *Clin Ophthalmol* 2012;6:33-9.
- Kessel L, Erngaard D, Flesner P, Andresen J, Tendal B, Hjortdal J. Cataract surgery and age-related macular degeneration. An evidence-based update. *Acta Ophthalmol* 2015; 93(7):593-600.
- Mayer A. Clinical experience with the Ben-Sira teledioptric system for use in age-related macular degeneration. *Ger J Ophthalmol* 1996; 5(4):229-32.
- Hudson HL, Lane SS, Heier JS, Stulting RD, Singerman L, Lichter PR, et al. Implantable miniature telescope for the treatment of visual acuity loss due to end-stage age-related macular degeneration: 1-year results. *Ophthalmology* 2006;113(11):1987-2001.
- Lane SS, Kuppermann BD, Fine IH, Hamill MB, Gordon JF, Chuck RS, et al. A prospective multicenter clinical trial to evaluate the safety and effectiveness of the implantable miniature telescope. *Am J Ophthalmol* 2004;137(6):993-1001.

15. Kaşkaloğlu M, Uretmen O, Yağcı A. Medium-term results of implantable miniaturized telescopes in eyes with age-related macular degeneration. *J Cataract Refract Surg* 2001;27(11):1751-5.
16. Orzalesi N, Pierrottet CO, Zenoni S, Savaresi C. The IOL-Vip System: a double intraocular lens implant for visual rehabilitation of patients with macular disease. *Ophthalmology* 2007; 114(5):860-5.
17. Mangione CM, Lee PP, Gutierrez PR, Spritzer K, Berry S, Hays RD; National Eye Institute Visual Function Questionnaire Field Test Investigators. Development of the 25-item National Eye Institute Visual Function Questionnaire. *Arch Ophthalmol* 2001; 119(7):1050-8.
18. Legge GE, Ross JA, Isenberg LM, LaMay JM. Psychophysics of reading. Clinical predictors of low-vision reading speed. *Invest Ophthalmol Vis Sci* 1992;33(3):677-87.