

# Spontaneous Perforation of the Left Hepatic Duct: Case Report

## Spontan Sol Hepatik Kanal Perforasyonu: Olgu Sunumu

İsmail SERT,<sup>a</sup>  
Semra SALİMOĞLU<sup>a</sup>

<sup>a</sup>Clinic of General Surgery,  
İzmir Tepecik Training and  
Research Hospital, İzmir

Geliş Tarihi/Received: 26.12.2012  
Kabul Tarihi/Accepted: 28.04.2013

Yazışma Adresi/Correspondence:  
İsmail SERT  
Van Regional Training and  
Research Hospital,  
Clinic of General Surgery, Van,  
TÜRKİYE/TURKEY  
drismailsertege@yahoo.com

**ABSTRACT** Spontaneous perforation of the bile duct (SPBD) is a rare status which causes peritonitis. A fifteen-year-old-male patient treated with T tube drainage and Endoscopic Retrograde Cholangiopancreatography (ERCP) due to spontaneous perforation of the left hepatic duct and developed cholangitis at postoperative 8th month was presented in this report. The preoperative diagnosis of SPBD is rather difficult. Usually, the diagnosis is made during the surgical operation. Although the most common location is common bile duct, the hepatic duct perforation could be seen, as well. T tube drainage and ERCP are both effective and confident treatment of choice for these patients. It should be kept in mind that complication of cholangitis can be seen not only in early period but also in late period.

**Key Words:** Bile ducts, extrahepatic; cholangitis; rupture, spontaneous; drainage

**ÖZET** Spontan safra kanalı perforasyonu, peritonite neden olan nadir bir durumdur. Spontan sol hepatic kanal perforasyonu nedeniyle, T tüp drenaj ve Endoskopik retrograd kolanjiyopankreatografi (ERCP) ile tedavi edilen ve ameliyat sonrası 8. ayda kolanjit gelişen 15 yaşında erkek hasta burada sunulmuştur. Ameliyat öncesi Spontan safra kanalı perforasyonu tanısı oldukça zordur. Sıklıkla tanı ameliyat sırasında konur. En sık yerleşim ana safra kanalı olmasına rağmen, hepatic kanal yaralanması da görülebilir. Bu hastalarda T tüp drenaj ve ERCP etkili ve güvenilir tedavi seçenekleridir. Kolanjit komplikasyonunun sadece erken dönemde değil aynı zamanda geç dönemde görülebileceği akıld tutulmalıdır.

**Anahtar Kelimeler:** Safra kanalları, karaciğer dışı; kolanjit; rüptür, kendiliğinden; tahliye

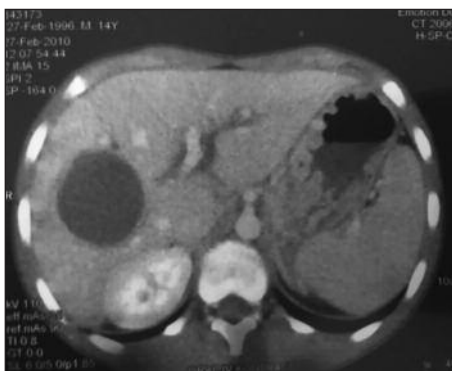
Türkiye Klinikleri J Case Rep 2013;21(2):53-5

Spontaneous perforation of the bile duct (SPBD) is quite rarely seen. It is mostly defined in infants.<sup>1-3</sup> And, some cases were reported in advanced ages.<sup>4,5</sup> In most of the cases, the perforation site is the junction of common bile duct and cystic duct.<sup>6</sup> But the level of hepatic duct is reported only few of cases, especially, in adolescence.<sup>7-9</sup> A fifteen years old adolescence case treated with T tube drainage for spontaneous perforation of the left hepatic duct and developed cholangitis at postoperative 8<sup>th</sup> month was presented in this report.

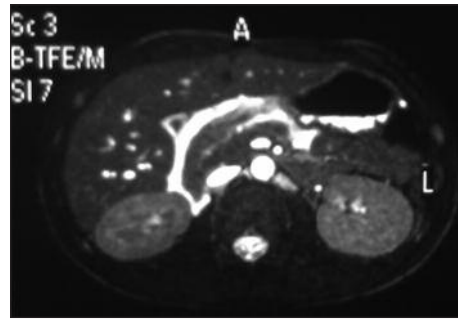
### CASE REPORT

Fifteen-year-old-male patient with upper right quadrant abdominal pain, which started two days before, admitted to our Emergency room. Firstly, he

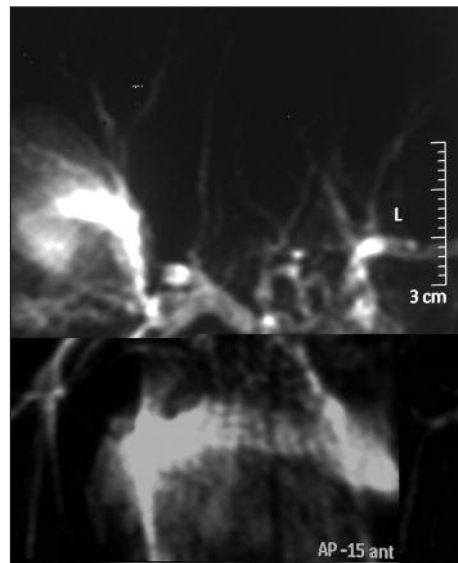
was hospitalized to Infectious Disease Clinic with the pre-diagnosis of acute viral hepatitis. Due to continuing of his abdominal pain, the patient was evaluated by our General Surgery Clinic. There was not any special finding in his history. It was seen that there was a minimal tenderness in right upper quadrant but there was not rebound and defense in physical examination. Laboratory test results was as follows: White Blood Cell(WBC): 15.000 K/ul, Total bilirubin(T.Bil): 4.6 mg/dl, AST: 189 U/L and ALT: 413 U/L. Abdominal Ultrasonography and Computerized Tomography revealed 5x4 cm sized cyst formation in segment 5-8 of the liver concordant with cyst hydatid and distension of intrahepatic bile ducts (Figure 1). Bile ducts at caudal of main bile duct junction were not able to be seen and fluid collection around the perihepatic area attracted attention in Magnetic Resonance Cholangiopancreatography (MRCP) (Figure 2, 3). Meropenem (1 g 3 doses a day) and symptomatic treatment were administered. At day 9 of follow-up, severe abdominal pain and high fever and disseminated peritonitis occurred. Laboratory tests revealed WBC:15.500 K/ul, Neu (%): 81.5, ALP:434 U/L, GGT: 81 U/L, T.Bil: 2.8 mg/dl, Direct Bilirubin: 1.3 mg/dl, Albumin: 3.1g/dl. Emergency laparotomy was performed with the diagnosis of diffuse peritonitis. Perforation of the left hepatic bile duct by 5 mm in a diameter was detected at laparotomy. Surgical treatment consisting of drainage of left hepatic duct by T drain and cholecystectomy were performed. T drain was inserted through the perforation site. Neither stone nor mud detected in exploration of the common



**FIGURE 1:** 5x4 cm sized cyst formation in segment 5-8 of the liver concordant with cyst hydatid and distension of intrahepatic bile ducts in CT scan.



**FIGURE 2:** Fluid collection around the perihepatic area in Magnetic Resonance Imaging.



**FIGURE 3:** Bile ducts at the level of caudal of common hepatic duct junction couldn't be seen in MRCP.

bile duct. When distal common bile duct was checked with 8 Fr feeding catheter, fluid flowed to duodenum without problem. Sphincterotomy with ERCP was applied at postoperative day 1. T tube was removed at postoperative day 14, after patent ducts and free stream flow into the duodenum had been seen in nasobiliary drain cholangiogram. Patient was discharged at postoperative day 22. Cholangitis was developed at 8th month and ERCP performed. Stenosis by 2 cm at distal part of common bile duct was seen in ERCP. Re-sphincterotomy was applied and transient 10 Fr plastic stents were placed to right and left hepatic ducts. Also, nasobiliary drain introduced to left hepatic duct. After performed ERCP with normal findings, the stents were subtracted at 5 weeks of introduction. At 24 months follow-up, the patient was troubleless. In-

formed consent of the patient has been obtained for the publication of this report.

## DISCUSSION

SPBD is quite rarely seen. It is defined in infants mostly.<sup>1-3</sup> In most of the cases, the perforation site is the junction of common bile duct and cystic duct.<sup>4,6</sup> But spontaneous perforation of hepatic duct is reported only few of cases, especially, in adolescence.<sup>7-9</sup> Perforation site was on left hepatic duct, closed to the liver, in the present case.

Classical presentation of SPBD is a combination of symptoms which are upper right quadrant abdominal pain, nausea, vomiting, moderate jaundice and slow advancing assist in healthy person up to these findings.<sup>1,6</sup> Sub-acute presentation is seen 80% of the cases.<sup>1</sup> Our patient has sub-acute presentation, as well. Although the etiology is not well understood, in infants and children, congenital wall weakness, ischemia, distal bile duct obstruction, pancreatic reflux and trauma can be assumed as etiological factors.<sup>1,2</sup> In adults, infection of the bile duct, bile stones, diverticulum, connective tissue defect or ischemia were suggested as possible etiological factors.<sup>5</sup>

Surgical management is needed for most of the cases and it gives better treatment outcomes than

the medical and symptomatic ones.<sup>1,2,4,6</sup> Surgical techniques are defined as simple peritoneal drainage, perforation repair, with or without cholecystectomy plus T tube drainage and Roux-en-Y intestinal anastomosis.<sup>2</sup> It is indicated that ERCP alone can be useful as a non-surgical approach.<sup>2</sup> Accurate diagnosis was achieved by surgical exploration and, the combination of surgical and endoscopic approach was used in our case.

Possible complications of SPBD are cholangitis, portal venous thrombosis and bile leakage.<sup>1,2</sup> Early detection and treatment gives favorable outcomes despite all above mentioned complications.<sup>1</sup> Cholangitis was seen at postoperative 8<sup>th</sup> month in our case. It should be kept in mind that cholangitis can be seen not only in early period but also in late period.

The pre-operative diagnosis of SPBD is rather difficult. Although the most common site of perforation is common bile duct, the possibility of hepatic duct perforation should not be sneezed at. T tube drainage and ERCP are both effective and confident treatment of choice for these patients. It should be kept in mind that complication of cholangitis can be seen not only in early period but also in late period.

## REFERENCES

1. Imanieh MH, Mowla A, Zohouri D, Forootan HR, Karimi M. Spontaneous perforation of the common bile duct with eosinophilia in an 18-month-old girl: a case report and review of literature. *Med Sci Monit* 2006;12(4):CS31-3.
2. Evans K, Marsden N, Desai A. Spontaneous perforation of the bile duct in infancy and childhood: a systematic review. *J Pediatr Gastroenterol Nutr* 2010;50(6):677-81.
3. Steiner Z, Dimitrov D. Spontaneous perforation of the common bile duct mimicking choledochal cyst. *Isr Med Assoc J* 2006;8(9):655-6.
4. Sen M, Turan M, Kurt A, Er Y. Spontaneous perforation of the ductus choledochus: case report. *Cumhuriyet Med J* 2009;31(1):75-7.
5. Kang SB, Han HS, Min SK, Lee HK. Nontraumatic perforation of the bile duct in adults. *Arch Surg* 2004;139(10):1083-7.
6. Özdemir T, Akgül AK, Arpaz Y, Arıkan A. Spontaneous bile duct perforation: a rare cause of acute abdominal pain during childhood. *Turkish Journ Trauma&Emerg Surg* 2008;14(3):211-5.
7. Chen TZ, Chen HC, Chou CM. Spontaneous perforation of the bile duct in a neonate: drainage or resection? *J Chin Med Assoc* 2012;75(7):353-4.
8. Wang CH, Lin RC, Mo LR, Yau MP, Tsai CC. Spontaneous perforation of the left hepatic duct--a case report. *Hepatogastroenterology* 1995;42(1):77-9.
9. Müller MF, Krestin GP, Weder W, Münch R, Wegmann A. [Spontaneous rupture of the left hepatic duct]. *Dtsch Med Wochenschr* 1993;118(11):377-80.