

# Advanced Hydatidosis of the Pelvis, Hip and Femur: Report of a Case

PELVİS, KALÇA VE FEMURUN DEV KİST HİDATİĞİ

Davut KESKİN, MD<sup>a</sup>

<sup>a</sup>Department of Orthopaedics and Traumatology, Atatürk University School of Medicine, ERZURUM

## Abstract

Bone hydatidosis is a rare parasitic disease that necessitates serious attention due to the fact that its treatment is difficult with high failure rates. Early diagnosis as well as combined use of well-planned surgery and chemotherapy are basic requirements for a successful treatment. Failure to provide one of these conditions may result with spreading of the disease to an extent making impossible to cope with it. This paper presents a case in which proximal femoral hydatidosis has spread to the pelvis threateningly due to delayed diagnosis and insufficient surgery performed without any chemotherapy support.

**Key Words:** Echinococcosis; complications; pelvis

**Türkiye Klinikleri J Med Sci 2007, 27:626-628**

## Özet

Kemik hidatidozisi çok nadir görülen, ancak tedavisinin oldukça zor ve başarısızlık oranının yüksek olması nedeniyle üzerinde önemle durulması gereken bir parazit hastalığıdır. Erken teşhis, iyi planlanmış bir cerrahi ve kemoterapinin birlikte kullanılması başarılı bir tedavi için gereklidir. Bu üçlüden birinin eksik olması hastalığın baş edilmesi neredeyse imkansız olacak şekilde yayılmasına neden olabilir. Bu çalışmada geç tanı konmuş, kemoterapi yapılmadan yetersiz bir cerrahi ile tedavi edilmeye çalışılan femur proksimal hidatidozisinin pelvise tehlikeli bir şekilde nasıl yayıldığı anlatılmıştır.

**Anahtar Kelimeler:** Kist hidatik; komplikasyon; pelvis

**H**ydatid disease is a parasitic disease caused by *Echinococcus granulosus* and less frequently by *Echinococcus multilocularis* in humans. The disease is most frequently observed in regions of the world where sheep is bred such as the Mediterranean, Middle-East, Far-East and South America countries. It is localized in the liver and lung by 78% despite reported retentions by other organs and extremities.<sup>1-5</sup> Bone hydatidosis is seen only in 1-2% of the patients.<sup>6,7</sup> Because bone hydatidosis often presents as a cystic lesion, preoperative diagnosis of this rare entity is clearly difficult.<sup>7,8</sup> Early diagnosis and treatment are associated with good outcomes. Thus, it is important to consider the disease for the differential diagnosis of

relevant bone lesions, especially in countries where the disease is more frequent. In this study, a case with hydatidosis located on the proximal part of the left femur that has spread into the pelvis due to insufficient treatment is presented with an emphasis on the difficulty of bone hydatidosis treatment.

## Case Report

A 48-year-old male patient with a pathologic fracture of the left femoral neck was operated and an endoprosthesis was placed in another hospital 11 years ago after which histopathological examination of the samples obtained from the lesion indicated the presence of hydatidosis. However, no drug treatment was initiated for hydatidosis at that time. Upon recurring pain of the hip causing difficulty in walking, the patient was operated again, the prosthesis was removed and the hip was freed. He was able to walk with the help of a crutch. In time, increasing swelling developed around his left hip and upper thigh with very severe pain. He was unable to walk without assistance. The present

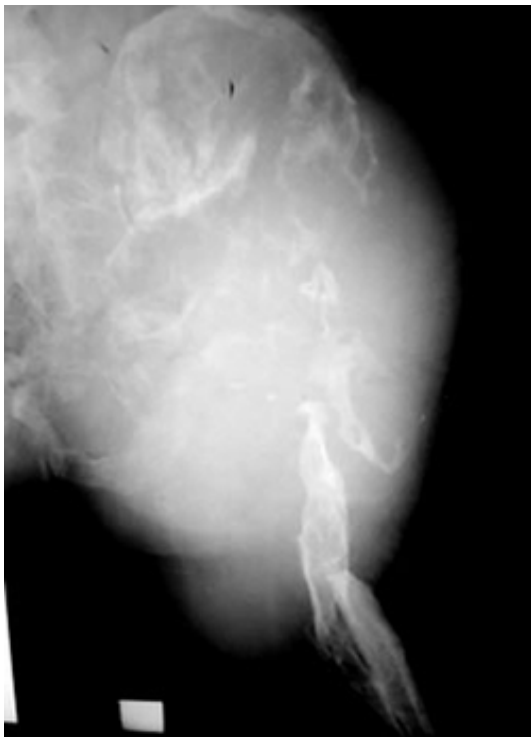Geliş Tarihi/Received: 01.06.2006 Kabul Tarihi/Accepted: 15.01.2007

**Yazışma Adresi/Correspondence:** Davut KESKİN, MD  
Atatürk University School of Medicine,  
Department of Orthopaedics and Traumatology,  
ERZURUM  
keskind2002@yahoo.com

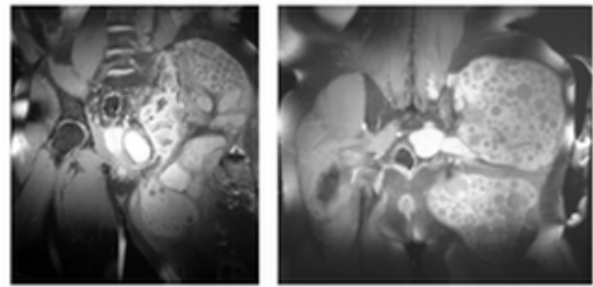
Copyright © 2007 by Türkiye Klinikleri

physical examination revealed a hard, painful and lobulated swelling spreading to the left upper thigh, abdomen and gluteal region. Left lower extremity was 18 cm shorter than the other one. Routine blood and urine examinations were normal except for a medium degree eosinophilia. Indirect hemagglutination test was positive at a titer of 1:256.

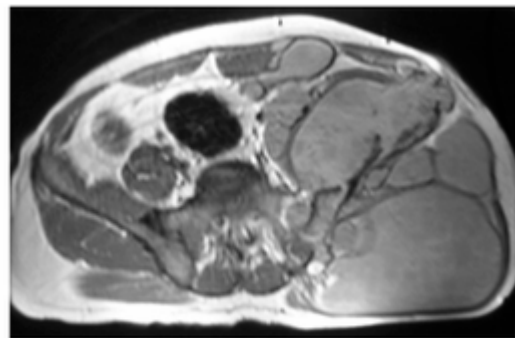
Plain radiography indicated massive destruction at the left iliac wing, os ischii and ramus superior of symphysis pubis. Femoral head was totally lytic. There was no detectable acetabular fossa. Destruction extended to proximal and mid-diaphysis of the left femur. There was also a pathologic fracture at the proximal diaphysis of the femur (Figure 1). Magnetic resonance (MR) images that best revealed the nature of the lesion revealed a huge, multiloculated lesion with daughter cysts within the pelvis located near the left psoas muscle. The lesion was retroperitoneal at the pelvic



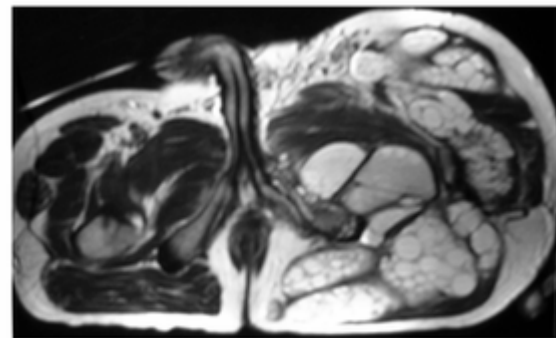
**Figure 1.** Anteroposterior plain radiography of the left iliac wing and femur demonstrating destruction within the iliac wing and left femoral head. Note also calcification within the soft tissues of the gluteal area. There is also a pathologic fracture at the proximal femur diaphysis.



**Figure 2.** T1 weighted, fat saturated coronal MR images show cyst-hydatid lesions with multiple daughter cysts. There is a massive destruction at the left iliac wing. The lesions extend to the left gluteal area and adductor muscles.



A



B

**Figure 3.** Axial proton-density (A) and T2-weighted (B) images show multiloculated cyst-hydatid with daughter cysts. Note also destruction at the left wing and left femur.

region and it displaced the bladder and rectum toward the left side. Lesion extended to the left gluteal area and adductor muscles. The iliac wing, left femoral head, proximal femoral diaphysis were highly destroyed (Figure 2 and 3). Plain x-rays of the chest and abdominal MR images did not reveal any other organ involvement. The patient did not accept any surgical intervention.

## Discussion

Although bone hydatidosis is a very rare disease, it requires special care due to the difficulty of treatment and discouraging outcomes. The radiographic and clinical findings of bone hydatidosis are not specific. They include early irregular absorption of bone and late multilocular cysts with a honeycomb aspect. Bone hydatidosis may be easily misdiagnosed as osteomyelitis, aneurysmal bone cyst, giant cell tumor, angioma, fibrous dysplasia, and other cystic lesions since the radiographic findings are not specific.<sup>7,8</sup> Serological tests performed for the diagnosis may be misleading due to negative results in most cases.<sup>8,9</sup> Because spread of the cyst contents during biopsy may later cause secondary cysts or allergic reactions, open or percutaneous needle biopsy is not recommended.<sup>1</sup> Early diagnosis and treatment are associated with good outcomes. It is therefore important to consider the disease for the differential diagnosis of relevant bone lesions, especially in countries where the disease is more frequent. Computed tomography allows the evaluation of the extent of bone disruption and other extraosseous lesions.<sup>8,10</sup> MR imaging is very useful in determining the extent of the disease and surgery.<sup>10</sup>

The treatment of bone hydatidosis may be medical or surgical. A local recurrence rate of 70-80% was reported after surgery.<sup>7,11</sup> Although there are reports of successful outcomes after medical treatment in patients who had an early diagnosis without any surgical interventions due to any reason, the treatment of bone hydatidosis mainly involves the use of surgical and medical (albendazole or mebendazole) treatment together.<sup>3,6,10,12</sup> While some authors prefer large marginal excision for surgical treatment, others advocate local excision and curettage.<sup>7,9,13,14</sup> In cases with bone hydatidosis close to the joint, as in our case, placement of prostheses following large marginal excision are also considered.<sup>15</sup> Chemotherapy along with early diagnosis and complete removal of diseased region seems to be the key for successful outcome. It will be therefore reasonable to keep always in mind that bone hydatidosis in countries where the disease is frequently observed may be

the cause in such conditions, and to use MR imaging to determine the extent of the disease. As in the present case, inadequate surgical treatment not combined with appropriate medical treatment may lead to a situation where cysts spread in a manner almost impossible to handle and tissues are destroyed.

## REFERENCES

1. Keskin D, Ezirmik N, Karsan O, Gursan N. Primary hydatidosis of the gracilis muscle in a girl. *J Int Med Res* 2002;30:449-51.
2. Amir-Jahed AK, Fardin R, Farzad A, Bakshandeh K. Clinical echinococcosis. *Ann Surg* 1975;182:541-6.
3. Martinez AA, Herrera A, Cuenca J, Herrero L. Hydatidosis of the pelvis and hip. *Int Orthop* 2001;25:302-4.
4. Santavirta S, Valtonen M, Patiala H, Saarinen O, Kontinen YT. Disseminated hydatid disease causing paraplegia and destruction of the hip. *Arch Orthop Trauma Surg* 2000;120:118-20.
5. Balik AA, Celebi F, Basglu M, Oren D, Yildirgan I, Atamanalp SS. Intra-abdominal extrahepatic echinococcosis. *Surg Today* 2001;31:881-4.
6. Szypryt EP, Morris DL, Mulholland RC. Combined chemotherapy and surgery for hydatid bone disease. *J Bone Joint Surg Br* 1987;69:141-4.
7. Agarwal S, Shah A, Kadhi SK, Rooney RJ. Hydatid bone disease of the pelvis. A report of two cases and review of the literature. *Clin Orthop Relat Res* 1992;(280):251-5.
8. Masse A, Parola PG, Brach del Prever EM, Gallinaro P. Hydatidosis of the pelvis: A case report with a 25-year follow-up. *Arch Orthop Trauma Surg* 2004;124:203-5.
9. Sapkas GS, Stathakopoulos DP, Babis GC, Tsarouchas JK. Hydatid disease of bones and joints. 8 cases followed for 4-16 years. *Acta Orthop Scand* 1998;69:89-94.
10. Markonis A, Tavernaraki A, Papaevangelou M. Humeral hydatid cyst complicated with extraosseous involvement: A case of unusual location of echinococcosis. *Eur J Radiol* 2001;37:130-3.
11. Ferrandez HD, Gomez-Castresana F, Lopez-Duran L, Mata P, Brandau D, Sanchez-Barba A. Osseous hydatidosis. *J Bone Joint Surg Am* 1978;60:685-90.
12. Poyanli A, Akan K, Poyanli O, Sencer S, Sayrak H. Primary hydatid disease of the femur: Unsuspected and incidental MRI findings with long-term curative results on medical treatment alone. *Skeletal Radiol* 2001;30:656-8.
13. De Cristofaro R, Ruggieri P, Biagini R, Picci P. Case report 629: Osseous hydatidosis. *Skeletal Radiol* 1990;19:461-4.
14. Ocete G, Guerrero A, Diaz-Peletier R, Burgos J, Bouza E, De Miguel C. Experience in the treatment of osseous hydatidosis. *Int Orthop* 1986;10:141-5.
15. Natarajan MV, Kumar AK, Sivaseelam A, Iyakutty P, Raja M, Rajagopal TS. Using a custom mega prosthesis to treat hydatidosis of bone: A report of 3 cases. *J Orthop Surg (Hong Kong)* 2002;10:203-5.