

Trisomy 13 Presented with Bilateral Anophthalmia, Postaxial Polydactyly on the Left Foot and Coarse Facial Appearance in a Newborn Infant: Case Report

Yenidoğan Bir Bebekte Her İki Gözde Anoftalmi, Sol Ayakta Lateral Sırada Fazla Parmak ve Kaba Yüz Görünümü ile Birlikte Sunulan Trizomi 13 Olgusu

Pehmen Yasin ÖZCAN,^a
Hasan Tolga ÇELİK,^b
Ebru TUNÇEZ,^c
Melda ÇELİK^d

^aClinic of Ophthalmology,
Şanlıurfa Training and Research Hospital,
Clinics of

^bNeonatology,
Neonatal Intensive Care Unit,
^cMedical Genetic,

^dPediatric Infectious Diseases,
Şanlıurfa Children's Hospital,
Şanlıurfa

Geliş Tarihi/Received: 07.01.2016
Kabul Tarihi/Accepted: 15.06.2016

Yazışma Adresi/Correspondence:
Pehmen Yasin ÖZCAN
Şanlıurfa Training and Research Hospital,
Clinic of Ophthalmology, Şanlıurfa,
TURKEY/TÜRKİYE
ozcan.yasin@yahoo.com

ABSTRACT A 1 day-old female infant was born at 36 weeks of gestation was charged in neonatal intensive care unit due to respiratory distress. Physical examination findings which aroused suspicious of a chromosomal anomaly included bilateral anophthalmia, postaxial polydactyly on the left foot, coarse facial appearance, wide and prominent nasal bridge, redundant nuchal skin, trigonocephaly. Abdominal and genitourinary system ultrasonographic findings were evaluated as normally. Family history was unremarkable. Because of having two healthy children, the parents had not applied to any gynecologist during the pregnancy period. In chromosome analysis, trisomy at the 13rd chromosome was revealed (47,XX,+13). The patient died on the postnatal first day due to severe respiratory insufficiency.

Keywords: Patau syndrome; anophthalmos; chromosome 13p duplication

ÖZET Otuzaltıncı doğum haftasında, kız cinsiyetine sahip olan bir günlük bebek solunum sıkıntısı nedeniyle yenidoğan yoğun bakım servisine yatırıldı. Kromozomal anomali şüphesi uyandıran klinik bulgulara sahip olgunun yapılan fiziksel muayenesinde her iki gözde anoftalmi, sol ayakta lateral sırada fazla parmak oluşumu, kaba yüz görünümü, nazal kemik çıkıntısında genişleme ve belirginleşme, ense cildinde kalınlaşma ve üçgen şeklinde kafatası saptandı. Batın ve genitouriner sistem ultrasonografi bulguları normal olarak değerlendirildi. Aile öyküsünde herhangi bir özellik yoktu. Bebeğin ailesi, önceden sağlıklı 2 çocuğa sahip oldukları için gebelik süresi boyunca hiç bir kadın hastalıkları ve doğum uzmanına başvurmadıklarını belirtti. Hastanın yapılan kromozom analizinde 13. Kromozomda trizomi (47,XX,+13) saptandı. Doğumdan sonraki 1. günde, hasta şiddetli solunum yetmezliği nedeni ile hayatını kaybetti.

Anahtar Kelimeler: Patau sendromu; anoftalmi; kromozom 13p duplikasyon

Trisomy 13 known as Patau syndrome is a rare lethal syndrome and is characterized by the presence of an extra chromosome 13 in each cell of the body. This syndrome is the third most commonly diagnosed autosomal trisomy syndrome among liveborn infants.¹ The prevalence is estimated between 1/10 000 and 1/20 000 in live births, generally resulting with spontaneous abortion.² This rare but lethal chromosomal disorder is associated with multiple congenital anomalies including microphthalmia or anophthalmia, microcephaly, holoprocencephaly, scalp defects, postaxial polydactyly of the hands or feet, orofacial clefting, congenital heart defects, and severe mental and growth retardation.³

Here, we report a case of newborn infant with trisomy 13 that confirmed by chromosomal analysis had bilateral anophthalmia, postaxial polydactyly of foot and coarse facial appearance.

CASE REPORT

The newborn with female gender was delivered at 36 weeks of gestation by emergency cesarean section delivery due to maternal HELLP syndrome, whose parents, a healthy 22-year-old mother and 25-year-old father, have consanguineous (*first-cousin*) marriage. Her siblings were healthy and family history was unremarkable. Because of having two healthy children, the parents had not ap-

plied to any obstetrician during the pregnancy period. On physical examination multiple dysmorphic features including coarse face, trigonocephaly, prominent metopic ridge, simple ears, sparse eyebrows, bilateral anophthalmia and disorganized intraocular structures with the presence of normal eyelid margins (Figure 1 A-B) were detected. In addition to excepting for cleft lip or palate, large nose, wide and prominent nasal bridge, wide philtrum, thin vermilion of lower and upper lips, horizontal chin crease, retrognathia, short neck, redundant nuchal skin, bilateral single palmar creases, hyperconvex nails of hands, postaxial polydactyly of right foot, hypoplastic toe nails were observed (Figure 1 C-D-E). Respiratory dis-

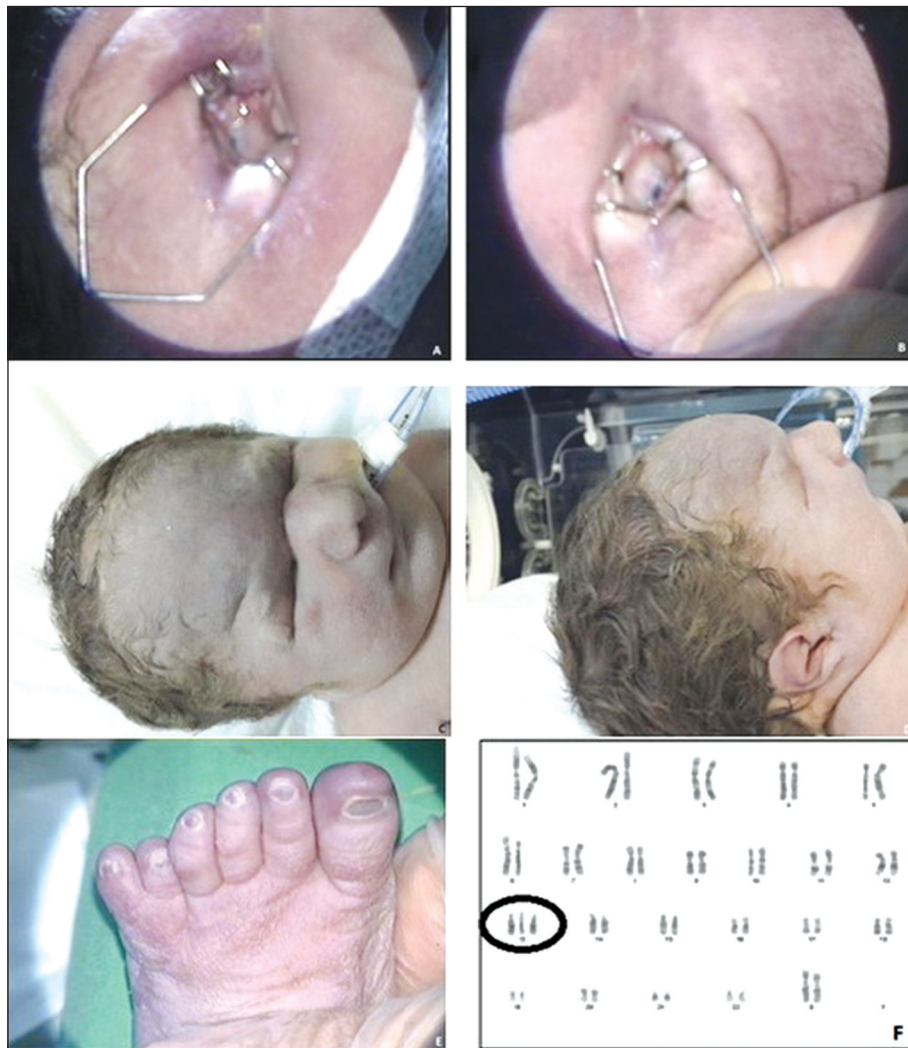


FIGURE 1: Color images of the patient. (A) anophthalmia in the right eye (B) anophthalmia in the left eye (C) coarse facial appearance (D) simple ear (E) postaxial polydactyly of right foot and hypoplastic toe nails (F) Karyotype of the patient showing 47,XX,+13 with GTG banding.

(See color Figure at <http://www.turkiyeklinikleri.com/journal/oftalmoloji-dergisi/1300-0365/tr-index.html>)

tress findings and diffuse interstitial pneumonic infiltration were showed on the chest radiography. Cerebral and cerebellar hypoplasia was detected on the transfontanellar ultrasound. To determine any cardiac, cranial and ocular anomalies by means of computerized tomography (CT) or magnetic resonance imaging (MRI) and echocardiography could not be performed because of clinical instability. Abdominal and renal tract ultrasonographic findings were normal. Since the baby had major dysmorphic findings, she was consulted to the medical geneticist. Chromosome analysis of peripheral leukocytes using GTG (450-550) banding technique at 20 metaphase revealed free trisomy 13 (47,XX,+13) (Figure 1-F). The patient died at the first day of her life from severe respiratory insufficiency. The family did not accept the autopsy and genetic counseling was offered to the parents by the medical geneticist.

DISCUSSION

Here, we present the clinical features and genetic data of a newborn infant with free trisomy 13, diagnosed in Sanliurfa province, Southeastern Anatolia region of Turkey. Trisomy 13 (Patau syndrome) is the third most commonly observed autosomal trisomy syndrome and involves multiple abnormalities many of which are not compatible with life, therefore it is resulted more commonly with spontaneous abortions.¹ Although the clinical triad of Patau syndrome consists of microphthalmia, cleft lip and palate and polydactyly, they were not presented for most cases. Cardinal findings include motor-mental retardation, microcephalus, holoprosencephaly, hypotelorism, and cardiovascular, genitourinary, and/or ocular malformations. Since there are no pathognomonic clinical findings leading to early identification, it is mandatory to perform cytogenetic analysis for definitive diagnosis. According to the results of 30 cases discussed in a review, the main findings were cryptorchidism (78%), abnormal auricles (77%), polydactyly of hands and/or feet (63%), microphthalmia (60%), micrognathia (50%), low-set ears (47%), aplasia cutis/scalp defects (43%) and microcephaly (40%).⁴

In our patient we revealed that bilateral anophthalmia, postaxial polydactyly of foot, micrognathia, abnormal auricles, large nose, short neck, hypoplastic toe nails. Postaxial polydactyly in Patau syndrome is one of the key elements of diagnosis and reported in 52-70% of cases. Although cleft lip and palate are present in 60-70% of cases, neither cleft lip nor cleft palate was observed in this case.⁵ Patients with trisomy 13 have significant involvement of central nervous system and are at high risk of profound mental retardation. Holoprosencephaly and other forebrain developmental anomalies are common. Less commonly, these patients may have hypoplasia of the cerebellum, hydrocephalus and spinal dysraphism. In presented case cerebral and cerebellar hypoplasia was detected and holoprosencephaly was suspected on transfontanellar ultrasound but clinical instability did not allow to confirm this via cranial MRI.

Ophthalmologic findings are common seen in trisomy 13. The most frequent ocular findings of Patau syndrome are microphthalmia, coloboma of the ciliary body and iris, and retinal dysplasia.⁵ Microphthalmia is a rare congenital anomaly affecting about 14/100 000 newborns, while anophthalmia is four times more rare (3/100 000 of newborns). In addition to about 16% of cases of anophthalmia/microphthalmia there is a chromosomal etiology, which trisomy 13 remains the main abnormality.⁶

Anophthalmia/microphthalmia is present in 60-70% of cases of trisomy 13.⁶ Anophthalmia has been reported in about 10% of individuals in three reported reviews.⁷ Other described ocular abnormalities in trisomy 13 include iris coloboma, persistent primary hyperplastic vitreous (PPHV), cataract, cycloopia, primary aphakia, bupthalmos due to congenital glaucoma.⁴ Bilateral prominent anophthalmia including disorganized remnants of intraocular structures associated with trisomy 13 had been observed in our patient. To our knowledge, this is the unique case of trisomy 13 with bilateral anophthalmia accompanied by disorganized intraocular structures and postaxial polydactyly of right foot.

The patient had typical abnormalities for trisomy 13 such as coarse facial appearance and

postaxial polydactyly as well as bilateral anophthalmia and delivered from a mother with a history of HELLP syndrome. The incidence of pre-eclampsia in pregnancies complicated by trisomy 13 has been reported to be significantly higher than normal karyotype populations.⁸ So, maternal HELLP syndrome strengthened the clinical suspicion of trisomy 13 in current case.

The exact diagnosis is established through chromosome analysis. Most frequent cytogenetic abnormality is free and homogeneous trisomy 13 (80.0%), rarely being detected as trisomy mosaics (5%) or Robertsonian translocations (10%). The mechanisms that cause this chromosomal abnormality are not completely known. In most cases it is a free homogeneous trisomy with the extra chromosome having a maternal origin in 90% of cases.⁹ In the presented case, classic free trisomy 47, XX,+13 was detected by karyotype analysis.

Trisomy 13 is associated with very low survival rates due to congenital malformations of the central nervous (CNS), cardiac, circulatory and urogenital systems and almost 50% of the cases die in the first month and 90% during the first year of life. The median survival of patients with trisomy 13 ranges from 2.5 to 10 days.^{2,10} The probability of survival until one month age is about 28% and only 5-10% survive for one year.¹⁰ Our patient died at the first day of life with severe respiratory insufficiency. All the cases suffer motor and mental deficits. The most common cause of death is car-

diopulmonary complications such as pulmonary hypoplasia and respiratory insufficiency as in the presented patient.

Prenatal ultrasonography (USG) is a powerful tool to detect structural abnormalities associated with the fetus in trisomy 13 pregnancies.¹¹ Detection of the anomalies in the fetus helps the parents accept prenatal genetic counseling including amniocentesis and therapeutic abortion. Early clinical recognition of trisomy 13 at birth remain essential to optimize guidance for care of the child and his family. Unfortunately, the parents of the present case had not been referred to an obstetrician for follow up.

Finally, this case may reflect the lack of health serving and awareness of prenatal following importance during the pregnancy period among parents living especially in rural parts of southeastern anatolia region in Turkey.

Acknowledgments

The authors thank the family of the patient for their cooperation.

Conflict of Interest

Authors declared no conflict of interest or financial support.

Authorship Contributions

Pehmen Yasin Özcan was responsible for ophthalmological examination and reduction of the paper; Hasan Tolga Çelik was responsible for clinical examination, treatment of the patient and correction of the paper; Ebru Tunçez was responsible for correction of the paper.

REFERENCES

1. Parker SE, Mai CT, Canfield MA, Rickard R, Wang Y, Meyer RE, et al; National Birth Defects Prevention Network. Updated National Birth Prevalence estimates for selected birth defects in the United States, 2004-2006. *Birth Defects Res A Clin Mol Teratol* 2010;88(12): 1008-16.
2. Brewer CM, Holloway SH, Stone DH, Carothers AD, FitzPatrick DR. Survival in trisomy 13 and trisomy 18 cases ascertained from population based registers. *J Med Genet* 2002;39(9):e54.
3. Gorlin RJ, Cohen MM Jr, Hennekam RC. Trisomy 13 (Patau) syndrome. *Syndromes of the Head and Neck*. 4th ed. New York: Oxford University Press, Inc; 2001. p.42-5.
4. Petry P, Polli JB, Mattos VF, Rosa RC, Zen PR, Graziadio C, et al. Clinical features and prognosis of a sample of patients with trisomy 13 (Patau syndrome) from Brazil. *Am J Med Genet A* 2013;161A(6):1278-83.
5. Bunting R, Leitch J. Buphthalmos in trisomy 13. *Eye (Lond)* 2005;19(4):487-8.
6. Morrison D, FitzPatrick D, Hanson I, Williamson K, van Heyningen V, Fleck B, et al. National study of microphthalmia, anophthalmia, and coloboma (MAC) in Scotland: investigation of genetic aetiology. *J Med Genet* 2002;39(1):16-22.
7. Hodes ME, Cole J, Palmer CG, Reed T. Clinical experience with trisomies 18 and 13. *J Med Genet* 1978;15(1):48-60.
8. Tuohy JF, James DK. Pre-eclampsia and trisomy 13. *Br J Obstet Gynaecol* 1992;99(11): 891-4.
9. Bugge M, Collins A, Hertz JM, Eiberg H, Lundsteen C, Brandt CA, et al. Non-disjunction of chromosome 13. *Hum Mol Genet* 2007;16(16):2004-10.
10. Parker MJ, Budd JL, Draper ES, Young ID. Trisomy 13 and trisomy 18 in a defined population: epidemiological, genetic and prenatal observations. *Prenat Diagn* 2003;23(10):856-60.
11. Chen CP. Prenatal sonographic features of fetuses in trisomy 13 pregnancies. IV. *Taiwan J Obstet Gynecol* 2010;49(1):3-12.