

# An Unusual Case of a Pericardial Mass with Effusion: Lymphoma or Tuberculosis?: Case Report

## Perikardiyal Kitle ile Birlikte Efüzyonu Olan Sıradışı Bir Olgu: Lenfoma veya Tüberküloz?

Ferhat EYYÜPKOCA,<sup>a</sup>  
Olçay DİŞLİ,<sup>b</sup>  
M. Sait ALTINTAŞ,<sup>a</sup>  
Şiho HİDAYET,<sup>a</sup>  
Barış AKÇA<sup>b</sup>

Departments of  
<sup>a</sup>Cardiology,  
<sup>b</sup>Cardiovascular Surgery,  
İnönü University Faculty of Medicine,  
Malatya

Geliş Tarihi/Received: 14.04.2013  
Kabul Tarihi/Accepted: 27.10.2013

Yazışma Adresi/Correspondence:  
Barış AKÇA  
İnönü University Faculty of Medicine,  
Department of Cardiovascular Surgery,  
Malatya,  
TÜRKİYE/TURKEY  
baris.akca@inonu.edu.tr

**ABSTRACT** Pericardial effusion is a frequent finding can occur secondary to many diseases such as following a viral infection even most of the time etiology can not be found. An unusual case of cardiac lymphoma presenting with pericardial effusion simulating tuberculosis (TBC) pericarditis was reported in a 49-year-old man admitted for evaluation of progressive dyspnea and general fatigue. Clinical presentation was congestive heart failure. Tuberculosis pericarditis was first suspected due to positive purified protein derivative (PPD) result, pericardial thickening on echocardiogram, physical examination findings (Kussmaul sign, pulsus paradoxus), insidious progress, high adenosine deaminase (ADA) levels in pericardial fluid. Heart failure symptoms initially improved with pericardiosynthesis but subsequently worsened and following bone marrow aspiration biopsy it was diagnosed as diffuse large B-cell lymphoma.

**Key Words:** Lymphoma, large B-Cell, diffuse; tuberculosis; pericardial effusion; heart failure

**ÖZET** Perikardiyal efüzyonun çoğu zaman etiyolojisi bilinemez ancak sıklıkla birçok hastalığa sekonder (en sık viral enfeksiyon sonrası) oluşabilen bir bulgudur. İlerleyici dispne ve halsizlik şikayetleri ile başvuran 49 yaşında erkek hastada tüberküloz perikarditini taklit eden sıradışı bir kardiyak lenfoma olgusunu sunduk. Klinik olarak bulgular konjestif kalp yetersizliği ile uyumluydu. Pozitif tüberkülin deri testi (PPD), yapılan ekokardiyografideki perikardiyal kalınlaşma, fizik muayene bulguları (Kussmaul bulgusu, pulsus paradoksus), perikardiyal sıvıdaki yüksek adenozin deaminaz (ADA) düzeyi, sinsü seyri nedeniyle öncelikle tüberküloz perikarditten şüpheniildi. Perikardiyosentez sonrası kalp yetersizliği semptomları her ne kadar düzeldi ise de sonrasındaki klinik kötüleşmeyi takiben yapılan kemik iliği aspirasyon biyopsisi diffüz büyük B hücreli lenfoma olarak sonuçlandı.

**Anahtar Kelimeler:** Lenfoma, büyük B-hücreli, yaygın; tüberküloz; perikardiyal efüzyon; kalp yetersizliği

Türkiye Klinikleri J Case Rep 2013;21(4):208-11

Pericardial effusion may be the first presentation of various pathologies including malignant diseases.<sup>1</sup> In the presence of effusion, assessment should be performed considering the patient's clinical status, age, presence of other diseases which can appear with pericardial involvement. The prognosis remains poor for malignant diseases such as lymphomas due to diagnostic delay and relevance of the site of disease.

## CASE REPORT

A 49 years-old male patient with no previously known history of heart disease admitted to hospital with the complaint of shortness of breath and fatigue worsened gradually in the last 20 days. On physical examination; Kusmaull and pulsus paradoxus signs were positive. Jugular venous pressure was high. The patient was afebrile and lymph nodes were not palpable. Cardiac and chest auscultation was normal.

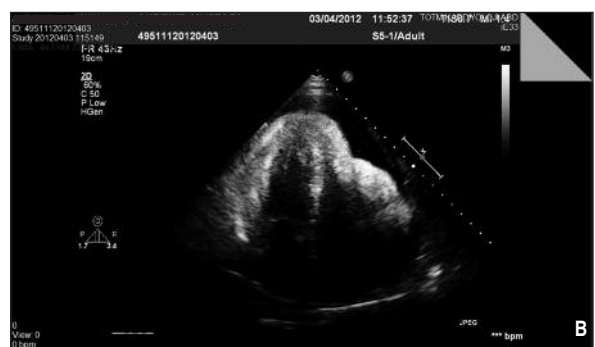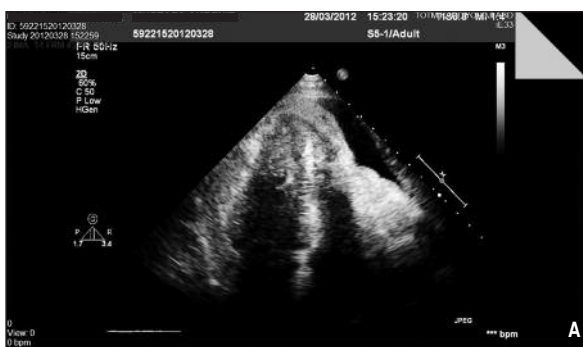All blood tests including thyroid functions, tumor and inflammation markers were all normal. Serologic markers such as high-sensitivity C-reactive protein (CRP), rheumatoid factor, anti-nuclear antibody, anti-dsDNA, Anti-HIV and Brucella antibodies were all negative. First peripheral blood smear was also normal.

Chest X-ray revealed cardiomegaly as well as bilateral pleural effusion even much more on right side. The standard 12-lead ECG was in normal sinus rhythm. There was not any ST-T segment changes. On echocardiographic examination; ejection fraction of left ventricle (LV) was 60% and pericardial effusion was measured as 1.5 cm in front of right ventricular outflow tract (RVOT), 1.8 cm at posterior of LV and 1.7 cm at apex. Thickening of visceral pericardium (seen like a pericardial mass) was measured 11mm at posterior wall and 15 mm at apex (Figure 1A, B). There was also respiratory variation in mitral inflow pulse wave doppler with septal bounce motion.

The patient's PPD result was measured 15x20 mm on forearm. Meanwhile, it must be emphasized that the patient had a contact history with a family member diagnosed with tuberculosis (TBC). Therefore, one of the possible initial diagnosis was tuberculosis because of the pleural effusion on chest X-ray, family history, positive PPD result, physical and echocardiographic findings.

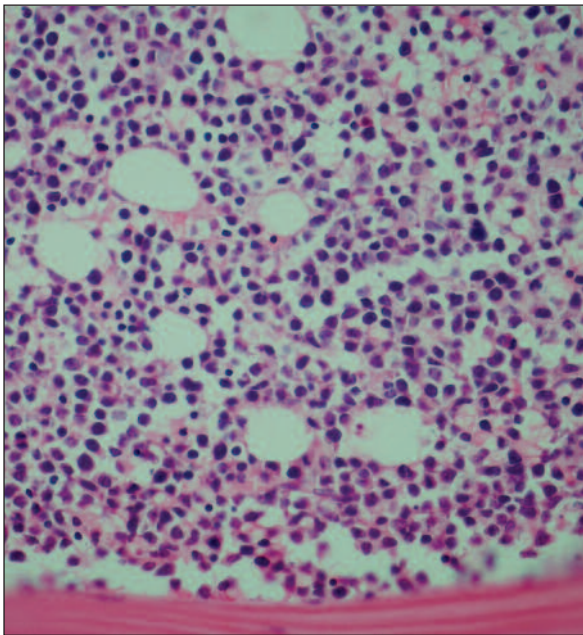
Abdomen and thorax computed tomography (CT) scans were revealed paraaortic, paratracheal lymph nodes and fluid collection around ascending/aortic arch and pericardial/pleural effusion. In thorax magnetic resonance imaging (MRI); tuberculosis pericarditis and tuberculosis aortitis was thought by radiologists as the suspected diagnoses. Thoracentesis was performed. Fluid was transudative. Polymerase chain reaction (PCR) for *Mycobacterium tuberculosis*, fluid smear, TBC culture, adenosin deaminaz (ADA) levels and cytology studied from pleural fluid. PCR for *Mycobacterium tuberculosis*, fluid smear and cytology were negative except for the high lactate dehydrogenase (LDH) level (161 mg/dL). Antituberculosis treatment was initiated because of high degree suspicion of TBC.

Pericardiocentesis and partial resection of the pericardium were performed by cardiovascular surgeons. 850 mL pericardial fluid was drained. Pericardial biopsy and fluid specimens were sent to pathology, cytology laboratory. After the results, there was no evidence in favor of malignancy or tuberculosis when examining pericardial, pleural fluid cytologies and pericardial biopsy specimens at pathology laboratory.



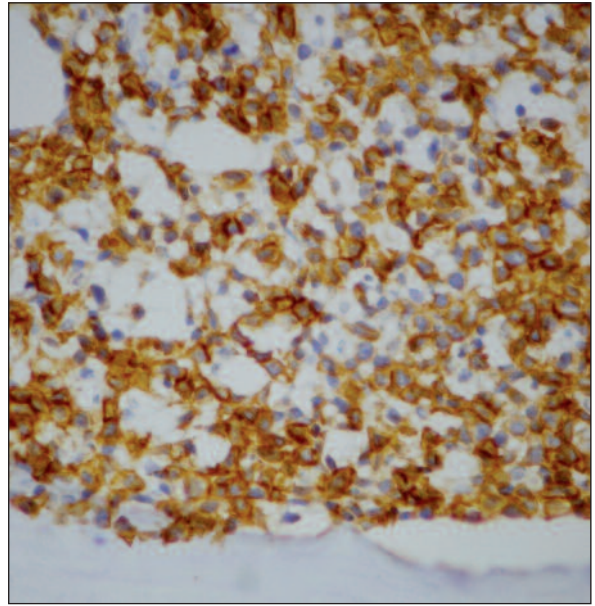
**FIGURE 1A, B:** Transthoracic echocardiography of apical four chamber views showing thickening of visceral pericardium in systole and in diastole (resembling like a pericardial mass).

However, the patient did not feel recovered after pericardiocentesis and shortness of breath became apparent again. That's why a control echocardiography performed and there was only a minimal pericardial effusion. In his follow-up in cardiology service; white blood cell counts were found elevated during routine blood screening. However, because there was no infection clinics or parameters, he was consulted to hematology department. After bone marrow aspiration biopsy he was transferred to the hematology service with the diagnosis of lymphoma. Antituberculosis treatment was stopped after tuberculosis culture was negative. In hematology service, another bone marrow biopsy revealed diffuse non-Hodgkin large B-cell lymphoma (diffuse NHL) (CD45+CD20+ CD79a- CD3- BCL2+ CD117- CD 68- BCL6-) (Figure 2, 3). Then one cure cyclophosphamide, hydroxydaunorubicin, oncovin, prednisone (CHOP) regimen was administered. During his chemotherapy patient's general status got worsened and oxygen saturation fell down. Finally, he was died in intensive care unit despite all medical treatments in a one week period.



**FIGURE 2:** View of the bone marrow with loss of first fat space near the bone trabecula, and replacement of hematopoietic tissue by mononuclear atypical cells (Hematoxylin and eosin x 400).

(See color figure at <http://www.turkiyeklinikleri.com/journal/turkiye-klinikleri-journal-of-case-reports/1300-0284/tr-index.html>)



**FIGURE 3:** Diffuse, strong positivity with CD20 antibody in the atypical mononuclear cells (Bond polymer immunohistochemistry, DAB chromogen x600).

(See color figure at <http://www.turkiyeklinikleri.com/journal/turkiye-klinikleri-journal-of-case-reports/1300-0284/tr-index.html>)

## DISCUSSION

Malignancy is one of the top causes of pericardial effusion, responsible for one third to one half of cases in the general population.<sup>2</sup> However, pericardial involvement of malignancy is suspected in only 20% of patients who have pericardial involvement confirmed at autopsy because pericardial invasion is often insidious.<sup>3</sup> Pericardial invasion of malignant lymphoma is a rare but well-known complication. Pericardial effusion due to non-Hodgkin lymphoma is not common, existing in less than 1% of cases and also tuberculosis pericarditis is seen rare, presenting in %1 of cases which is similar to those of lymphoma.<sup>4,5</sup> Lymphoma often produces false-negative results on cytologic examination and additionally if the neoplasm involves only the visceral pericardium, a biopsy of the parietal tissue can not be enough for the diagnosis.<sup>6</sup> These factors may led to the initial failure to get a diagnosis in our patient.

Clinical presentations associated with lymphoma with cardiac involvement are heterogeneous. Symptoms of these lymphomas most

commonly are systemic symptoms such as fever or weakness, heart failure, pericardial effusion, arrhythmias and cardiac tamponade.<sup>7</sup> Fuzellier et al. reported that the most frequent manifestations of lymphoma are arrhythmias, dyspnea, tamponade and right-sided heart failure.<sup>8</sup> Myocardial involvement by lymphoma may be the reason of congestive heart failure signs and symptoms in our patient.

Moreover, as mentioned above, cardiac tamponade is a frequent manifestation of lymphoma and the association of a tamponade with an alteration of the general state or signs leads directly to a malignant disease.<sup>9</sup> This variable clinic of cardiac lymphoma had been also present in our patient. The present case had severe heart failure symptoms and also had several different physical examination and echocardiographic findings on admission. Although we did numerous of diagnostic tests including negative pericardial biopsy, the patient's clinic status was deteriorating and some of the positive test results led us to think that this deteriorating clinic was mostly due to tuberculosis. Tuberculosis pericarditis was first the suspected diagnosis because of positive PPD result, pericardial thickening and mass image seen on echocardiogram, physical examination findings (Kussmaul sign, pulsus paradoxus etc...), insidious progress, high ADA levels in pericardial fluid and so on.

Tuberculosis pericarditis is detected in 1 to 2% of all acute pericarditis cases and cardiac tamponade is the main finding in 7% of these cases.<sup>10</sup> There

are clinical similarities between tuberculosis patients and lymphoma patients. The complaints are usually associated with the magnitude of the effusion and with the constitutional symptoms (such as weight loss, fever) in both types of patients.<sup>11,12</sup> So it not easy to distinguish lymphoma from tuberculosis from only clinical signs and symptoms point of view.

However, in our patient, because of the rapid deterioration of patient's clinic and a sudden rise in the white blood cells in renewed hemogram analysis led to think another possible etiology. Ultimately, renewed peripheral blood smear and bone marrow biopsy confirmed the diagnosis which was a lymphoma. For this patient, except high ADA levels which could be suggestive for lymphoma, hemogram and first peripheral blood smear were all normal as well as pericardial biopsy.

Several points of interest are illustrated by this case. First, the possibility of malignancy must be considered any time when pericardial effusion occurs and should be excluded in every case of acute pericardial disease. NHL should always be considered in the differential diagnostic spectrum. Second, patients with lymphoma or tuberculosis-related pericardial effusion have similar clinical, radiological, and laboratory characteristics. Lastly, even though ADA levels in pericardial fluid tend to be high both in tuberculosis and in lymphoma-related pericardial effusions, this variable may overlap as in our case.

## REFERENCES

- Vaitkus PT, Herrmann HC, LeWinter MM. Treatment of malignant pericardial effusion. *JAMA* 1994;272(1):59-64.
- Allen KB, Faber LP, Warren WH, Shaar CJ. Pericardial effusion: subxiphoid pericardiostomy versus percutaneous catheter drainage. *Ann Thorac Surg* 1999;67(2):437-40.
- Kralstein J, Frishman W. Malignant pericardial diseases: diagnosis and treatment. *Am Heart J* 1987;113(3):785-90.
- Das DK, Gupta SK, Ayyagari S, Bambery PK, Datta BN, Datta U. Pleural effusions in non-Hodgkin's lymphoma. A cytomorphologic, cytochemical and immunologic study. *Acta Cytol* 1987;31(2):119-24.
- Kim HY, Song KS, Goo JM, Lee JS, Lee KS, Lim TH. Thoracic sequelae and complications of tuberculosis. *Radiographics* 2001;21(4):839-58; discussion 859-60.
- Press OW, Livingston R. Management of malignant pericardial effusion and tamponade. *JAMA* 1987;257(8):1088-92.
- Ceresoli GL, Ferreri AJ, Bucci E, Ripa C, Ponzoni M, Villa E. Primary cardiac lymphoma in immunocompetent patients: diagnostic and therapeutic management. *Cancer* 1997;80(8):1497-506.
- Fuzellier JF, Saade YA, Torossian PF, Baehrel B. [Primary cardiac lymphoma: diagnosis and treatment. Report of 6 cases and review of the literature]. *Arch Mal Coeur Vaiss* 2005;98(9): 875-80.
- Quigley MM, Schwartzman E, Boswell PD, Christensen RL, Gleason LA, Sharpe RW, et al. A unique atrial primary cardiac lymphoma mimicking myxoma presenting with embolic stroke: a case report. *Blood* 2003;101(12):4708-10.
- Fowler NO. Tuberculous pericarditis. *JAMA* 1991;266(1):99-103.
- Light RW. Update on tuberculous pleural effusion. *Respirology* 2010;15(3):451-8.
- Elis A, Blickstein D, Mulchanov I, Manor Y, Radnay J, Shapiro H, et al. Pleural effusion in patients with non-Hodgkin's lymphoma: a case-controlled study. *Cancer* 1998;83(8):1607-11.