

# Atypical Virchow-Robin Spaces: Report of Seven Cases

## Atipik Virchow-Robin Mesafeleri: Yedi Adet Olgu Sunumu

Serhat AVCU, MD,<sup>a</sup>  
Refah SAYIN, MD,<sup>b</sup>  
Özkan ÜNAL, MD,<sup>a</sup>  
Etem Emre ÇÖĞEN, MD,<sup>b</sup>  
Temel TOMBUL, MD<sup>b</sup>

Departments of  
<sup>a</sup>Radiology,  
<sup>b</sup>Neurology,  
Yüzüncü Yıl University  
Faculty of Medicine, Van

Geliş Tarihi/Received: 22.05.2009  
Kabul Tarihi/Accepted: 15.02.2010

Yazışma Adresi/Correspondence:  
Serhat AVCU, MD  
Yüzüncü Yıl University  
Faculty of Medicine,  
Department of Radiology, Van,  
TÜRKİYE/TURKEY  
serhatavcu@hotmail.com

**ABSTRACT** The term “Virchow-Robin spaces” (VRS) refers to the extension of the subarachnoid space accompanying a vessel penetrating the cerebral cortex. In case of widening, they can be seen on magnetic resonance imaging as round, oval, or curvilinear well-defined cystic lesions with smooth margins, isointense to cerebrospinal fluid. Although dilated VRS are normal findings that may be seen at all ages, big and atypical forms are rare. Although they have associated mass effect, they should not be mistaken for neoplasm or other disease. We report seven patients whose ages were between 7 and 66 (mean: 35.8) years showing unilateral or bilateral cerebral intraparenchymal extensive cystic dilations corresponding to atypical VRS (two with Type-I and five with Type-II VRS), with clinical and radiological findings.

**Key Words:** Cerebrum; cerebrovascular disorders; magnetic resonance imaging

**ÖZET** “Virchow-Robin mesafeleri” (VRM) terimi subaraknoid mesafenin serebral korteksi penetre eden bir damara eşlik ederek uzamasıdır. Genişleme durumunda manyetik rezonans incelemede beyin omurilik sıvısı ile izointens yuvarlak, oval, veya kürvilineer iyi sınırlı ve düzgün konturlu kistik lezyonlar şeklinde görülürler. Genişlemiş VRM’ler her yaşta görülebilen normal bulgular olmakla birlikte büyük ve atipik formları nadirdir. Kendileri ile ilişkili kitle etkisine sahip olmalarına rağmen neoplazm veya diğer hastalıklarla karıştırılmamalıdır. Yaşları 7 ile 66 (ortalama: 35.8) arasında olan, atipik VRM’lere karşılık gelen tek veya çift taraflı belirgin serebral parankim içi kistik genişlemeler gösteren yedi adet (2 tanesi Tip-I, 5 tanesi Tip-II VRM) olguyu klinik ve radyolojik bulguları eşliğinde sunuyoruz.

**Anahtar Kelimeler:** Beyin; serebrovasküler bozukluklar; manyetik rezonans görüntüleme

**Türkiye Klinikleri J Med Sci 2010;30(6):2061-6**

**D**ilated perivascular spaces are known as Virchow-Robin spaces (VRS). Perivascular space is the elongation of the subarachnoid space around the penetrating arteries into the cerebral parenchyma which is covered by pia mater. VRS also cover the arteries and veins other than capillaries. They may be seen at all ages and are normal findings, however in case of aging and other situations resulting in brain atrophy they become more significant due to the dilatation of cerebrospinal fluid (CSF) spaces. They are typically found at the inferior 1/3<sup>rd</sup> of the basal ganglia and here they are called as “sublenticular cysts” as well. They may also be seen at centrum semiovale, thalamus, brainstem, and other areas of the brain. Dilated VRS typically occur in three characteristic locations. The first type (type I) is frequently seen on magnetic resonance (MR) images and appears

along the lenticulostriate arteries entering the basal ganglia through the anterior perforated substance. The second type (type II) can be found along the path of the perforating medullary arteries as they enter the cortical gray matter over the high convexities and extend into the white matter. The third type (type III) appears in the midbrain.<sup>1-6</sup>

Although dilated VRS are normal findings that may be seen at all ages, big and atypical forms are rare. Occasionally, VR spaces have an atypical appearance. They may become very large, predominantly involve one hemisphere, assume bizarre configurations, and even cause mass effect. Knowledge of the signal intensity characteristics and locations of VR spaces helps us to differentiate them from various pathologic conditions, including lacunar infarctions, cystic periventricular leukomalacia, multiple sclerosis, cryptococcosis, mucopolysaccharidoses, cystic neoplasms, neurocysticercosis, arachnoid cysts, and neuroepithelial cysts.<sup>1,7,8</sup> We report seven patients whose ages were between 7 and 66 (mean: 35.8) years whose MRI examinations revealed unilateral or bilateral cerebral intraparenchymal extensive cystic dilations corresponding to atypical VRS.

## CASE REPORTS

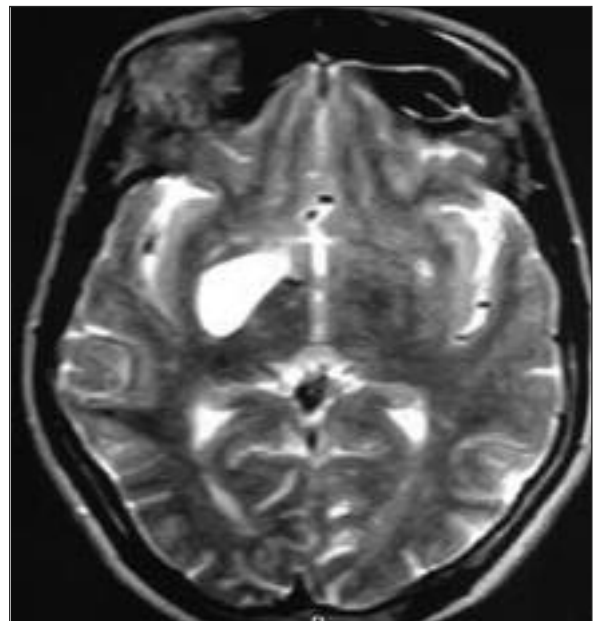
### CASE 1

Sixty-six-year-old woman was admitted to our hospital with the complaint of band-type tension headache for the past ten years. The patient was hypertensive and on antihypertensive medication for more than ten years. The neurological examination was normal. On cerebral MRI examination,

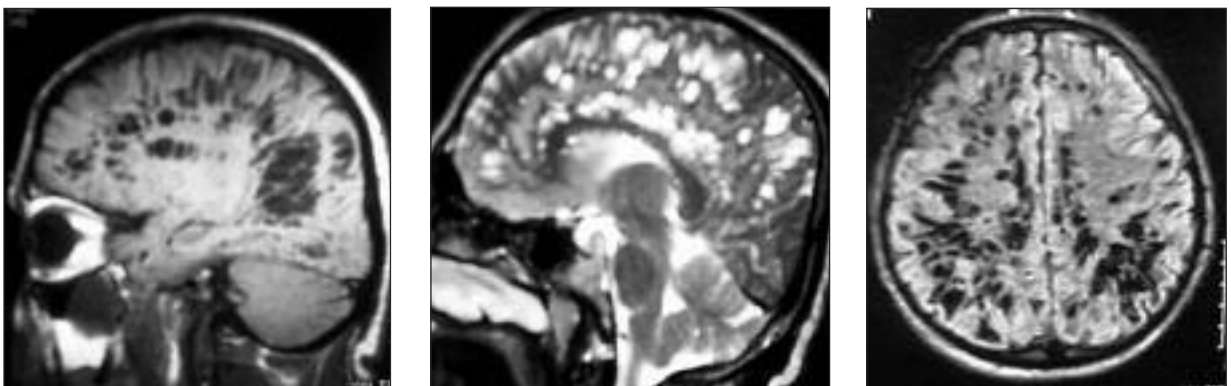
a Type-I VRS dilatation with a diameter of 3 centimeters was detected at the anteroinferior aspect of the right basal ganglia (Figure 1).

### CASE 2

Thirty-seven-years-old male patient applied to our hospital with severe headache for ten years. The systemic and neurological examinations were negative. On cerebral MRI examination, wide spread Type-II VRS dilatations were observed in bifrontal and biparietal regions and periventricular white matter that tend to conjoin (Figure 2).



**FIGURE 1:** On axial T2-weighted MR image, a Type I VRS dilatation with a diameter of 3 centimeters is seen at the anteroinferior aspect of the right basal ganglia.



**FIGURE 2:** Sagittal T1-weighted (a), T2-weighted (b), and axial FLAIR MR images showing wide-spread Type-II VRS dilatations in both cerebral hemispheres.

**CASE 3**

Forty-five year-old male applied to our clinic after falling down. The neurological examination of the patient was normal. On cerebral CT which was obtained to evaluate head trauma, cerebral hypodense areas were observed. On further evaluation with MRI, the hypodense regions on CT were interpreted as Type-II dilated VRS in callosal and cingulate gyrus localizations (Figure 3).

**CASE 4**

Seven-years-old male patient applied to our hospital with complaints of nausea, vomiting, otalgia and headache. The systemic and neurological examinations of the patient were normal. On cerebral MRI examination, bilateral Type-II periventricular VRS dilatations were detected (Figure 4).

**CASE 5**

Twenty-five-year-old male who had generalised tonic-clonic epileptic attacks twice a month for fifteen years was admitted to emergency room because of status epilepticus. Neurological examination revealed loss of consciousness and localized response to pain. On cerebral MRI, left hippocampal atrophy and neighbouring Type-II dilated VRS were observed (Figure 5).

**CASE 6**

Twenty-eight-year-old female was brought to our hospital with loss of consciousness after suicidal attempt by hanging. Neurological examination revealed hypotonia and akinetic mutism. There was no involuntary movement or seizure. On cerebral MRI

which was obtained with a presumptive diagnosis of hypoxic encephalopathy, an incidental Type-II atypical VRS dilatation with a size of 2 x 1 cm was observed at callosal-right pericallosal region (Figure 6).

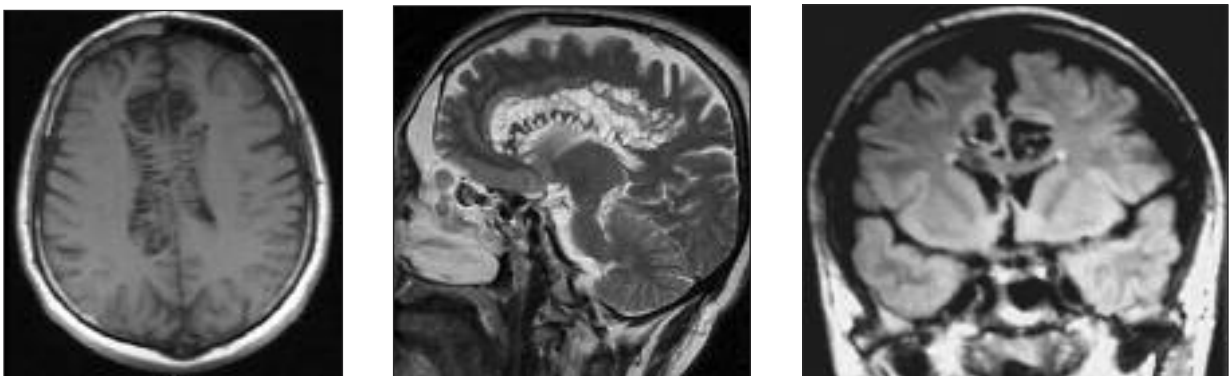
**CASE 7**

Forty-three-year-old male applied to our hospital with the complaint of headache. Patient history, laboratory and neurologic examinations were normal. Cerebral MRI revealed a 3.8 x 1.4 cm Type-I giant VRS dilatation in the left external capsule (Figure 7).

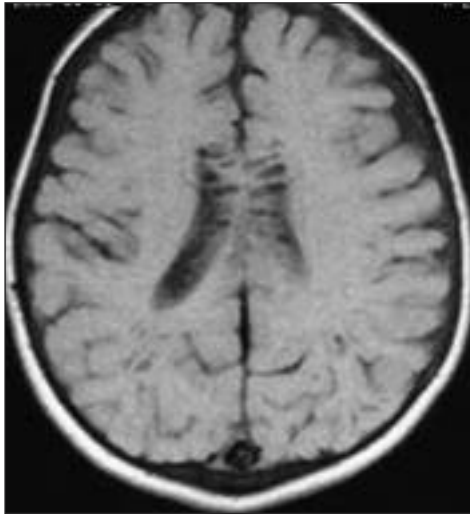
**DISCUSSION**

In a patient without any neurological deficit, multiple cavities in the white matter especially following the route of penetrating arteries with a signal intensity identical to CSF should remind VRS dilatations. VRS encircle the vessel walls throughout the brain parenchyma, and small VRS may be seen at all age groups. With the increase in age, VRS become bigger and more common. They are mostly located at the basal ganglia, white matter, and midbrain.<sup>1</sup>

VRS are seen on MR images as small foci that are isointense to CSF with all pulse sequences and conform to the path of penetrating arteries as they enter the brain from the subarachnoid space. T1-weighted, T2-weighted, and Fluid-Attenuated Inversion Recovery (FLAIR) sequences are routinely used on MR examinations. Recently, diffusion-weighted imaging is added into routine MR examinations in some centers, which has a value in the differentiation of abscesses from cysts, and epidermoid cysts from arachnoid cysts. Additionally, there are a few studi-



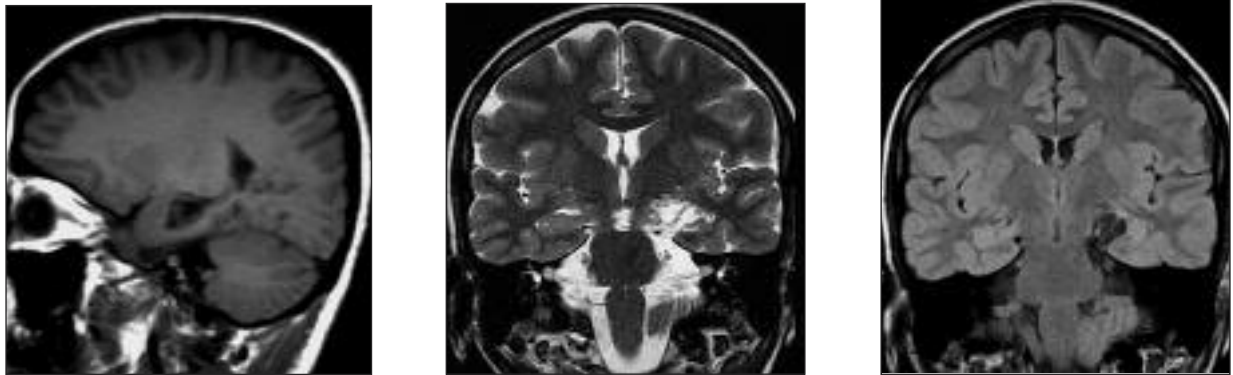
**FIGURE 3:** Axial T1-weighted (a), sagittal T2-weighted (b), and coronal FLAIR (c) MR images displaying bilateral supraventricular dilated Type-II VRS.



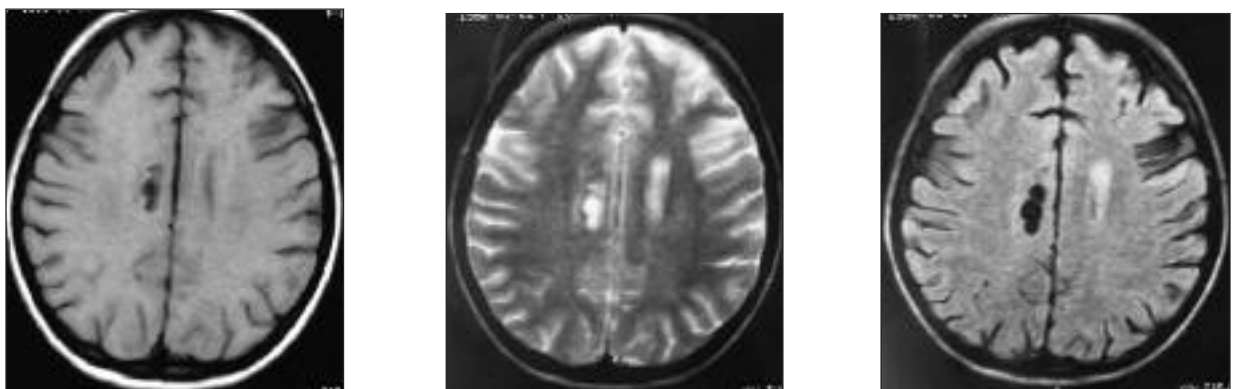
**FIGURE 4:** Bilateral periventricular Type-II VRS dilatations are seen on cerebral axial T1-weighted MR image.

es concerning the use of diffusion tensor MR imaging study with tractography and functional MRI (fMRI).<sup>6</sup> In a retrospective study of MR imaging, age, arterial

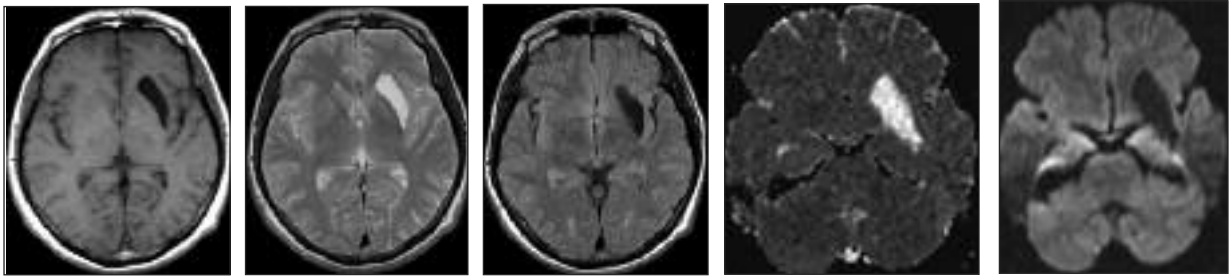
hypertension, dementia, and the incidental white matter lesions were found to be significantly associated with large VRS. Typically, they lack mass effect and are asymptomatic, however in some cases with expanding lacunae reported earlier, the perivascular spaces expanded more than usual, acting as space-occupying lesions.<sup>7</sup> FLAIR MR images should not show any signal-intensity abnormality in the adjacent white matter, but in some cases, hypersignals have been reported corresponding to gliosis.<sup>6</sup> The VRS in our cases did not show any perilesional signal increase on FLAIR images. Mathias et al. reported two patients with VRS who underwent a diffusion tensor MR imaging study with tractography and an fMRI after neuropsychological evaluation.<sup>6</sup> They claimed that fMRI showed no functional reorganization of cortical areas despite apparent extent of the lesions, and tractography showed an apparent decrease of white matter tract vectors into the regions of concern



**FIGURE 5:** Sagittal T1-weighted (a), Coronal T2-weighted (b), and coronal FLAIR (c) MR images showing left parahippocampal cortex atrophy and neighboring dilated Type-II VRS.



**FIGURE 6:** On axial T1-weighted (a), T2 weighted (b), and FLAIR(c) MR images, an atypical Type-II VRS dilatation 2x1 cm in size is seen at callosal-right pericallosal region.



**FIGURE 7:** On axial T1-weighted (a), T2 weighted (b), FLAIR (c), ADC (d), and diffusion-weighted (e) MR images, a 3.8 x 1.4 cm giant Type-I VRS dilatation is visualised in the left external capsule. The ADC value of the VRS was measured as  $3.03 \times 10^{-3} \text{ mm}^2/\text{sn}$ . VRS showed no restriction in diffusion.

compared to the healthy side. They suspected that this asymmetry between both sides corresponded to a technical limit of tractography rather than to a real decrease in the number of axons. The neuropsychological examination findings were normal in both patients, and these results were in agreement with the previous work in the literature. They stated that even giant and extensive white matter cystic dilations, which could correspond to dilation of VRS, did not deteriorate brain function.

Dilations of perivascular spaces, even if giant, are, in most cases, fortuitously discovered because they do not induce any clinical abnormality. However, some atypical presentations have been reported in the literature: Papayannis et al. described a patient who presented with a large cystic lesion of the midbrain inducing an acute obstructive hydrocephalus due to the compression of the aqueduct of Sylvius.<sup>7</sup> It is also reported in a study that some dilated perivascular spaces required surgical intervention to relieve mass effect or hydrocephalus.<sup>6</sup> In our cases however, the VRS caused no serious mass effect. Regarding differential diagnosis, we could exclude cystic lesions (ependymal cyst, neuroepithelial cyst, arachnoid cyst, ventricular diverticula, cystic infarction, and mucopolysaccharidosis) because in all these lesions, clinical symptoms or neurologic findings should often be present. In our study, six of the seven patients with atypical VRS had no significant neurological findings (Table 1). One of our patients was epileptic and presented with status epilepticus. VRS may be associated with microvascular disease, multiple sclerosis and traumatic brain injury. The differentiating point from other simulating lesions such as lacunar infarct may be the lack of hyperintense

signal around most of the VRS on FLAIR MR images that correspond to gliosis.<sup>8-11</sup>

It is stated that situations such as cerebral infarct, hypertension, and dementia are strongly associated with VRS, and thus, age is an important factor.<sup>2</sup> Three of our cases were above the age of 40, and four of them were below the age of 40, and thus we can say that the VRS in our cases were not strongly associated with increasing age.

Dilated VRS typically occur in three characteristic locations. The first type (type I) is frequently seen on MR images and appears along the lenticulostriate arteries entering the basal ganglia through the anterior perforated substance. The second type (type II) can be found along the path of the perforating medullary arteries as they enter the cortical gray matter over the high convexities and extend into the white matter. The third type (type III) appears in the midbrain. In the lower midbrain, VRS at the pontomesencephalic junction surround the penetrating branches of the collicular and accessory collicular arteries. They are mainly located between the cerebral peduncles in the axial plane and correspond to the level of the tentorial margin as seen in coronal sections. In the upper midbrain, where the VRS are visible at the mesencephalodiencephalic junction, they appear along the posterior thalamoperforating artery or the paramedian mesencephalothalamic artery and short and long circumferential arteries originating from the upper basillary artery or proximal posterior cerebral artery.<sup>1</sup> The atypically dilated VRS in our cases were corresponding to types 1 and 2 (Table 1).

It is reported that clusters of type II enlarged VRS may predominantly involve one hemisphere.

**TABLE 1:** Clinical and MR imaging findings of the cases with atypical VRS.

	Number of cases
Headache	4
Hypertension	1
Nausea and vomiting	1
Epilepsy	1
Suicidal attempt by hanging	1
Head trauma	1
Neurological finding	1
Type-I VRS	2
Type-II VRS	5

VRS: Virchow-Robin Space.

There are even reports that describe the solely unilateral appearance of enlarged VRS in the high convexity. Occasionally, VRS appear markedly enlarged, cause mass effect, and assume bizarre cystic configurations that may be misinterpreted as other pathologic processes, most often a cystic neoplasm. As most of these giant VRS border a ventricle or subarachnoid space, reports of such cases have offered an extensive differential diagnosis that includes cystic neoplasms, parasitic cysts, cystic infarctions, nonneoplastic neuroepithelial cysts, and deposition disorders such as mucopolysaccharidosis. Salzman et al. presented a series of 37 patients with giant VRS.<sup>12</sup> These spaces most often appear as clusters of

variably sized cysts and are most common in the mesencephalothalamic region, in the territory of the paramedial mesencephalothalamic artery, and in the cerebral white matter. Giant VRS in the mesencephalothalamic region may cause hydrocephalus by direct compression of the third ventricle or the sylvian aqueduct, requiring surgical intervention.<sup>1</sup> Giant VRS are expanded VRS that occur along the penetrating vessels, most commonly in the mesencephalothalamic region in the territory of the paramedial mesencephalothalamic artery and in the cerebral white matter. They differ from typical VRS in that they are larger in size and may have focal mass effect. In addition, white matter giant VRS may have associated T2 and FLAIR signal intensity alterations in the adjacent white matter. Giant VRS (up to 2-3 cm in diameter) have been reported to occur as a normal variant. The precise etiology of these enlarged VRS is unknown.<sup>12</sup>

In conclusion, incidental cystic lesions isointense with CSF corresponding to dilated VRS in cerebral white matter may be seen on MR images, and awareness of these lesions is important to consider them in the differential diagnosis of cerebral cystic lesions. Knowledge of their signal intensity characteristics and localization helps in differentiating them from different pathological conditions.

## REFERENCES

1. Kwee RM, Kwee TC. Virchow-Robin spaces at MR imaging. *Radiographics* 2007;27(4):1071-86.
2. Heier LA, Bauer CJ, Schwartz L, Zimmerman RD, Morgello S, Deck MD. Large Virchow-Robin spaces: MR-clinical correlation. *AJNR Am J Neuroradiol* 1989;10(5):929-36.
3. Marnet D, Noudel R, Peruzzi P, Bazin A, Bernard MH, Scherpereel B, et al. [Dilatation of Virchow-Robin perivascular spaces (types III cerebral lacunae): radio-clinical correlations]. *Rev Neurol (Paris)* 2007;163(5):561-71.
4. Coskun A, Karahan OI. [Incidental white matter hyperintensities in MR imagings of healthy subjects]. *Diagnostic and Interventional Radiology* 2002;8(3):330-4.
5. Braffman BH, Zimmerman RA, Trojanowski JQ, Gonatas NK, Hickey WF, Schlaepfer WW. Brain MR: pathologic correlation with gross and histopathology. 1. Lacunar infarction and Virchow-Robin spaces. *AJR Am J Roentgenol* 1988;151(3):551-8.
6. Mathias J, Koessler L, Brissart H, Foscolo S, Schmitt E, Bracard S, et al. Giant cystic widening of Virchow-Robin spaces: an anatomofunctional study. *AJNR Am J Neuroradiol* 2007;28(8):1523-5.
7. Papayannis CE, Saidon P, Rugilo CA, Hess D, Rodriguez G, Sica RE, et al. Expanding Virchow Robin spaces in the midbrain causing hydrocephalus. *AJNR Am J Neuroradiol* 2003;24(7):1399-403.
8. Ge Y, Law M, Herbert J, Grossman RI. Prominent perivenular spaces in multiple sclerosis as a sign of perivascular inflammation in primary demyelination. *AJNR Am J Neuroradiol* 2005;26(9):2316-9.
9. Inglese M, Bomsztyk E, Gonen O, Mannon LJ, Grossman RI, Rusinek H. Dilated perivascular spaces: hallmarks of mild traumatic brain injury. *AJNR Am J Neuroradiol* 2005;26(4):719-24.
10. Patankar TF, Mitra D, Varma A, Snowden J, Neary D, Jackson A. Dilatation of the Virchow-Robin space is a sensitive indicator of cerebral microvascular disease: study in elderly patients with dementia. *AJNR Am J Neuroradiol* 2005;26(6):1512-20.
11. Cumurciuc R, Guichard JP, Reizine D, Gray F, Bousser MG, Chabriat H. Dilation of Virchow-Robin spaces in CADASIL. *Eur J Neurol* 2006;13(2):187-90.
12. Salzman KL, Osborn AG, House P, Jinkins JR, Ditchfield A, Cooper JA, et al. Giant tumefactive perivascular spaces. *AJNR Am J Neuroradiol* 2005;26(2):298-305.