

# Comparison of Symptomatic and Asymptomatic Temporomandibular Joints in Unilateral Temporomandibular Joint Disorder: A Morphometric Study

## Tek Taraflı Temporomandibular Eklem Bozukluğunda Semptomatik ve Asemptomatik Temporomandibular Eklemi Karşılaştırılması: Morfometrik Bir Çalışma

Hasan CAMCI<sup>a</sup>, Ömer EKİCİ<sup>b</sup>

<sup>a</sup>Department of Orthodontics, Afyonkarahisar Health Sciences University Faculty of Dentistry, Afyonkarahisar, TÜRKİYE

<sup>b</sup>Department of Oral and Maxillofacial Surgery, Afyonkarahisar Health Sciences University Faculty of Dentistry, Afyonkarahisar, TÜRKİYE

**ABSTRACT Objective:** To compare healthy and affected joints of patients with the unilateral temporomandibular disorder (TMD) via morphometric measurements of radiographic images. **Material and Methods:** Forty-one patients aged 16 to 56 years were included in the research. All individuals had chronic unilateral TMD and at least one of the following symptoms had to be unilaterally present in patients: joint pain, joint sound or movement limitation. In order to evaluate a total of 82 temporomandibular joints, 3 angular and 3 linear measurements on orthopantomogram (OPG) and 2 angular and 12 linear measurements on lateral temporomandibular joints image (LTI) were performed. AudaxCeph Version 5.X orthodontic software was used for morphometric measurements. The findings were compared using Student's t-test and Mann-Whitney U test. **Results:** No significant difference was found between the healthy side and the affected side in all parameters of both OPG and LTI assessments ( $p>0.05$ ). **Conclusion:** In patients with unilateral TMD, the hard tissue characteristics of healthy and affected sides were similar.

**Keywords:** Temporomandibular joint disorders; morphometric analysis; orthopantomogram; lateral temporomandibular joints image

**ÖZET Amaç:** Radyografik görüntülerin morfometrik ölçümleriyle tek taraflı temporomandibular bozukluk (TMB) hastalarının sağlıklı ve etkilenmiş eklemlerini karşılaştırmak. **Gereç ve Yöntemler:** Araştırmaya 16-56 yaş arası 41 hasta dâhil edildi. Tüm bireyler kronik tek taraflı TMB'ye sahipti ve hastalarda aşağıdaki semptomlardan en az birinin tek taraflı olması gerekiyordu; eklem ağrısı, eklem sesi veya hareket kısıtlılığı. Toplamda 82 temporomandibular eklemi değerlendirmek için ortopantomogramda (OPG) 3 açı ve 3 uzunluk ölçümü ve lateral temporomandibular eklem görüntüsünde (LTG) 2 açı ve 12 uzunluk ölçümü yapıldı. Morfometrik ölçümler için AudaxCeph Version 5.X ortodontik yazılımı kullanıldı. Bulgular Student t-testi ve Mann-Whitney U testi kullanılarak karşılaştırıldı. **Bulgular:** Hem OPG hem de LTG değerlendirmelerinin tüm parametrelerinde sağlıklı taraf ile etkilenen taraf arasında anlamlı bir fark bulunmadı ( $p>0,05$ ). **Sonuç:** Tek taraflı TMB şikâyeti olan hastaların sert doku sagittal yön değerlendirmelerinde belirtilen özellikler sağlıklı ve etkilenen taraflarda benzerdi.

**Anahtar Kelimeler:** Temporomandibular eklem bozuklukları; morfometrik analiz; ortopantomogram; lateral temporomandibular eklem görüntüsü

The temporomandibular joint (TMJ) is one of the unique joints of the human body, both in terms of its anatomical structure and function.<sup>1</sup> TMJs are the most active joints in the human body because they perform an average of more than 2,000 movements per day by biting, speaking, swallowing, chewing.<sup>2</sup>

Temporomandibular joint disorders (TMDs) have multifactorial etiology.<sup>3</sup> It can be seen in a wide range of prevalence in different societies.<sup>4</sup> In the literature, there is no clear consensus on the predisposing and perpetuating factors associated with TMD.<sup>5</sup> Researchers have reported that many variables, including genetic and environmental factors (parafunc-

**Correspondence:** Hasan CAMCI

Department of Orthodontics, Afyonkarahisar Health Sciences University Faculty of Dentistry, Afyonkarahisar, TÜRKİYE/TÜRKİYE

E-mail: dt.hasan@hotmail.com



Peer review under responsibility of Türkiye Klinikleri Journal of Dental Sciences.

Received: 12 Jan 2021

Received in revised form: 24 Feb 2021

Accepted: 04 Mar 2021

Available online: 12 Mar 2021

2146-8966 / Copyright © 2022 by Türkiye Klinikleri. This is an open access article under the CC BY-NC-ND license (<http://creativecommons.org/licenses/by-nc-nd/4.0/>).

tional habits, malocclusions, local infections, premature contact, trauma, unilateral chewing, etc.) play a role in the development and progression of TMD.<sup>6</sup>

TMDs usually involve symptoms related to the TMJ and periarticular structures (bone, ligament, chewing muscle or retrodiscal tissue). Symptoms could be seen as pain, discomfort, mandibular dysfunction, or joint noise (clicking, snapping, or crepitus) on its own or in combination.<sup>7</sup> These disorders have a negative impact on the quality of life in all age groups, whether adults, adolescents, or children.<sup>8</sup> However, due to the high adaptive capacity of TMJ, TMD may develop and progress in some patients without symptoms.<sup>3</sup>

Etiological factors may affect the distribution of biomechanical forces in the condyle, leading to unilateral or bilateral morphological changes in the articular structure.<sup>9</sup> Condylar remodeling is an adaptive process that occurs to effectively meet the joint loads and maintain the function. This situation has been associated with the remodeling capacity (or ability to modify their morphology) of the TMJ components that are thought to continue for life.<sup>10</sup> Dupuy-Bonafe et al. suggested that morphological examinations play an important role in the detection of TMJ pathologies.<sup>11</sup> Reasonable morphometric measurements of TMJ components therefore enable us to better analyze the structure and function of the joint. The morphometric analysis has been performed using various types of image analysis techniques due to the complex TMJ anatomy. The morphological changes in the size and shape of the joint are being analyzed using magnetic resonance imaging (MRI), computed tomography (CT), cone-beam computed tomography (CBCT), orthopantomogram (OPG) or lateral temporomandibular joint image (LTI). (Figure 1).<sup>12</sup> The images are virtually or metrically evaluated in the sagittal plane for anatomical structures. OPG is routinely used in dentistry for diagnostic purposes. OPG and LTI are recommended methods for assessing major condyle changes in patients with TMD.<sup>13</sup>

The purpose of the present study was to compare the symptomatic and asymptomatic condyle morphology with morphometric measurements in patients with chronic unilateral TMD. The study also tested the null hypothesis that there was no morphological difference between healthy and affected condyles.

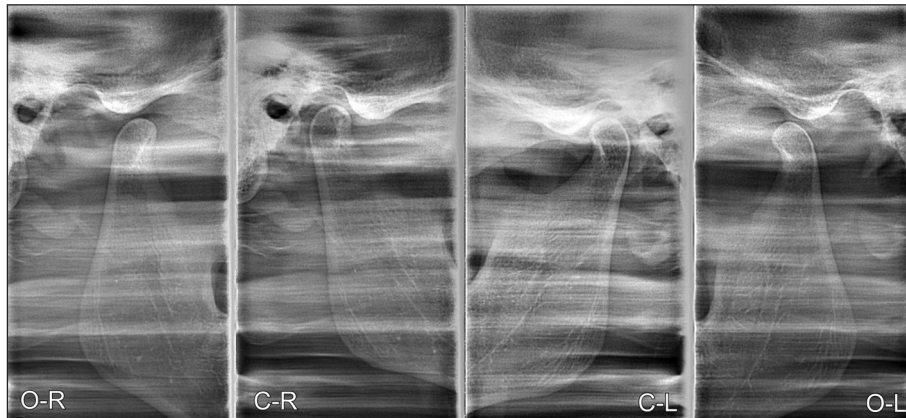
## MATERIAL AND METHODS

The approval of this retrospective cross-sectional study was provided by the local ethics committee (Afyonkarahisar Health Sciences University Clinical Research Ethics Committee, 11.09.20-393). This research has been conducted in accordance with the Declaration of Helsinki Principles. Informed consent forms were obtained from all patients included in the study. G Power software was used in the calculation of sample sizes and it was revealed that at least 41 patients ( $\alpha=0.05$ , and  $1-\beta=0.80$ ) were required.

Individuals with predominant symptoms of chronic unilateral TMJ pain and dysfunction were selected retrospectively from a pool of previously differentiated patient groups. At least one of the following symptoms had to be unilaterally present in patients: joint pain, joint sound or movement limitation. Only patients whose radiographic images provided well-defined contours were included in the study. Exclusion criteria were bilateral TMD, physical disability, neuromuscular disorders, TMJ malignancies, hypermobile condyles, signs of osteoarthritis, acute joint pain or restriction, direct trauma or bone facial fracture, low radiographic image quality. All patients were examined by the same maxillofacial surgeon in accordance with the Research Diagnostic Criteria/TMD criteria.<sup>14</sup> Findings of the examination and detailed information on individual anamnesis were recorded. OPG and LTI images of the patients were used for visual and metric evaluation. The final sample size consisted of eighty-two joints.

## MEASUREMENTS

Morphological features of intracapsular hard tissues of TMJ (condyle, glenoid fossa, articular eminence size and shape, joint space dimensions, etc) were compared for symptomatic and asymptomatic sides. In addition, mandibular ramus length, corpus length, and gonial angles were evaluated on OPG. Audax-Ceph Version 5.X orthodontic software was used for morphometric measurements. On the OPG, 6 points and 4 planes were defined, and then 3 angular and 3 linear measurements were performed (Figure 2).<sup>15</sup> On the LTI (in closed-mouth position), 22 points and 3 planes were defined, and then 2 angular and 12 linear



**FIGURE 1:** Lateral temporomandibular joint image. **O-R:** Right temporomandibular joint in open-mouth position. **C-R:** Right temporomandibular joint in closed-mouth position, **C-L:** Left temporomandibular joint in closed-mouth position. **O-L:** Left temporomandibular joint in open mouth position.

parameters were measured (Figure 3).<sup>16</sup> Both right and left condyles were assessed in all measurements by the same researcher.

#### EXAMINATION CARDS

Specially designed examination cards for patients with TMD are routinely used in our clinics. Symptoms and complaints of the patients were recorded following a detailed clinical examination (both TMJ and dentition) performed by the same clinician. The cards also included parameters such as age, gender, complaint duration, body mass index, visual analog scale, maximum mouth opening, maximum assisted opening and the presence of joint sounds.

#### STATISTICAL ANALYSIS

All analyzes were performed with a package SPSS 22.0 (SPSS Inc, Chicago, Ill) program. Shapiro-Wilk test was used to test the homogeneity of the data. Symptomatic and asymptomatic TMJ data were compared using Student t-test and Mann-Whitney U test. All measurements were performed in 10 randomly selected patients for the second time after 15 days and the intra-correlation coefficient was analyzed to detect the variability of intra-examiner. High coefficient of repeatability was found for each measurement ( $\alpha > 875$ ). Results were considered statistically significant at  $p < 0.05$  significant level.

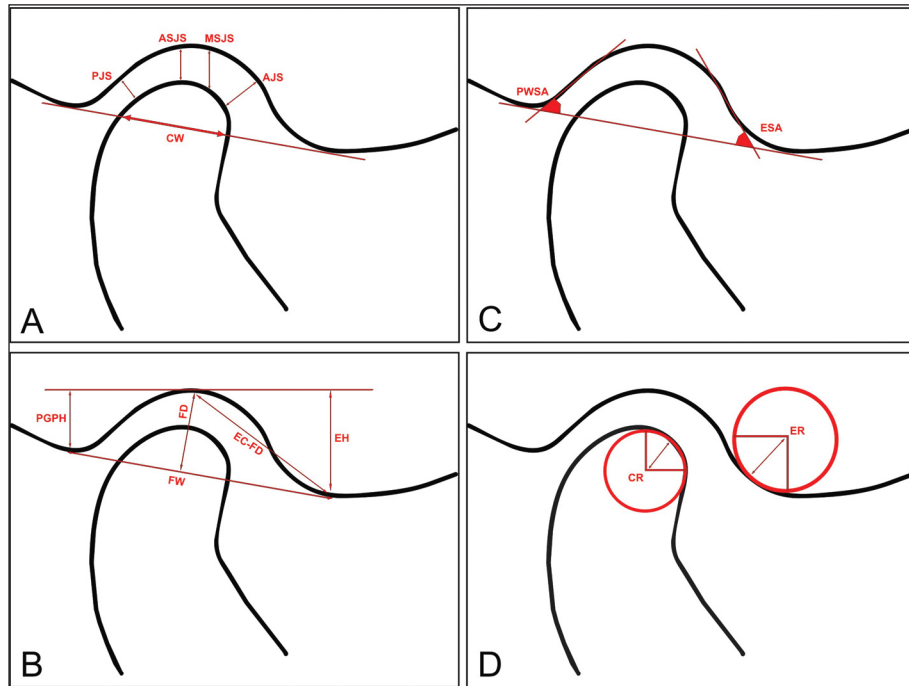
#### RESULTS

Descriptive statistical results of the demographic data and clinical findings of the patients were shown

in Table 1. A total of 82 TMJs of 35 female and 6 male patients (age range: 16-56) with an average age of 29.1 years were evaluated. The mean duration of complaints of the patients was  $3.4 \pm 3.2$  years (range: 1-13). A significant correlation was observed between age and duration of complaints. There was, however, no correlation between age or duration of complaints and other clinical findings (Table 2). In LTI measurements, no statistically significant difference was found between symptomatic and asymptomatic joints in all parameters such as joint space, condyle tract inclination, fossa width, fossa depth, eminence height, etc. ( $p > 0.05$ ). Similarly, there was no significant difference between the groups in any of the parameters measured on OPG (condyle height, condyle slope, mandibular body length, ramus slope and length, etc.) ( $p > 0.05$ ). Comparison results of parametric data were shown in Table 3 and nonparametric data were shown in Table 4. The results of correlation test between radiographic measurements and, age and duration of complaints were given in Table 5. According to the results, only the condylar height (sigmoid-condylion) was correlated with age ( $p = 0.22$ ) and anterior joint space (AJS) was correlated with the duration of complaint ( $p = 0.009$ ).

#### DISCUSSION

The most irritating symptom of TMD, affecting a significant part of societies, is pain.<sup>17</sup> Patients seek treatment due to pain that occurs during function and/or rest, and pain reduction is the primary goal of

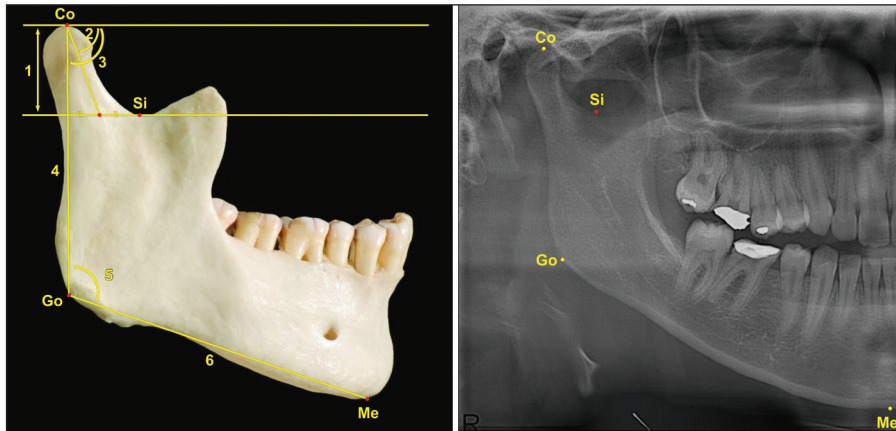


**FIGURE 2:** **A)** Posterior joint space and anterior joint space were measured as smallest distance between anterior condyle and posterior condyle and fossa. Absolute superior joint space was measured as vertical distance between highest point of condyle to fossa, and maximum superior joint space was measured as vertical distance between highest point of fossa to condyle. Condyle width was dimension between anterior and posterior condyle outline along tangent drawn between most inferior point of eminence and postglenoid process. **B)** Fossa width was distance between most inferior point of eminence and postglenoid process. Fossa depth was distance between highest point of fossa and point at which connecting line met fossa width tangent at right angle. Eminence height was distance between eminence crest and line drawn as horizontal tangent to highest point of fossa. Similarly, postglenoid process height was distance between deepest point of postglenoid process and line drawn as horizontal tangent to highest point of fossa. Distance between eminence crest and highest point of fossa was recorded. **C)** Angles between tangent connecting eminence crest with deepest point on postglenoid process and tangent of posterior eminence as well as tangent of anterior postglenoid process were recorded. **D)** Eminence radius was recorded as radius of circle fitted to 6 to 9 o'clock position of eminence. Condyle radius was recorded as radius of circle fitted to 12 to 3 o'clock position of condyle.

treatment. Many environmental or genetic factors have a role in the development of TMD.<sup>18</sup> TMJ disorders are responsible for progressive internal irregularities. Asymmetrical or excessive loads on the joint surfaces lead to regressive condylar remodeling in TMJ hard tissues. A macroscopic reduction in condyle size can be seen in the TMJ radiographic examination. Remodeling, which is an adaptation mechanism, can also lead to thickening or resorption in certain areas and therefore to condyle asymmetry. While the morphological change continues without symptoms to the threshold of adaptation, the symptoms appear when the ability to adapt is exceeded.

In previous studies, morphological variations in condyle shape and TMJ structures have been observed.<sup>19</sup> Differences in TMJ morphology exist for a variety of reasons, such as age, gender, type of face,

functional loads, occlusal forces, type of malocclusion. The most dramatic morphological variation (bony surface erosion, concavity, spurring, flattening, etc.) is observed in the elderly due to the onset of joint degeneration. Previously, the accuracy of the different radiographic imaging techniques were compared for the detection of changes in TMJ. Numerous joint morphology studies have been conducted using MRI, CT, CBCT, OPG, or LTI.<sup>19</sup> Since TMJ is a complex structure that includes hard and soft tissues, MRI is the only imaging technique that can evaluate both soft and hard tissues.<sup>20</sup> MRI is therefore widely used to analyze internal derangement of TMJ. However, it is known that MRI is insufficient for morphological evaluation of hard tissue.<sup>21</sup> In addition, the availability of MRI is limited, and the image acquisition time is long. Previous studies have reported that tomograms play a valuable role in the



**FIGURE 3:** Condylion: Highest point of condyle; Go: Gonion; Me: Menton. 1. condylar height; 2. condylar anterior posterior inclination (Angle 2); 3. ramal anteriorposterior inclination (Angle 3); 4. ramal length; 5. gonial angle; 6 mandibular body length.

assessment of existing bone changes in individuals with TMD.<sup>22,23</sup> In the present study, all measurements were evaluated on OPG and LTI. Since OPG and LTI are simple, low-cost, and cause small doses of radiation, it is one of the most widely used imaging techniques by dentists and dental professionals to evaluate the bone structure of TMJ. Similar to the present study, OPG and LTI were used in previous TMD studies for morphometric measurements.<sup>24</sup>

Some researchers have discussed the reliability of OPG images in morphometric measurements.<sup>25</sup> Although the accuracy of OPG in horizontal measurements is controversial due to the distortion of images, angular measurements have been claimed to be safe.<sup>26</sup> Many researchers suggest that panoramic radiographs are suitable for the measurement of mandibular vertical symmetry, ramus, and condyle vertical dimensions.<sup>27,28</sup> In the present study, high-

**TABLE 1:** Descriptive statistics of the patients.

Demographic values			
	Groups	n	Percentage (%)
Gender	Male	5	12
	Female	36	88
Age	16-26	20	50
	27-36	7	17
	37-46	9	22
	47-56	5	11
Clinical findings			
	Mean values	Standard Deviations	Minimum-Maximum
Duration of complaint (years)	3.4	3.2	1-13
Body mass index (kg/m <sup>2</sup> )	24.5	4.5	17.2-35.1
VAS scores	6	2.2	2-10
Maximum mouth opening (mm)	33.9	8.4	11-50
Maximum assisted opening (mm)	37.0	8.4	15-52
TMJ sounds			
	n	Percentage (%)	
Clicking	25	61	
Reciprocal clicking	8	19.5	
Crepitation	14	34	

TMJ: Temporomandibular joint; VAS: Visual analog scale for pain.



**TABLE 2:** Correlation test results related to clinical findings.

	Duration of complaint	Clicking	Reciprocal clicking	Crepitation	VAS scores	Maximum mouth opening	Age
<b>Duration of complaint</b>							
Coefficient	1.000	-0.120	-0.030	0.211	0.034	0.268	0.430**
Sig. (2-tailed)	.	0.465	0.857	0.198	0.835	0.099	0.006
<b>Age</b>							
Coefficient	0.430**	0.143	-0.141	0.081	0.124	0.102	1.000
Sig. (2-tailed)	0.006	0.386	0.391	0.625	0.451	0.536	.

VAS: visual analog scale; \*\*Correlation is significant at the 0.01 level (2-tailed); \*Correlation is significant at the 0.05 level (2-tailed).

quality OPG and LTI images were selected to reduce the error rate. However, in an *in vitro* study by Türp et al., there was a low correlation between condyle and ramus length physical measurements and OPG measurements.<sup>29</sup> The researchers correlated this phenomenon with the unavoidable distortion effect of OPG images induced by the device’s rotational movement.

There are a number of studies assessing degenerative changes that occur over time in hard and soft tissues using various imaging techniques. In the MRI examination of Zhuo et al., there was a 0.41 mm decrease in condyle height on the affected side in juvenile patients and an increase of 0.75 mm on the healthy side.<sup>30</sup> Takayama et al. suggested that osseous changes in patients with and without TMD

were minimal and not statistically significant.<sup>31</sup> In the present study, symptomatic and asymptomatic TMJ structures were compared by making a radiological examination in the sagittal plane (lateral view). However, in the study of Kurita et al., it was emphasized that the morphological change on the joint surface was in the mediolateral (ML) direction, not in the anteriorposterior (AP) direction.<sup>32</sup> Similarly, in a 30-year follow-up study by Leeuw et al., it was reported that the condyle size in TMD patients had decreased in ML dimension, but there was no change in AP size.<sup>33</sup> They also observed that osteoarthritis and internal derangement had developed asymptotically even on contralateral TMJ. The reason for the lack of differences between the groups in the present study may be related to this

**TABLE 3:** Student t-test results.

	Groups	Mean	SD	p value
Si-Co (mm)	Stmj	17.79	3.6	0.299
	Htmj	16.95	3.6	
Angle 3 (°)	Stmj	83.33	5.0	0.619
	Htmj	82.68	6.7	
AJS (mm)	Stmj	3.21	1.4	0.529
	Htmj	3.42	1.5	
FW (mm)	Stmj	20.76	3.0	0.117
	Htmj	21.77	2.7	
CW (mm)	Stmj	8.77	1.6	0.726
	Htmj	8.91	1.9	
PWSA (°)	Stmj	51.02	14.5	0.917
	Htmj	50.74	9.2	
ESA (°)	Stmj	54.32	12.4	0.068
	Htmj	49.08	13.5	

Stmj: Symptomatic temporomandibular joint; Htmj: Healthy temporomandibular joint; Si-Co: Condylar height; Angle 3: Ramal anteriorposterior inclination; AJS: Anterior joint space; FW: Fossa width; CW: Condyle width; PWSA: Posterior wall slope angle; ESA: Eminence slope angle; p<0.05 is statistically significant.

TABLE 4: Mann-Whitney U test results.

	Groups	Mean	SD	p value
Gonial Angle (°)	Stmj	112.28	9.0	0.256
	Htmj	114.58	6.1	
Co-Go (mm)	Stmj	59.53	10.0	0.975
	Htmj	59.31	10.6	
Go-Me (mm)	Stmj	97.27	14.6	0.691
	Htmj	95.37	16.2	
Angle 2 (°)	Stmj	74.07	4.9	0.579
	Htmj	73.17	9.4	
PJS (mm)	Stmj	3.44	1.8	0.502
	Htmj	3.58	1.9	
ASJS (mm)	Stmj	3.95	1.6	0.929
	Htmj	3.90	1.8	
MSJS (mm)	Stmj	4.91	1.5	0.439
	Htmj	5.27	1.8	
PGPH (mm)	Stmj	8.37	2.6	0.239
	Htmj	8.02	3.7	
EH (mm)	Stmj	10.34	2.9	0.632
	Htmj	10.55	2.4	
FD (mm)	Stmj	9.23	2.1	0.558
	Htmj	9.03	2.3	
EC-FD (mm)	Stmj	14.98	2.3	0.751
	Htmj	15.23	2.5	
CR (mm)	Stmj	4.85	1.0	0.329
	Htmj	5.02	0.8	
ER (mm)	Stmj	7.36	1.3	0.241
	Htmj	7.17	1.5	

Stmj: Symptomatic temporomandibular joint; Htmj: Healthy temporomandibular joint, Co-Go: ramal length, Go-Me: Mandibular body length; Angle 2: Condylar anterior posterior inclination; PJS: Posterior joint space; ASJS: Absolute superior joint space; MSJS: Maximum superior joint space; PGPH: Postglenoid process height; EH: Eminence height; FD: Fossa depth; EC-FD: Distance between eminence crest and highest point of fossa; CR: Condyle radius; ER: Eminence radius; p<0.05 is statistically significant.

situation. Similar to the findings of the present study, no correlation between TMD and radiographic changes in condylar morphology was observed in a cross-sectional study conducted by Mathew et al.<sup>34</sup> On the other hand, the fact that the reduction in the size of the condyle is seen only in the advanced stages of the internal derangement may be another reason why healthy and affected sides were similar in our study. Because, in this present cross-sectional study, patients' ages, gender and duration of the complaints were not homogeneously distributed. This was a limitation of the current study. However, the correlation test results revealed that there was only a correlation between

only two radiographic parameters (Si-Co and AJS) and, duration of complaints and age. We considered that the positive correlation between Si-Co length and age was linked to the lifelong bone remodeling suggested by Boskey and Coleman.<sup>35</sup> Degenerative changes caused by TMD could be the reason for the positive correlation between AJS and duration of complaint.

Further studies with more samples in specific patient groups are needed to assess the degenerative changes caused by TMD in hard tissues. This will allow us to better analyze the morphological effects of unilateral TMD symptoms.

**TABLE 5:** Results of correlation test between radiographic measurements and, age and duration of complaints.

	Correlation coefficient	
	Age	Duration of complaint
Si-Co (mm)	0.367*	0.012
Gonial Angle (°)	0.091	0.092
Co-Go (mm)	0.115	-0.135
Go-Me (mm)	0.006	-0.223
Angle 3 (°)	0.084	0.014
Angle 2 (°)	0.205	0.208
PJS (mm)	0.084	0.213
ASJS (mm)	-0.128	0.034
MSJS (mm)	0.138	0.225
AJS (mm)	0.126	0.415**
FW (mm)	-0.080	0.076
CW (mm)	-0.121	-0.162
PWSA (°)	-0.258	-0.135
ESA (°)	0.156	0.028
PGPH (mm)	-0.092	0.023
EH (mm)	-0.071	-0.136
FD (mm)	-0.052	-0.024
EC-FD (mm)	-0.302	-0.184
CR (mm)	0.057	-0.057
ER (mm)	0.058	0.195

Si-Co: Condylar height; Co-Go: Ramal length; Go-Me: Mandibular body length; Angle 3: Ramal anteriorposterior inclination; Angle 2: Condylar anterior posterior inclination; PJS: Posterior joint space; ASJS: Absolute superior joint space; MSJS: Maximum superior joint space; AJS: Anterior joint space; FW: Fossa width; CW: Condyle width; PWSA: Posterior wall slope angle; ESA: Eminence slope angle; PGPH: Postglenoid process height; EH: Eminence height; FD: Fossa depth; EC-FD: Distance between eminence crest and highest point of fossa; CR: Condyle radius; ER: Eminence radius; \*\*Correlation is significant at the 0.01 level; \*Correlation is significant at the 0.05 level.

## CONCLUSION

In patients with unilateral TMD, the hard tissue characteristics of healthy and affected sides were similar.

If the symptom is unilateral, it does not mean that there is no degeneration of the contralateral side.

### Source of Finance

During this study, no financial or spiritual support was received neither from any pharmaceutical company that has a direct connection with the research subject, nor from a company that provides or produces medical instruments and materials which may negatively affect the evaluation process of this study.

### Conflict of Interest

No conflicts of interest between the authors and / or family members of the scientific and medical committee members or members of the potential conflicts of interest, counseling, expertise, working conditions, share holding and similar situations in any firm.

### Authorship Contributions

**Idea/Concept:** Hasan Camcı, Ömer Ekici; **Design:** Hasan Camcı, Ömer Ekici; **Control/Supervision:** Hasan Camcı, Ömer Ekici; **Data Collection and/or Processing:** Hasan Camcı, Ömer Ekici; **Analysis and/or Interpretation:** Hasan Camcı, Ömer Ekici; **Literature Review:** Hasan Camcı; **Writing the Article:** Hasan Camcı; **Critical Review:** Hasan Camcı, Ömer Ekici; **References and Fundings:** Hasan Camcı, Ömer Ekici; **Materials:** Hasan Camcı, Ömer Ekici.

## REFERENCES

- Dellavia C, Rodella LF, Pellicchia R, Barzani G. Detailed anatomy of the temporomandibular joint. In: Connelly ST, Tartaglia GM, Silva RG, eds. Contemporary Management of Temporomandibular Disorders. 1st ed. Switzerland: Springer International Publishing; 2019. p.51-70. [Crossref]
- Mahdian N, Dostálová T, Daněk J, Nedoma J, Kohout J, Hubáček M, et al. 3D reconstruction of TMJ after resection of the cyst and the stress-strain analyses. Comput Methods Programs Biomed. 2013;110(3):279-89. [Crossref] [PubMed]
- Tanaka E, Detamore MS, Mercuri LG. Degenerative disorders of the temporomandibular joint: etiology, diagnosis, and treatment. J Dent Res. 2008;87(4):296-307. [Crossref] [PubMed]
- Troeltzsch M, Troeltzsch M, Cronin RJ, Brodine AH, Frankenberger R, Messlinger K. Prevalence and association of headaches, temporomandibular joint disorders, and occlusal interferences. J Prosthet Dent. 2011;105(6):410-7. [Crossref] [PubMed]
- Melis M, Di Giosia M. The role of genetic factors in the etiology of temporomandibular disorders: a review. Cranio. 2016;34(1):43-51. [Crossref] [PubMed]
- Bevilaqua-Grossi D, Chaves TC, de Oliveira AS. Cervical spine signs and symptoms: perpetuating rather than predisposing factors for temporomandibular disorders in women. J Appl Oral Sci. 2007;15(4):259-64. [Crossref] [PubMed] [PMC]
- Matsubara R, Yanagi Y, Oki K, Hisatomi M, Santos KC, Bangbose BO, et al. Assessment of MRI findings and clinical symptoms in patients with temporomandibular joint disorders. Dentomaxillofac Radiol. 2018;47(4):20170412. [Crossref] [PubMed] [PMC]
- Barbosa Tde S, Miyakoda LS, Poczaruk Rde L, Rocha CP, Gavião MB. Temporomandibular disorders and bruxism in childhood and adolescence: review of the literature. Int J Pediatr Otorhinolaryngol. 2008;72(3):299-314. [Crossref] [PubMed]



9. Lalue-Sanches M, Gonzaga AR, Guimaraes AS, Ribeiro EC. Disc displacement with reduction of the temporomandibular joint: the real need for treatment. *J Pain Reli.* 2015;4(5):1-5. [[Crossref](#)]
10. Hegde V. A review of the disorders of the temporomandibular joint. *The Journal of Indian Prosthodontic Society.* 2005;5(2):56-61. [[Link](#)]
11. Dupuy-Bonafé I, Otal P, Montal S, Bonafé A, Maldonado IL. Biometry of the temporomandibular joint using computerized tomography. *Surg Radiol Anat.* 2014;36(9):933-9. [[Crossref](#)] [[PubMed](#)]
12. Coombs MC, Bonthius DJ, Nie X, Lecholop MK, Steed MB, Yao H. Effect of measurement technique on TMJ mandibular condyle and articular disc morphometry: CBCT, MRI, and physical measurements. *J Oral Maxillofac Surg.* 2019;77(1):42-53. [[Crossref](#)] [[PubMed](#)] [[PMC](#)]
13. Crow HC, Parks E, Campbell JH, Stucki DS, Daggy J. The utility of panoramic radiography in temporomandibular joint assessment. *Dentomaxillofac Radiol.* 2005;34(2):91-5. [[Crossref](#)] [[PubMed](#)]
14. Anderson GC, Gonzalez YM, Ohrbach R, Truelove EL, Sommers E, Look JO, et al. The research diagnostic criteria for temporomandibular disorders. VI: future directions. *J Orofac Pain.* 2010;24(1):79-88. [[PubMed](#)] [[PMC](#)]
15. Kjellberg H, Ekestubbe A, Kiliaridis S, Thilander B. Condylar height on panoramic radiographs. A methodologic study with a clinical application. *Acta Odontol Scand.* 1994;52(1):43-50. [[Crossref](#)] [[PubMed](#)]
16. Pullinger AG, Seligman DA. Multifactorial analysis of differences in temporomandibular joint hard tissue anatomic relationships between disk displacement with and without reduction in women. *J Prosthet Dent.* 2001;86(4):407-19. [[Crossref](#)] [[PubMed](#)]
17. Chantaracherd P, John MT, Hodges JS, Schiffman EL. Temporomandibular joint disorders' impact on pain, function, and disability. *J Dent Res.* 2015;94(3 Suppl):79S-86S. [[Crossref](#)] [[PubMed](#)] [[PMC](#)]
18. Slade GD, Diatchenko L, Ohrbach R, Maixner W. Orthodontic treatment, genetic factors and risk of temporomandibular disorder. *Semin Orthod.* 2008;14(2):146-56. [[Crossref](#)] [[PubMed](#)] [[PMC](#)]
19. Hegde S, Bn P, Shetty SR. Morphological and radiological variations of mandibular condyles in health and diseases: a systematic review. *Dentistry.* 2013;3(1):1-5. [[Link](#)]
20. Vieira-Queiroz I, Gomes Torres MG, de Oliveira-Santos C, Flores Campos PS, Crusoé-Rebello IM. Biometric parameters of the temporomandibular joint and association with disc displacement and pain: a magnetic resonance imaging study. *Int J Oral Maxillofac Surg.* 2013;42(6):765-70. [[Crossref](#)] [[PubMed](#)]
21. Hansson LG, Westesson PL, Eriksson L. Comparison of tomography and midfield magnetic resonance imaging for osseous changes of the temporomandibular joint. *Oral Surg Oral Med Oral Pathol Oral Radiol Endod.* 1996;82(6):698-703. [[Crossref](#)] [[PubMed](#)]
22. Pullinger AG, White SC. Efficacy of TMJ radiographs in terms of expected versus actual findings. *Oral Surg Oral Med Oral Pathol Oral Radiol Endod.* 1995;79(3):367-74. [[Crossref](#)] [[PubMed](#)]
23. White SC, Pullinger AG. Impact of TMJ radiographs on clinician decision making. *Oral Surg Oral Med Oral Pathol Oral Radiol Endod.* 1995;79(3):375-81. [[Crossref](#)] [[PubMed](#)]
24. Joo JK, Lim YJ, Kwon HB, Ahn SJ. Panoramic radiographic evaluation of the mandibular morphological changes in elderly dentate and edentulous subjects. *Acta Odontol Scand.* 2013;71(2):357-62. [[Crossref](#)] [[PubMed](#)]
25. Kaya D. Is there any difference between gonial angle values measured on digital lateral cephalograms and orthopantomograms? *Turkish J Orthod.* 2020;1;33(2):72-6. [[Crossref](#)] [[PubMed](#)] [[PMC](#)]
26. Larheim TA, Svanaes DB. Reproducibility of rotational panoramic radiography: mandibular linear dimensions and angles. *Am J Orthod Dentofacial Orthop.* 1986;90(1):45-51. [[Crossref](#)] [[PubMed](#)]
27. Mattila K, Altonen M, Haavikko K. Determination of the gonial angle from the orthopantomogram. *Angle Orthod.* 1977;47(2):107-10. [[PubMed](#)]
28. Xie QF, Ainamo A. Correlation of gonial angle size with cortical thickness, height of the mandibular residual body, and duration of edentulism. *J Prosthet Dent.* 2004;91(5):477-82. [[Crossref](#)] [[PubMed](#)]
29. Türp JC, Vach W, Harbich K, Alt KW, Strub JR. Determining mandibular condyle and ramus height with the help of an Orthopantomogram—a valid method? *J Oral Rehabil.* 1996;23(6):395-400. [[Crossref](#)] [[PubMed](#)]
30. Zhuo Z, Cai X, Xie Q. Is anterior disc displacement without reduction associated with temporomandibular joint condylar height in juvenile patients younger than 20 years? *J Oral Maxillofac Surg.* 2015;73(5):843-9. [[Crossref](#)] [[PubMed](#)]
31. Takayama Y, Miura E, Yuasa M, Kobayashi K, Hosoi T. Comparison of occlusal condition and prevalence of bone change in the condyle of patients with and without temporomandibular disorders. *Oral Surg Oral Med Oral Pathol Oral Radiol Endod.* 2008;105(1):104-12. [[Crossref](#)] [[PubMed](#)]
32. Kurita H, Koike T, Narikawa J, Nakatsuka A, Kobayashi H, Kurashina K. Relationship between alteration of horizontal size and bony morphological change in the mandibular condyle. *Dentomaxillofac Radiol.* 2003;32(6):355-8. [[Crossref](#)] [[PubMed](#)]
33. de Leeuw R, Boering G, van der Kuijl B, Stegenga B. Hard and soft tissue imaging of the temporomandibular joint 30 years after diagnosis of osteoarthritis and internal derangement. *J Oral Maxillofac Surg.* 1996;54(11):1270-80; discussion 1280-1. [[Crossref](#)] [[PubMed](#)]
34. Mathew AL, Sholapurkar AA, Pai KM. Condylar changes and its association with age, TMD, and dentition status: a cross-sectional study. *Int J Dent.* 2011;2011:413639. [[Crossref](#)] [[PubMed](#)] [[PMC](#)]
35. Boskey AL, Coleman R. Aging and bone. *J Dent Res.* 2010;89(12):1333-48. [[Crossref](#)] [[PubMed](#)] [[PMC](#)]