

Primary Peritoneal Serous Borderline Tumour Associated with Behçet's Disease: A Rare Case Report

Behçet Hastalığı ile Birlikte Görülen Primer Peritoneal Seröz Borderline Tümör: Nadir Bir Olgu Sunumu

Engin KORKMAZER,^a
Sare KABUKÇUOĞLU^b

^aDepartment of Gynecology and Obstetrics,
Giresun University Faculty of Medicine,
Giresun

^bDepartment of Pathology,
Eskişehir Osmangazi University
Faculty of Medicine, Eskişehir

Geliş Tarihi/Received: 26.12.2013
Kabul Tarihi/Accepted: 21.12.2014

Yazışma Adresi/Correspondence:

Engin KORKMAZER
Giresun University Faculty of Medicine,
Department of Gynecology and Obstetrics,
Giresun,
TÜRKİYE/TURKEY
ekorkmazer@yahoo.com

ABSTRACT Primary peritoneal serous borderline tumour is a rare epithelial proliferation can mostly present as an incidental finding at laparotomy. The risk factors for developing these tumours are not well known. Nulliparity and drugs used in infertility treatment appear to increase the risk, while oral contraceptives seem to have a protective effect. For the differential diagnosis, mesothelial proliferation, endosalpingiosis, endometriosis, high-grade primary papillary serous carcinoma and implants from primary ovarian serous carcinoma should be considered. Behçet's Disease in association with malignancy has been reported sporadically in a few case reports. Preservation of the uterus and ovaries in young women is possible with conservative surgical approach, once the presence of an associated primary ovarian tumour has been excluded. Long term prognosis in primary peritoneal serous borderline tumour is very good similarly to ovarian borderline tumours.

Key Words: Neoplasms, cystic, mucinous, and serous; peritoneum

ÖZET Primer peritoneal seröz "borderline" tümörler, nadir görülen bir epitelyal proliferasyon olup genellikle laparotomi sırasında tesadüfi olarak saptanırlar. Bu tümörler için risk faktörleri tam bilinmemektedir. Nulliparite ve infertilite tedavisinde kullanılan ilaçlar risk faktörü olup oral kontraseptifler koruyucu etki göstermektedirler. Ayırıcı tanıda mezotelyal proliferasyon, endosalpingios, endometriozis, yüksek dereceli primer peritoneal seröz karsinom ve overin primer seröz karsinomları düşünülmelidir. Malignensi ile birlikte Behçet hastalığı birkaç olguda sporadik olarak rapor edilmiştir. Primer ovarian bir tümörün varlığı dışlandığı durumlarda genç kadınlarda fertilitenin de korunması açısından uterus ile overleri koruyacak şekilde mezotelyal proliferasyon, endosalpingios, endometriozis, yüksek dereceli primer peritoneal seröz karsinom ve overin primer seröz karsinomları düşünülmelidir. Malignensi ile birlikte Behçet hastalığı birkaç olguda sporadik olarak rapor edilmiştir. Primer ovarian bir tümörün varlığı dışlandığı durumlarda genç kadınlarda fertilitenin de korunması açısından uterus ile overleri koruyacak şekilde mezotelyal proliferasyon, endosalpingios, endometriozis, yüksek dereceli primer peritoneal seröz karsinom ve overin primer seröz karsinomları düşünülmelidir. Malignensi ile birlikte Behçet hastalığı birkaç olguda sporadik olarak rapor edilmiştir. Primer ovarian bir tümörün varlığı dışlandığı durumlarda genç kadınlarda fertilitenin de korunması açısından uterus ile overleri koruyacak şekilde mezotelyal proliferasyon, endosalpingios, endometriozis, yüksek dereceli primer peritoneal seröz karsinom ve overin primer seröz karsinomları düşünülmelidir.

Anahtar Kelimeler: Tümörler, kistik, müsinöz, ve seröz; periton

Türkiye Klinikleri J Case Rep 2016;24(1):18-21

Primary Peritoneal Serous Borderline Tumour (PPSBT) is a rare entity with limited malignant potential.¹ Real incidence is not known as the lesion is mostly found as incidental finding in surgical operations made for another reason. This is a müllerian type proliferation of peritoneum which has been named "Atypical Endosalpingiosis" or "Primary Papillary Peritoneal Neoplasm" in last two decades. The long-term outlook for these patients is remarkably favorable. It is difficult to determine the malignant potential in pre-operative period.²

doi: 10.5336/caserep.2013-38574

Copyright © 2016 by Türkiye Klinikleri

Aim of this paper is to present microscopic findings of a case of PPSBT in a 23 year old woman together with the review of literature of this rare tumour.

CASE REPORT

Case is a 23-year-old, nulligravid, virgin, white race patient without any gynecological disease. In her medical history, she had Behçet's Disease for 6 years.

She has history of azothioprine, corticosteroid and interferon-alpha usage periodically before. She presented with persistent right inguinal pain. In pelvic examination, 5 cm diameter smooth surfaced mass was palpated which begins from middle abdomen and grows to the right side. 95x58 mm paraovarian cystic lesion was detected in ultrasound scan. Tumour markers were CA-125: 18,4 U/ml [1,9-16,3], CEA: 0,571 mg/ml [0-34], AFP: 0,988 IU/ml [0-5,8], Beta-HCG: <1,00 mIU/ml [0-30]. In pelviabdominal computed tomography an 8,5x5x7 cm relatively smooth edged hypodens mass was detected at right lateral adnex.

A 23-year-old white virgin nulligravid woman was admitted to the hospital because of persistent right inguinal pain which had started 2 months earlier associated without any other symptom. She had Behçet's disease for 6 years with history of azothioprine corticosteroids and interferon alpha usage for it periodically.

The patient underwent laparoscopic surgery. In intraoperative exploration we found an adnexial mass which origins from peritoneum and extends to abdominal cavity with multiple adhesions to ovaries and uterus. Rest of the peritoneal surfaces was normal. We performed laparoscopic cyst excision. After the cyst excision patient was discharged at postoperative 3rd day.

Microscopic examination disclosed tumour clusters of branching papillae or glandular structures, which had prominent psammomatous calcifications (Figures 1, 2). The tumour cells lack significant cytologic atypia and mitoses. Stromal invasion is not identified. Atypical proliferating serous tumour has developed in 4 mm² of the peri-

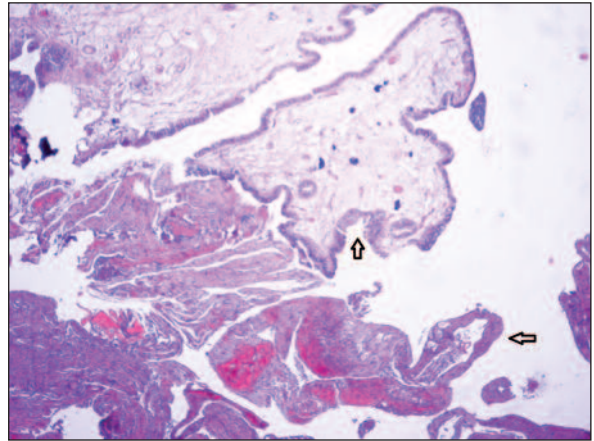


FIGURE 1: Atypical proliferating serous tumour development (arrows) (haematoxylin and eosin stain; original magnification, x80).

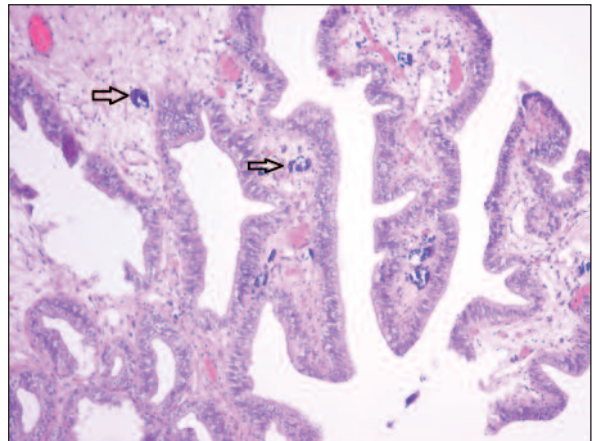


FIGURE 2: Psammoma bodies (arrows) are noted in the core of the papilla and stroma (haematoxylin and eosin stain; original magnification, x200).

toneum. In that area there are also psammomatous calcifications, peritonitis, chronic inflammatory process showing abscess formation and peritoneal inclusion cysts (Figure 3).

An informed consent form obtained from patient.

DISCUSSION

PPSBT is usually seen in women younger than 40 years and has a really good prognosis. It can presents various manifestations (infertility, pelvic pain, chronic pelvic inflammatory disease, amenorrhea, pelvic mass) mostly found incidentally.³ Usually pelvic mass and high serum CA-125 levels imitate an ovarian malignancy.

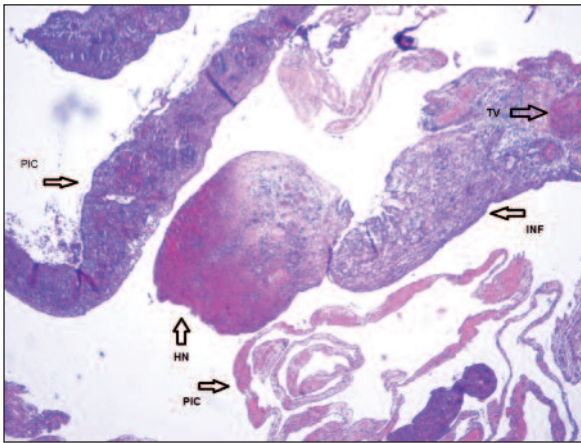


FIGURE 3: Peritoneal inclusion cyst (PIC), Haemorrhagic Necrosis (HN), Chronic inflammation (INF), Thrombosis Vessel (TV) (haematoxylin and eosin stain; original magnification, x80)

The gross characteristics of PPSBT observed during the surgery have variable appearances, with focal-to-diffuse lesions that may be miliary, granular, or nodular or may resemble adhesions.^{2,4,5}

Microscopic findings of peritoneal/serosal foci are divided into two categories as lesions with or without fibroblastic reaction surrounding epithelial cell proliferations. Epithelial component can be changed by the proliferation of surrounding microstructural cellular units. Due to its complexity and severity lesion may include unique cells or small solid cell clusters. There is no significant histological atypia or mitosis in cells. Destructive stromal invasion is generally not defined. Lesions without fibroblastic reaction have wide papillary groups with epithelial cells that are located near peritoneal surface or can be separated easily from peritoneal surface and have moderate cellular atypia. Papillae are formed of flat, cuboidal or columnar cells organized in simple or stratified manner. These cells separate from stroma by forming clefts. In those lesions usually there are several psammoma bodies.^{2,6,7}

PPSBT is invariably extensive and thought to develop from a pre-existing endosalpingiosis which is present in 70-80% of cases. Endosalpingiosis is a metaplastic lesion in the peritoneal cavity and is a precursor for PPSBT.^{1,7}

Behçet's Disease was first described by Hulusi Behçet in 1937 as a triad of recurrent aphthous ulcers of the mouth and genitalia and relapsing

uveitis and also systematic vasculitis of unknown origin that may involve all systems.⁸ Several studies have shown that there's no increase in malignancy risk in Behçet's Disease compared to normal population.^{9,10}

Bell and Scully described 25 cases originally diagnosed as PPSBT, atypical endosalpingiosis, or serous cystadenoma/cystadenofibroma with peritoneal implants.¹ The patients were all women, aged 19 to 53 years, and had a variable clinical history, which included abdominal/ pelvic pain (7 patients), infertility (6 patients), chronic pelvic inflammatory disease, small bowel obstructive symptoms, and amenorrhea. Eight of the patients' peritoneal lesions were incidental to laparotomy for other reasons (benign ovarian serous tumour, leiomyoma, ventral hernia, and cesarean section). Biscotti and Hart studied 17 cases of PPSBT. The patients were all girls or women aged 16 to 67 years. Nine of Biscotti and Hart's cases were incidental to surgery performed for other reasons, such as caesarean section, endometriosis, or adhesions.^{1,7}

The pathological differential diagnosis includes endometriosis, endosalpingiosis, benign reactive mesothelial proliferations such as adenomatoid tumour or florid mesothelial hyperplasia, and borderline mesothelial proliferations with similar histological features, which include benign or well-differentiated papillary mesothelioma.^{4,5,11-14}

Primary peritoneal neoplasms showed significantly less expression of estrogen receptor and progesterone receptor than ovarian primary tumours did.¹¹ Calretinin, which is a mesothelial cell marker was negative in our case.

PPSBT is a very rare case and should be considered in the differential diagnosis of epithelial proliferations with associated psammoma bodies on the peritoneal surfaces of viscera. Correlation with clinical presentation, radiographic findings, surgical staging, histopathologic and immunohistochemical findings of the epithelial proliferation is essential for the correct diagnosis. Conservative surgery can be performed in young fertile female patients.

REFERENCES

- Bell DA, Scully RE. Serous borderline tumours of the peritoneum. *Am J Surg Pathol* 1990; (14):230-9.
- Hutton RL, Dalton Sr. Primary peritoneal serous borderline tumours. *Arch Pathol Lab Med* 2007;131(1):138-44.
- Tinelli A, Malvasi A, Pellegrino M. An incidental peritoneal serous borderline tumor during laparoscopy for endometriosis. *Eur J Gynaecol Oncol* 2009;30(5):579-82.
- Arraiza M, Metser U, Vajpeyi R, Khalili K, Hanbidge A, Kennedy E, et al. Primary cystic peritoneal masses and mimickers: spectrum of diseases with pathologic correlation. *Abdom Imaging* 2014 Oct 1. [Epub ahead of print]
- Levy AD, Shaw JC, Sobin LH. Secondary tumors and tumorlike lesions of the peritoneal cavity: imaging features with pathologic correlation. *Radiographics* 2009;29(2):347-73.
- Biron-Shental T, Klein Z, Edelstein E, Altaras M, Fishman A. Primary peritoneal borderline tumour. A case report and review of the literature. *Eur J Gynaecol Oncol* 2003; 24(1):96-8.
- Go HS, Hong HS, Kim JW, Woo JY. CT appearance of primary peritoneal serous borderline tumour: a rare epithelial tumour of the peritoneum. *Br J Radiol* 2012;85(1009):e22-5.
- Biscotti CV, Hart WR. Peritoneal serous micropapillomatosis of low malignant potential (serous borderline tumours of the peritoneum): a clinicopathologic study of 17 cases. *Am J Surg Pathol* 1992;16(5):467-75.
- Behçet H. Über rezidivierende aphtose, durch ein virus verursachte Geschwure am Mund, am Auge und an den Genitalien. *Dermatol Wschr* 1937;105:1152-7.
- Arimura K, Arima N, Matsushita K, Akimoto M, Park CY, Uozumi K, et al. High incidence of morphological myelodysplasia and apoptotic bone marrow cells in Behçet's disease. *J Clin Immunol* 2007;27(2):145-51.
- Tada Y, Koarada S, Haruta Y, Mitamura M, Ohta A, Nagasawa K. The association of Behçet's disease with myelodysplastic syndrome in Japan: a review of the literature. *Clin Exp Rheumatol* 2006;24(5 Suppl 42):S115-9.
- Halperin R, Zehavi S, Hadas E, Habler L, Bukovski I, Schneider D. Immunohistochemical comparison of primary peritoneal and primary ovarian serous papillary carcinoma. *Int J Gynecol Pathol* 2001;20(4):341-5.
- Bell DA, Scully RE. Benign and borderline serous lesions of the peritoneum in women. *Path Annu* 1989;24 Pt 2:1-21.
- Bell KA, Smith Sehdev AE, Kurman RJ. Refined diagnostic criteria for implants associated with ovarian atypical proliferative serous tumours (borderline) and micropapillary serous carcinoma. *Am J Surg Pathol* 2001; 25(4):419-32.
- Smith Sehdev AE, Sehdev PS, Kurman RJ. Noninvasive and invasive micropapillary (low-grade) serous carcinoma of the ovary: a clinicopathologic analysis of 135 cases. *Am J Surg Pathol* 2003;(27(6):725-36.