

# Axillary Elastofibroma: Original Image

## Aksilla Elastofibroması

Zafer ÖZSOY, MD,<sup>a</sup>  
Fatma Nilay YOĞUN, MD<sup>a</sup>  
Hürriyet TURGUT, MD,<sup>b</sup>

<sup>a</sup>Clinic of Plastic, Reconstructive and  
Eigthetic Surgery

<sup>b</sup>Clinic Medical Pathology,  
Bezm-i Alem Valide Sultan Vakıf  
Gureba Training and Research  
Hospital, İstanbul

Geliş Tarihi/Received: 12.05.2008  
Kabul Tarihi/Accepted: 04.07.2008

Yazışma Adresi/Correspondence:  
Fatma Nilay YOĞUN, MD  
Bezm-i Alem Valide Sultan Vakıf  
Gureba Training and Research  
Hospital, Clinic of Plastic,  
Reconstructive and Esthetic Surgery,  
İstanbul  
TÜRKİYE/TURKEY  
dr\_nilay@yahoo.com

**ABSTRACT** Elastofibroma is a rare, benign neoplasm of the elderly, typically located in the subscapular area. An intramuscular lesion that was hypointense in the center and hyperintense at the periphery was observed in the magnetic resonance images of our case. The mass located within the latissimus dorsi was removed through a vertical incision made on the posterior of the left axilla paying attention to axillary vessels and nerves. Histopathologic examination after Hematoxylin-Eosine and Von Gieson staining demonstrated degenerated elastic fibers. CD34 and Vimentin showed positive reaction, whereas smooth muscle actin, S100 and desmine showed negative reaction in immunohistochemical analysis. This case of elastofibroma is presented for its unusual localization, namely in the axilla.

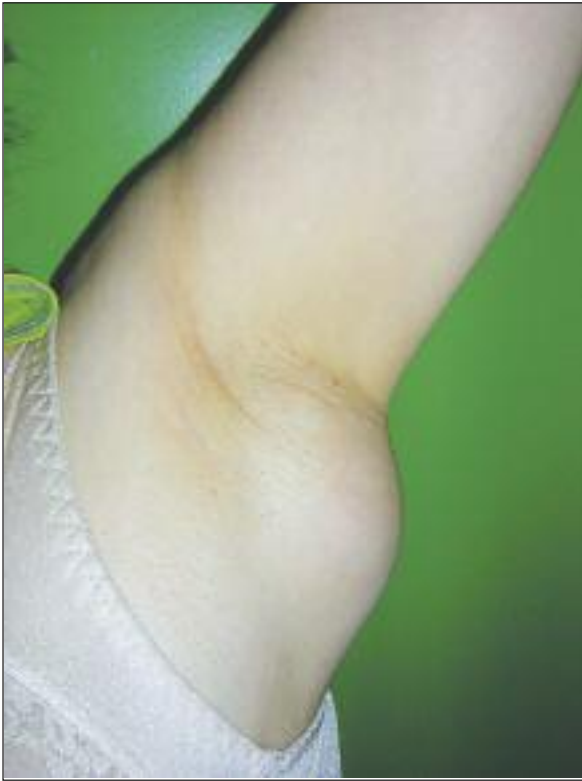**Key Words:** Axilla; fibroma

**ÖZET** Elastofibrom ileri yaşlarda subskapuler bölgede gelişen, nadir görülen benign bir neoplazmdir. Olgunun MR incelemesinde santrali hipointens ve periferi hiperintens kas içi yerleşimli lezyon olarak geldi. Genel anestezi altında sol aksilla posteriordan vertikal insizyonla girilerek aksiller damar ve sinirler korunarak latissimus dorsi kası içinde kitleye ulaşıldı ve ekstirpe edildi. Kitleye yönelik patolojik incelemede Hematoksilin-Eozin ve Von Gieson ile boyama yapıldı ve dejenere elastik lifler gösterildi. İmmunohistokimyasal çalışmada CD34 ve Vimentin ile pozitif reaksiyon saptandı. Elastofibroma aksiller bölgede nadir olarak görülmektedir.

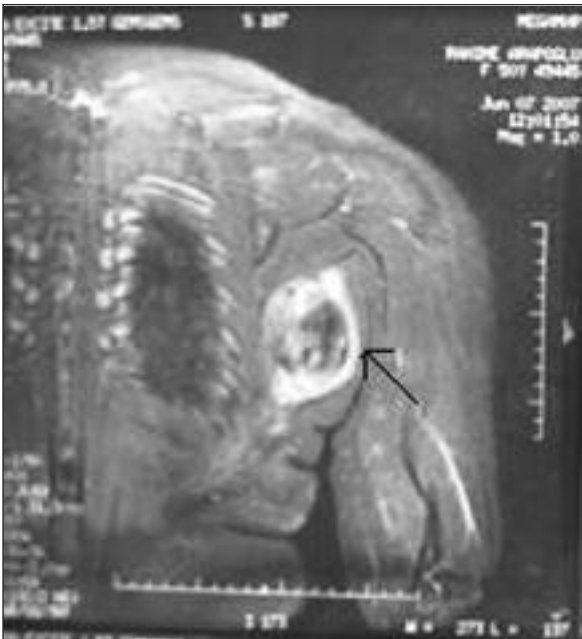**Anahtar Kelimeler:** Aksilla; fibroma

**Türkiye Klinikleri J Med Sci 2008;28:778-781**

A 51-year-old female presented to our clinic with a swelling in her left armpit, which had progressively enlarged within the last 8 years (Figure 1). On her physical examination, a mobile, solid and smooth contoured mass of 8 x 6 x 5 cm was palpated in the posterior wall of the left axilla. The mass could not be visualized by plain radiography. MR imaging of the case revealed an intramuscular lesion that showed hypointense signals in the center and hyperintense signals at the periphery (Figure 2). Mass located within the latissimus dorsi was removed through a vertical incision made on the posterior of the left axilla paying attention to axillary vessels and nerves. Excision was accomplished by a gentle dissect-



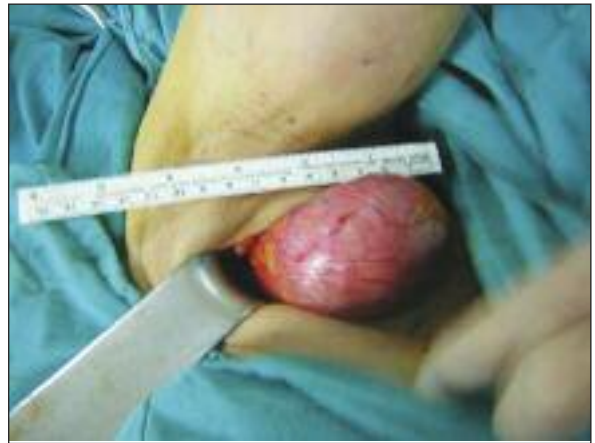**FIGURE 1:** Preoperative Image of the case.



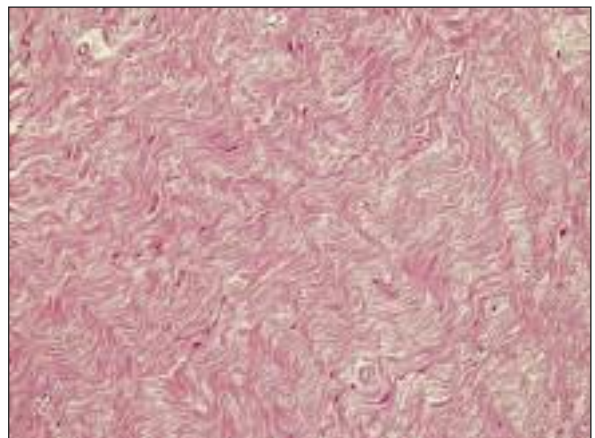
**FIGURE 2:** MR Image with Coronal STIR sequence.

on from the anterior to the posterior, protecting axillary vessels and nerves. The mass did not have a major artery (Figure 3). The patient was discharged on the third postoperative day without any complication.

Histopathologic examination performed after Hematoxylen-Eosine stain revealed a neoplastic lesion comprising of mature fatty tissue within the proliferated fibroblastic cells that showed high degree of collagenization. Eosinophilic collagen and elastic fibers with degenerative changes were observed in the stroma (Figure 4). Degenerated elastic fibers demonstrated intense staining with Von Gieson (Figure 5). CD34 and Vimentine showed



**FIGURE 3:** Intraoperative image of the case.



**FIGURE 4:** Degenerated elastic fiber structures within fibroadipose tissues (HEX100).

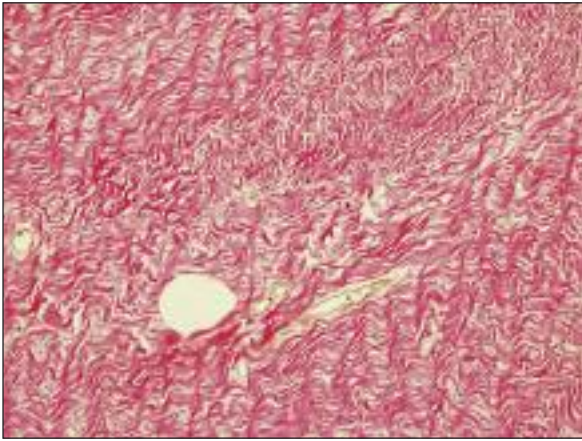


FIGURE 5: Image of elastic fibers with elastic Von Gieson x 100.

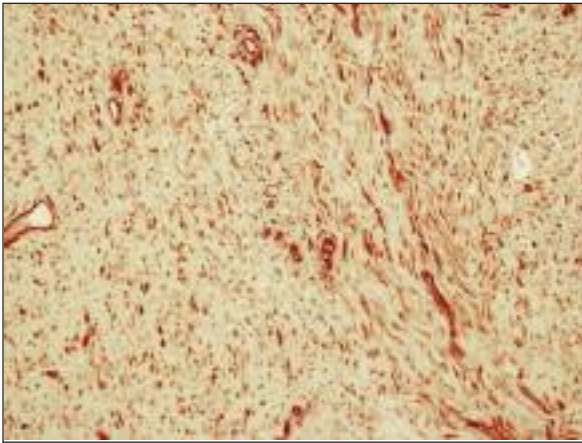


FIGURE 6: CD 34 positivity in neoplasm cells (CD 34 X 100).

positive reaction, whereas smooth muscle actin, S100 and desmine showed negative reaction in immunohistochemical analysis (Figure 6, 7).

## DISCUSSION

Elastofibroma is a benign neoplasm of the elderly population particularly among women.<sup>1,2</sup> Extrasca-

pular location is rare. Localization in the colon, intestine, cornea, deltoid, and omentum have also been reported.<sup>3,4</sup> The author had operated a bilateral elastofibroma dorsi case previously but in this case, the mass was located in the left axilla.<sup>5</sup> To our knowledge, axillary localization of this type of tumor has not been reported up to date. It is visualized as a heterogeneous soft tissue mass with irregular contours in the MR images.<sup>1</sup> Macroscopically, elastofibroma is a solid mass with irregular contours sizing from 5 to 10 cm.

Elastofibromas are benign lesions with inconsistent histopathologic structure depending upon their localization.<sup>3</sup> Elastofibroma is reported to be due to the degeneration of collagen fibers to elastic fibers and a disorder in the biosynthesis of elastic fiber.<sup>1</sup> Radiotherapy and inheritance were also suggested to play a role in the etiology.<sup>1</sup>

Elastofibroma is treated by simple excision; local recurrence is rare, and no malignant transformation was reported.<sup>1</sup> Elastofibromas do not recur if they are removed completely.<sup>6</sup> No recurrence was observed in the follow-up examinations of our case performed up to postoperative 9 month.

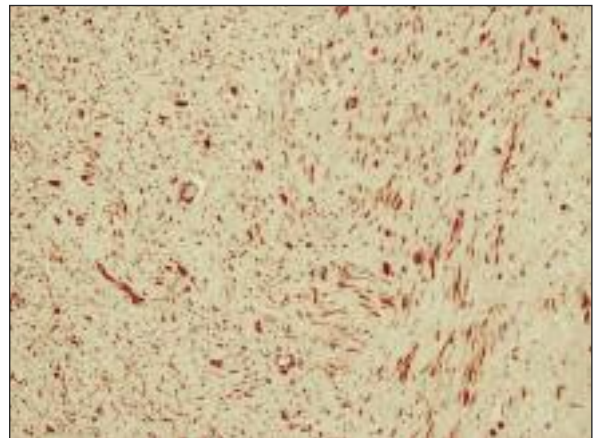


FIGURE 7: Vimentine positivity in neoplasm cells (Vimentine X 100).

## REFERENCES

1. Enzinger F, Weiss SW. Soft Tissue Tumors. 9<sup>th</sup> ed. Missouri: Mosby; 2002. p.286-9.
2. Rosai J. Ackerman's Surgical Pathology. 8<sup>th</sup> ed. Missouri: Mosby; 1996. p.2030-1.
3. Goldblum JR, Beals T, Weiss SW. Elastofibromatous change of the rectum. A lesion mimicking amyloidosis. Am J Surg Pathol 1992;16:793-5.
4. Hsu JK, Cavanagh HD, Green WR. An unusual case of elastofibroma oculi. Cornea 1997;16:112-9.
5. Özsoy Z, Kul Z, Gözü A, Derivisoglu S. Bilateral elastofibroma dorsi: Olgu sunumu. Türk Plast Rekonstr Est Cer Derg 2005;13:219-20.
6. Özbarlas HS. [Benign soft tissue tumors]. Türkiye Klinikleri J Surg Med Sci 2006;2: 45-8.