

Rapid Mandibular Symphysis Widening by Distraction Osteogenesis with Intraoral Devices: Case Report

Intraoral Aparenter ile Gerçekleştirilen Hızlı Mandibular Simfiz Distraksiyon Osteogenezisi

Kemal Murat OKÇU,^a
Gürkan Raşit BAYAR,^b
Hasan Ayberk ALTUĞ,^c
Metin ŞENÇİMEN,^d
Necdet DOĞAN,^d
Osman BENLİ,^e
Hasan Suat GÖKÇE^f

^aDental Clinic,
Beytepe Military Hospital,
Departments of
^dOral and Maxillofacial Surgery,
^eOrthodontics,
^fProsthodontics,
Gülhane Military Medical Academy
Dental Sciences Center, Ankara
^bDental Clinic,
Guzelyali Military Hospital, İzmir
^cDental Clinic,
Diyarbakır Military Hospital,
Diyarbakır

Geliş Tarihi/Received: 10.06.2008
Kabul Tarihi/Accepted: 26.09.2008

*This case report was presented as a
poster at VIII. BASS The Balkan
Stomatology Congress Albania, 2003*

Yazışma Adresi/Correspondence:
Metin ŞENÇİMEN
Gülhane Military Medical Academy
Dental Sciences Center,
Department of Oral and
Maxillofacial Surgery, Ankara
TÜRKİYE/TURKEY
metinsencimen@yahoo.com

ABSTRACT Transverse mandibular deficiency with crowding of the mandibular anterior teeth is frequently present in patients with Class I and II malocclusions. Some surgical technique has been developed to widen the mandible. Our method is based upon distraction osteogenesis, process of bone formation that occurs during slow separation of the segments, following vertical interdental symphyseal osteotomy. A Symphysis Distractor (Martin) was used to gradually widen the mandible. Distraction osteogenesis is a viable alternative to treatment of transverse mandibular deficiency without extraction of teeth.

Key Words: Osteogenesis, distraction; mandibular advancement

ÖZET Transvers mandibular defektlerin düzeltilmesi esnasında seri diş çekimlerinin kullanılması gerekebilmektedir. Transmandibular distraksiyon yöntemi ise diş çekimine gerek duymadan defektin tedavisini mümkün kılmaktadır. Sınıf I ve II maloklüzyonlu bireylerde transvers mandibular bozukluklara ilaveten sıklıkla mandibular anterior dişlerin çapraşıklıklarından da bahsedilmektedir. Mandibulanın genişletilmesi ile düzelebilecek bu bozuklukların tedavisi amacıyla bazı teknikler geliştirilmiştir. Bizim uyguladığımız metot interdental dental osteotomi sonrasında ikiye ayrılan kemik segmentlerinin dereceli olarak ayrılması esasına dayanan distraksiyon osteogenezis uygulamasıdır. Simfiz distraktörü (Martin) mandibulayı lateral yönde genişletmeye yarayan bir distraktör çeşididir. Bu distraksiyon yöntemi ile transvers mandibular defektlerin diş çekimine gerek duyulmaksızın tedavisi söz konusu olabilmektedir.

Anahtar Kelimeler: Osteogenezis, distraksiyon; osteogenezis, distraksiyon

Türkiye Klinikleri J Dental Sci 2009;15(2):135-8

Mandibular symphysis osteodistraction was initially reported by Guerrero in 1990 and has been used sparingly by others.¹⁻³ Distraction osteogenesis especially symphyseal distraction is an efficient surgical alternative to orthognatic surgery for widening the mandible and treatment of transverse mandibular deficiency without extraction of teeth.^{1,3-5}

The aim of this presentation is to perform two cases with insufficient mandibular width treated by symphyseal distraction osteogenesis.

CASE REPORTS

CASE 1

A fifteen year-old girl was referred to our center for a transverse mandibular deficiency (Figure 1a). After clinical and radiographic examination of the patient in collaboration with the department of orthodontics we decided to widening the mandible by distraction osteogenesis (Figure 1b). Firstly the consent form was signed by the patient. After the soft tissue dissection the distraction device were gently adapted to the symphyseal region with bending pliers according the planned osteotomy line. Transmandibular osteotomy was brought up superiorly to meet the facial corticotomy made between the incisors (Figure 1c). Then the distractor was placed to distraction site and fixed with microscrews to the bone and mandibular occlusal splint (Figure 1d).

Seven days after surgery the distraction was started at the rate of 1 mm per day until desired widening was achieved. Distractor was in position for eight weeks after the distraction period (Figure 1e). Periapical radiographs were taken every two weeks in consolidation period to monitor the radio-density of the osseous gap. The distractor of patient

one was removed after a consolidation period of three months (Figure 1f).

CASE 2

A thirteen year-old boy was referred to our center for dental crowding, narrow arch form (transverse mandibular deficiency). After clinical and radiographic examination of the patient in collaboration with the department of orthodontics we decided to widening the mandible by distraction osteogenesis (Figure 2a, b). Then the patient signed the consent form about this operation. In this patient to prevent the discomfort of the distractor's body to anterior soft tissue a preventive shield was made (Figure 2c). The shield was attached to the device after the wound closure at the end of the surgical operation. The distraction period is finished but the consolidation period is still go on in this patient (Figure 2d, e).

DISCUSSION

The principal indication for widening the mandible is absolute transverse mandibular deficiency. An excessively narrow arch form, dental crowding, tipped teeth and congenitally missing teeth are other indications for the use of surgery which

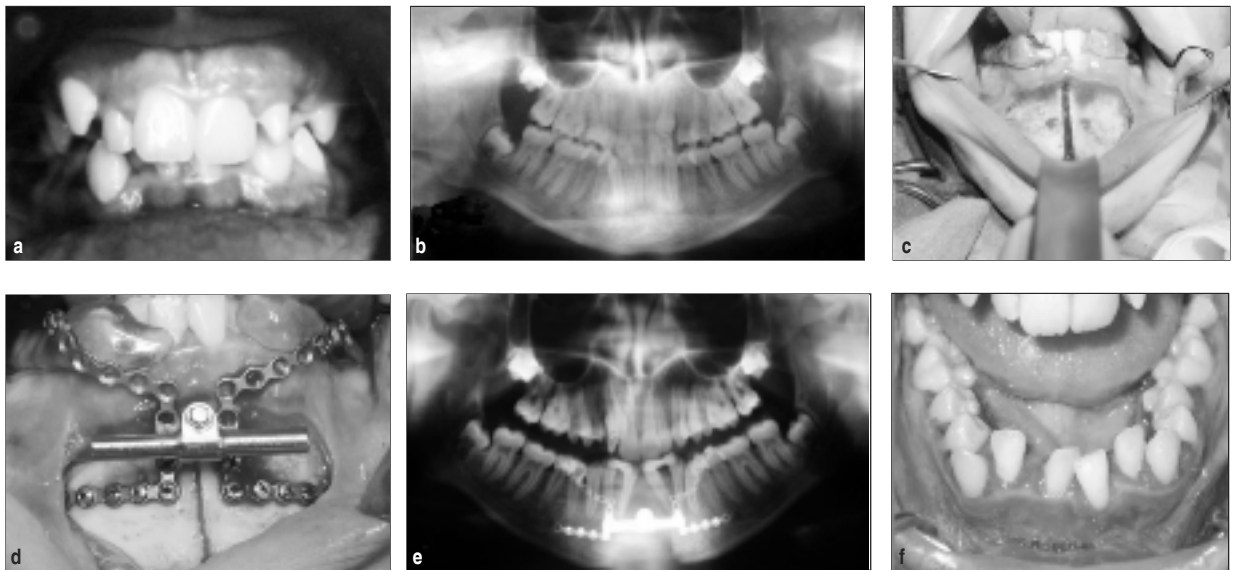


FIGURE 1: a) Preoperative clinical appearance of the patient, b) Preoperative panoramic radiography of the patient, c) Intraoperative view of the osteotomy line, d) Intraoperative placement of the distractor in case 1, e) Postoperative radiographic appearance of case 1 after a consolidation period of three months, f) Postoperative intraoral clinical view of the distraction area.

is intended to normalize basal bone position and facilitate non-extraction orthodontic treatment.^{2,6-8}

Profitt and Ackerman have reported a high risk of dental relapse when compensating orthodontic therapy has been performed to increase the inter-canine width in the presence of a primary transverse bone deficiency.⁹

Braun et al., undertook to determine the true nature of condylar displacements associated with mandibular symphyseal distraction osteogenesis.⁵ They reported that each condyle was laterally displaced in direct relationship to the amount of symphyseal distraction. Temporomandibular joints (TMJ) appear to accommodate these displacements because symptoms were not introduced or, if present before treatment, symphyseal distraction did not exacerbate them in their study. This result is similar to reports by other investigator.²⁻⁴

Although we had a short-term follow up of our patients we also did not detect TMJ symptoms, decreased of crestal bone height, loss of tooth vitality and decreased of attached gingival tissue height.

Mommaerts used The Transmandibular Distractor (bone anchored intraoral device) for symphyseal widening by callus distraction.¹⁰ He pioneered its advantages including limited surgical exposure, skeletal anchorage, and expansion along the arch segment together with proportional and differential widening in the frontal plane.

CONCLUSION

We fixed the distractor to bone and used mandibular occlusal splint for widening the mandibular symphyseal region to obtain an equal gap along the osteotomy line. The occlusal splint which formed the upper part of the distractor prevented the negative effects of the occlusal interference during the distraction. In our opinion mandibular symphyseal distraction is a useful technique for widening the mandible.

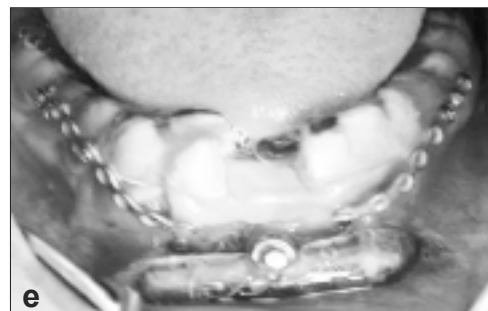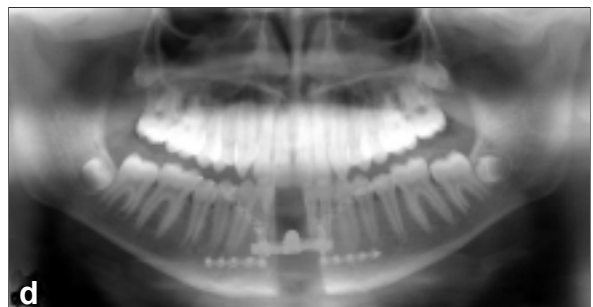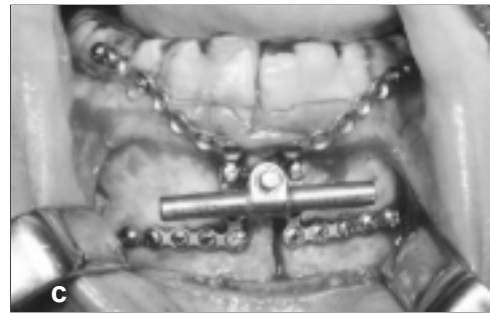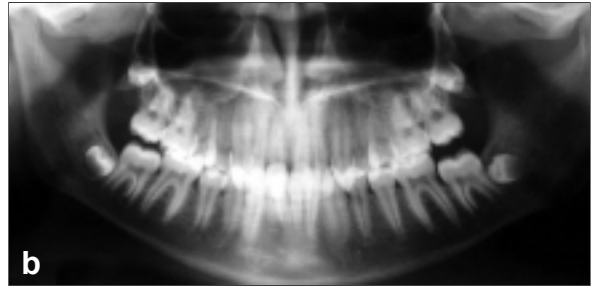


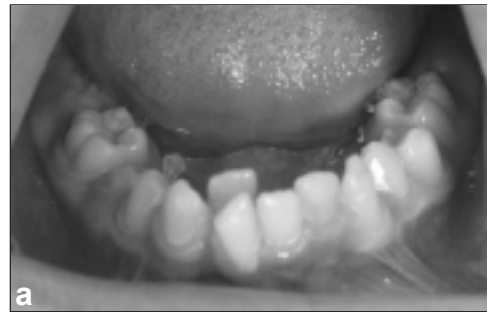FIGURE 2: a) Preoperative clinical appearance of the patient, b) Preoperative panoramic radiography of the patient, c) Intraoperative placement of the distractor in case 2, d) Postoperative radiographic appearance of case 2 after distraction period, e) Postoperative intraoral clinical view of the distraction area.

REFERENCES

1. Guerrero C. Rapid mandibular expansion. *Rev Venez Ortod* 1990;1-2:48.
2. Perrott DH, Berger R, Vargervik K, Kaban LB. Use of a skeletal distraction device to widen the mandible: a case report. *J Oral Maxillofac Surg* 1993;51(4):435-9.
3. Kewitt GF, Van Sickels JE. Long-term effect of mandibular midline distraction osteogenesis on the status of the temporomandibular joint, teeth, periodontal structures, and neurosensory function. *J Oral Maxillofac Surg* 1999; 57(12):1419-26.
4. Weil TS, Van Sickels JE, Payne CJ. Distraction osteogenesis for correction of transverse mandibular deficiency: a preliminary report. *J Oral Maxillofac Surg* 1997;55(9):953-60.
5. Braun S, Bottrel JA, Legan HL. Condylar displacement related to mandibular symphyseal distraction. *Am J Orthod Dentofacial Orthop* 2002;121(2):162-5.
6. Havlik RJ, Bartlett SP. Mandibular distraction lengthening in the severely hypoplastic mandible: a problematic case with tongue aplasia. *J Craniofac Surg* 1994;5(5):305-12.
7. Bayram M, Ozer M, Alkan A. Mandibular symphyseal distraction osteogenesis using a bone-supported distractor. *Angle Orthod* 2007; 77(4):745-52.
8. Alkan A, Ozer M, Baş B, Bayram M, Celebi N, Inal S, Ozden B. Mandibular symphyseal distraction osteogenesis: review of three techniques. *Int J Oral Maxillofac Surg* 2007;36(2): 111-7.
9. Profitt WR, Ackerman JL. Diagnosis and treatment planning in orthodontics. In: Graber TM, Vanarsdall RL, eds. *Orthodontics Current Principles and Techniques*. 2nd ed. Philadelphia: Mosby-Year Book, Inc, 1994: 3-95.
10. Mommaerts MY. Bone anchored intraoral device for transmandibular distraction. *Br J Oral Maxillofac Surg* 2001;39(1):8-12.