

The Effects of Dimethyl Sulfoxide and Pentoxifylline on Plasma MDA Levels and Tissue Damage in Sepsis

SEPSİSTE DİMETİLSULFOKSİD VE PENTOKSİFİLİNİN PLAZMA MDA DÜZEYLERİ VE DOKU HASARINA ETKİLERİ

Şakir TEKİN*, Hüsnü ALPTEKİN**, Mustafa ŞAHİN***, Celalettin VATANSEV*, Mustafa Cihat AVUNDUK****, Mehmet GÜRBİLEK***** , Adnan KAYNAK*****

* Ass.Prof.Dr., Selçuk University Medical Faculty Department of General Surgery,
** Dr., Selçuk University Medical Faculty Department of General Surgery,
*** Asc.Prof. Dr., Selçuk University Medical Faculty Department of General Surgery,
**** Asc.Dr., Selçuk University Medical Faculty Department of Pathology,
***** Prof.Dr., Selçuk University Medical Faculty Department of Biochemistry,
***** Prof.Dr., Selçuk University Medical Faculty Department of General Surgery, Konya, TURKEY

Summary

Aim: The aim of this study is to investigate the effects of Dimethyl sulfoxide (DMSO) and Pentoxifylline (PTX) on plasma Malondialdehyde (MDA) levels and tissue damage in septic rats.

Materials and Methods: 40 Wistar Albino rats were divided into four groups. Sepsis was induced by cecal ligation and perforation method in all groups. Nothing was used in sepsis group, in PTX group 15 mg/kg PTX, in DMSO group 300 mg/kg DMSO and in PTX+DMSO group 15 mg/kg PTX and 3 mg/kg DMSO were given intramuscularly. Blood and tissue samples were taken 24 hours after induction of sepsis and then animals were sacrificed. The plasma MDA levels were measured and the histopathological damages in lungs, liver and kidneys were evaluated.

Results: The plasma MDA level of sepsis group in comparison to the other 3 groups was higher and statistically significant (P<0.05). The neutrophil infiltration, interstitial edema and alveolar basal membrane damage in the lungs of PTX group, were less and statistically significant (p<0.05) when compared with sepsis group. Interstitial edema and intraalveolar fibrin deposition in the lungs of DMSO+PTX group, in comparison to the sepsis group, was less and the difference was statistically significant (p<0.05). There was no significantly different changes in liver and kidney tissues.

Conclusions: Pentoxifylline reduces plasma MDA levels and tissue damage in lung in sepsis. DMSO had no effect on preventing tissue damage meanwhile reducing plasma MDA levels.

Key Words: Sepsis, Free oxygen radicals, Dimethyl sulfoxide, Pentoxifylline, Antioxidants

T Klin J Med Res 2002, 20:125-131

Sepsis and accompanying septic shock have both an increasing incidence and a high mortality. Complex physiopathological changes in sepsis

Özet

Amaç: Çalışmanın amacı, deneysel sepsis oluşturulan ratlarda Dimetilsulfoksit (DMSO) ve Pentoksifilin'in (PTX) plasma Malondialdehid (MDA) düzeyleri ve doku hasarına olan etkilerini araştırmaktır.

Materyal ve Metodlar: Çalışmaya Wistar Albino cinsi 40 rat alındı ve ratlar 10'arlı 4 gruba ayrıldılar. Çekal ligasyon perforasyon yöntemi ile sepsis oluşturuldu. Sepsis grubuna (Grup I) bir şey verilmedi, Grup II: 15 mg/kg PTX, Grup III: 300 mg/kg DMSO, Grup IV: Her iki ajan aynı dozda i.m. olarak verildiler. Sepsisin oluşturulmasından 24 saat sonra rafların kan, akciğer, karaciğer ve böbrek doku örnekleri alındı ve denekler öldürüldüler. Plasma MDA düzeyleri ölçüldü ve dokulardaki histopatolojik değişiklikler mikroskopik olarak değerlendirildi.

Bulgular: Sepsis grubunun plasma MDA düzeyi diğer üç gruptan da anlamlı olarak yüksek idi (P< 0.05). PTX grubunda akciğerlerdeki nötrofil infiltrasyonu, interstisyel ödem ve alveolar bazal membran hasarı sepsis grubundan anlamlı olarak düşük derece bulundu, intraalveolar fibrin birikimi ve interstisyel ödem DMSO+PTX grubunda sepsis grubundan daha düşük düzeyde idi ve aradaki fark anlamlı idi (p<0.05). Karaciğer ve böbrekte gruplar arasında anlamlı değişiklik gözlenmedi (P>0.05).

Sonuç: Antioksidan etkili PTX sepsiste plazma MDA düzeyini düşürmekte ve akciğerde doku hasarını azaltmaktadır. DMSO plazma MDA düzeylerini düşürmesine karşın, dokular üzerine olumlu etki göstermemektedir.

Anahtar Kelimeler: Sepsis, Serbest oksijen radikalleri, Dimetilsulfoksit, Pentoksifilin, Antioksidanlar

T Klin Araştırma 2002, 20:125-131

varies from moderate to severe forms of circulatory shock (1). Toxins produced by microorganisms activate cellular and humoral

immune systems and as a result secreted mediators augment the host immune response. These mechanisms result in characteristic hemodynamic changes of sepsis such as high cardiac output, low systemic arterial resistance, and normal or low cardiac filling pressures (2-4).

In spite of new surgical techniques, antibiotics, and sophisticated critical care units, intra-abdominal infections are still important problems in surgical procedures (1-4). Increased permeability caused by the inflammation of the peritoneum results in the extravasation of protein-rich fluid. This fluid loss leads to hypovolemia. Increasing abdominal pressure increases abdominal vascular resistance, and alters venous return, splanchnic, and renal perfusions (5,6). Free oxygen radicals (FOR) generated during ischemia cause tissue damage through peroxidation of cell membrane phospholipids and leucocyte-endothelium interaction during hypoperfusion leads to microvascular thrombosis(7-12).

The aim of this study is to investigate the effects of pentoxifyllin (PTX), an agent preventing inflammatory effects of TNF- α on neutrophils and decreasing neutrophil-endothelium interaction, and dimethyl sulfoxide (DMSO), a non-enzymatic agent scavenging free oxygen radicals in sepsis and to compare their effects.

Materials and Methods

This study was held in the Experimental Medicine and Research Center of Selçuk University. Forty Wistar Albino type rats (mean weight 285 ± 35 gr) were used in this study, and they were divided into 4 groups. In all groups, sepsis was induced by cecal ligation-perforation (CLP) method.

Group I (Sepsis group): CLP was performed.

Group II (PTX group): CLP, and 15 mg/kg of pentoxifyllin (HOECHST) was injected intramuscularly.

Group III (DMSO group): CLP, and 300 mg/kg of DMSO (HOECHST) was injected intramuscularly.

Group IV (PTX+DMSO group): CLP, and 15 mg/kg of pentoxifyllin and 3 mg/kg of DMSO were injected intramuscularly.

The agents were injected intramuscularly in left groin 30 minutes before the procedure. Following anesthesia performed by Ketamine HCL (50 mg/kg), laparotomy was performed under sterile conditions through 2 cm of midline incision following shaving of abdomen of the rats and cecum was isolated. Cecum was filled with feces by squeezing ascending colon, then it was ligated by 3/0 silk and anterior surface of the cecum was perforated by 18 F needle twice. Rats were let to be fed by standard rat diet and tap water after 12th hours of the operation.

Rats were re-anesthetized at the end of 24th hour, re-anesthetized rats were sacrificed following 3 cc blood was withdrawn, the abdomen was opened and 1 g tissue samples of lung, liver, and kidney were taken. Blood samples were centrifuged at 3000rpm/min for 5 minutes, plasma samples were collected, and stored at -80°C . Plasma MDA levels were measured by thiobarbituric acid reactivity method described by Hunter et al (13).

Tissue samples taken from lung, liver and kidney were fixed in 10% formalin solution. After they were put in paraffin blocks by routine methods, 5 mm of slices were taken. Slices were stained by hematoxylin-eosin and were evaluated under light microscope by a pathologist. Histopathologic changes were graded from 0 to 3 points and after adding these points, the total score of every group was found and mean was calculated (0=absent, 1= mild, 2= moderate, 3= severe).

Histopathologic changes in the lung were evaluated for the presence and the degree of intra-alveolar fibrin deposition, neutrophil infiltration, damage in alveolar capillary membrane and interstitial edema. The presence and the degree of increase in the distance of Bowman's capsule and engorgement of kidney tubular cells were used for the evaluation of kidney. The presence and the degree of hydropic degeneration, Kupffer's cell hyperplasia and sinusoidal neutrophil infiltration were used as the evaluation criteria for liver injury.

SPSS for Windows (Version 10.1) program was used for statistical analysis. Variance analysis (ANOVA) was used to understate differences between groups in data in which parametric hypothesis was present. Tukey HSD was done as post Hoc test. Kruskal-Wallis and Mann-Whitney U tests were used to understate differences between groups in data in which nonparametric hypothesis was present. If p value is <0.05 , difference is accepted as significant.

Results

Plasma MDA Values

Mean plasma MDA levels of the groups were given in figure 1.

MDA level of sepsis group was significantly higher than other groups ($p<0.05$). At the same time, MDA level of PTX+DMSO group was significantly higher than both PTX and DMSO groups ($p<0.05$). There was no significant difference between PTX and DMSO groups.

Histopathologic changes in the lungs (Table 1).

Intraalveolar fibrin deposition was more in sepsis group than in Groups II and IV (Figure 2). These differences were statistically significant ($p<0.05$). There was no significant difference between the other groups.

Degree of the neutrophil infiltration was more in sepsis group than other groups and these differences were statistically significant ($p<0.05$). No statistically significant difference was present between the other groups.

Alveolar capillary basal membrane damage was significantly lower in Group II than Groups I and III ($p<0.05$). No significant difference was present between the other groups.

Interstitial edema was significantly higher in sepsis group than Groups II and IV ($p<0.05$). No statistically significant difference was present between the other groups.

Histopathologic changes in the kidneys (Table 2).

Increase in distance of Bowman's capsule was similar in all groups and no statistically significant difference was present between the groups (Figure 3).

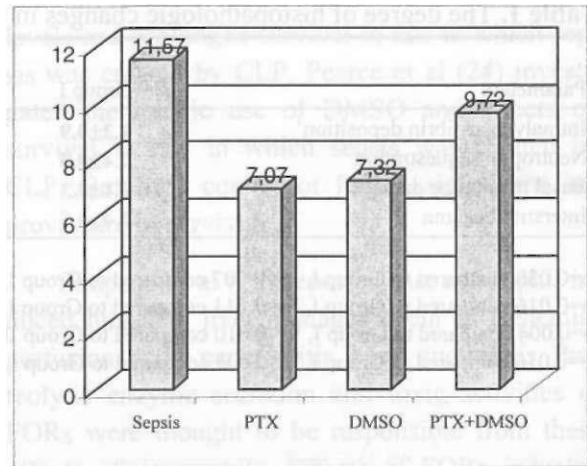


Figure 1. Plasma MDA levels (nmol/ml).

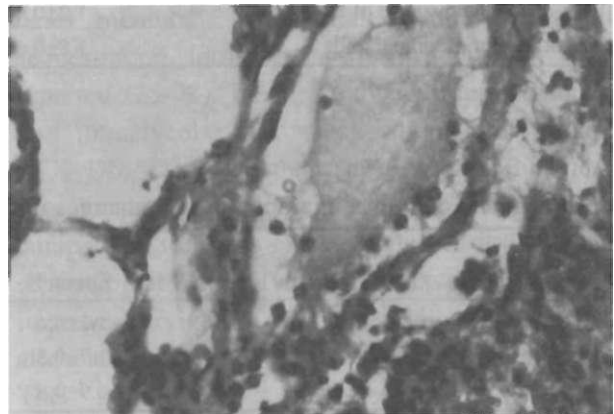


Figure 2. Neutrophil infiltration and intraalveolar fibrin deposition in lung in sepsis group (HE; x 40).

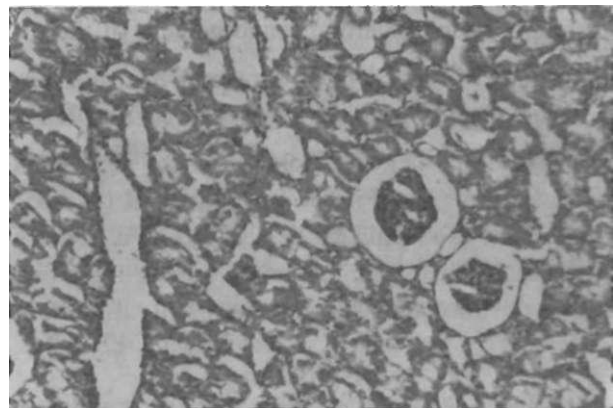


Figure 3. Increase in Bowman's capsule distance in sepsis group (HE; x20).

Table 1. The degree of histopathologic changes in the lung tissues (X+SD)

Parameters	Group I	Group II	Group III	Group IV	Kruskal-Wallis
Intraalveolar fibrin deposition ¹	1.2±0.9	0.4±0.7 ^a	0.7±0.7	0.2±0.4 ^b	P=0.022
Neutrophil sequestration	2.4±0.5	1.8±0.4 ^c	1.6±0.7 ^d	1.5±1.1 ^e	P=0.038
Basal membrane damage	2.1±0.3	1.3±0.7 ^f	2.2±0.6 ^g	1.9±1.0.6	P=0.010
Interstitial edema	2.4±0.5	1.8±0.4 ^h	2.0±1.0.8	1.5±0.5 ⁱ	P=0.020

¹p=0.038 compared to Group I, ^ap=0.007 compared to Group I, ^cp=0.016 compared to Group I, ^dp=0.011 compared to Group I, ^ep=0.048 compared to Group I, ^fp=0.004 compared to Group I, ^gp=0.010 compared to Group II, ^hp=0.016 compared to Group I, ⁱp=0.003 compared to Group I.

Table 2. The degree of histopathologic changes in the kidney (X±SD)

Parameters	Group I	Group II	Group III	Group IV	Kruskal-Wallis
Increase in the distance of Bowman's capsule	1.2±1.0.4	0.8±1.0.8	1.4±1.0.7	1.3±1.0.7	P=0.237
Engorgement of tubular cells	1.8±1.0.6	1.4±1.0.7	1.5±1.0.9	1.1±1.0.7	P=0.240

Table 3. The degree of histopathologic changes in the liver (X±SD)

Parameters	Group I	Group II	Group III	Group IV	Kruskal-Wallis
Hydrophic degeneration	1.2±1.0.6	0.2±1.0.4	0.5±1.0.5 ^a	0.7±1.0.8	P=0.007
Kupffer cell hyperplasia	1.7±1.0.8	2.0±1.0.8	1.6±1.0.5	1.3±1.0.4	P=0.206
Neutrophil	0.9±1.0.6	0.2±1.0.4	0.5±1.0.5	0.7±1.0.8	P=0.075

^ap=0.005 compared to Group I, ^bp=0.010 compared to Group I.

There was no statistically significant difference between groups regarding engorgement of the tubular cells.

Histopathologic changes in the liver (Table 3).

Hydrophic degeneration was more significant in sepsis group than in Groups II and III ($p < 0.05$) (Figure 4). No statistically significant difference was present between the other groups regarding Kupffer cell hyperplasia and neutrophil infiltration.

Discussion

Sepsis is initiated by exotoxins and endotoxins originated from microorganisms. Cellular immunity is activated in response to these toxins and

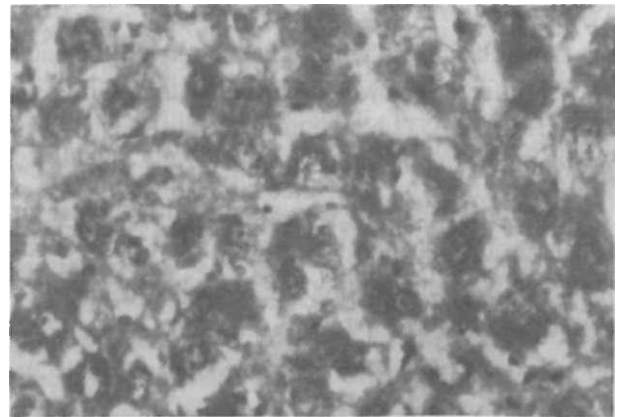


Figure 4. Hydrophic degeneration in liver tissue in sepsis group (HE;x20).

cytokines are secreted (2-4). TNF secreted following endotoxin stimulation activates neutrophils and makes their adhesion to endothelium easy. Also formation of FORs is stimulated (8,14,15). Leucocyte-endothelium interaction makes endothelium tissue factor and activates FVII leading to microvascular thrombosis (1,2). Current treatment protocols include xanthine oxidase inhibitors such as allopurinol, mannitol, and free oxygen radical scavengers like SOD, DMSO.

In this study we investigated antioxidant effects and tissue histopathologic changes of PTX, an agent (16-18) correcting hemodynamic parameters of sepsis, and DMSO, an agent (19,20) thought to be inhibiting adverse effects of free oxygen radicals, in experimental sepsis model. We measured plasma MDA levels of rats at the 24th hours. This value was higher in sepsis group than 3 other groups. There was no significant difference between PTX and DMSO groups regarding plasma MDA levels. Plasma MDA levels of groups in which PTX and DMSO were applied separately were lower than PTX+DMSO group.

We used DMSO as free oxygen radical inhibiting agent in our study. But we could not find the recovery of 3 histopathological changes of the lung in DMSO group in comparison to sepsis group. There was significant decrease in only neutrophil infiltration in DMSO group. Tissue damages in lungs were less in PTX and PTX+DMSO groups than in sepsis group. PTX prevented tissue damage effectively but DMSO showed no positive effect in tissue protection. On the other hand the preventive effect of PTX was reduced by DMSO in Group IV. It is known that PTX has a drug interaction (21), but DMSO is used as solvent in drug and chemical industries. It can be possible that molecular structure of PTX may be altered due to simultaneous application of these two agents.

Essani et al (22) found 86% decrease in TNF levels of mice after the use of DMSO and 80% decrease in the liver damage, and they suggested that the drug might have therapeutic potentials in the treatment of septic shock. Marinkovic et al (23) reported that use of DMSO, chlorpromazine, and

vitamin A combination decreased plasma MDA levels and prolonged survival in rats in which sepsis was created by CLP. Pearce et al (24) investigated therapeutic use of DMSO and effects on survival in rats in which sepsis was created by CLP. But they could not find a significant improvement in survival.

Simpson et al (25) reported that neutrophil induced lung and liver damages occur in ischemia-perfusion, acute pancreatitis, burn, and sepsis. Proteolytic enzyme secretion and toxic activities of FORs were thought to be responsible from these effects of neutrophils. Effects of FORs inducing liver damage were searched in many studies. As a result findings supporting increased microvascular permeability such as damage to alveolar capillary basal membrane, interstitial edema, neutrophil sequestration, intraalveolar fibrin deposition were reported (25-28). In our study we reported much less intraalveolar fibrin deposition in PTX and PTX+DMSO groups than sepsis group. But there was no significant difference in DMSO group in comparison to sepsis group. Myers et al (29) have reported that pentoxifylline may have been used to improve survival of animals with sepsis and to attenuate lung injury in acute lung inflammation. Their findings about the effect of PTX in lung injury were similar to our results.

Bringham (28) reported that it was possible that decreasing microvascular damage by use of agents inhibiting free oxygen radicals attenuated mechanical changes of the lung. Galat et al (30) reported that varying degrees of tubular damage and increase in the Bowman's capsule in their studies concerning renal dysfunction. Kajiwara et al (31) found renal tubular damage in the dogs, and reported that morphological changes were much less in SOD and DMSO treated groups. In our study, there were not any significant changes in kidney tissue in all groups, but hydrophic degeneration was less in PTX and DMSO groups in liver.

Liver and lung have a rich macrophage infiltration, and these organs are the transient gates for the circulating endotoxins (25). Van Bebber et al

(27) reported histopathologic changes such as Kupffer cell hyperplasia, neutrophil sequestration, cell necrosis in a study in which lipid peroxidation was investigated. In our study hydrophic degeneration in the liver was significantly slighter in PTX and DMSO groups than in sepsis group. Applied agents had no effects on Kupffer cell hyperplasia and sinusoidal neutrophil infiltration.

In conclusion, PTX has an antioxidant effect against to FOR-induced damage in sepsis, and decreases and prevents hydrophic degeneration in the liver and histopathologic changes in the lung together with lipid peroxidation. In comparison to DMSO it was much more effective than DMSO. We can suggest that PTX can be used as a therapeutic agent in sepsis although this is an animal study.

REFERENCES

- Bone RC, Balk RA, Cerra FB, et al. Definitions for sepsis and organ failure and guidelines for use of innovative therapies in sepsis. *Chest* 1992; 101: 1644-55.
- Scarg G, Redl H, Hallstrom S. The cell in shock: The origin of multiple organ failure. *Resuscitation* 1991; 21(2-3): 137-80.
- Root RK, Jakobs R. Septicemia and septic shock. In: Wilson JD, Braunwald E, Isselbacher KJ, editors. *Principles of Internal Medicine*. New York: McGraw-Hill 1991: 502-7.
- Lo CJ, Cryer HG, Fu M, Kim B. Endotoxin-induced macrophage gene expression depends on platelet-activating factor. *Arc Surg* 1997; 132(12): 1342-7.
- Parks DA, Granger DN. Ischemia-induced vascular changes: role of xanthine oxidase and hydroxyl radicals. *Am J Physiol* 1983; 245: 285-9.
- Reilly PM, Schiller JH, Bulkley GB. Pharmacologic Approach to Tissue Injury Mediated by Free Radicals and Other Reactive Oxygen Metabolites. *Am J Surg* 1991; 161:488-503.
- Sun XM, Hsueh W, Torre-Amione G. Effects of in vivo priming on endotoxin-induced hypotension and tissue injury. The role of PAF and tumor necrosis factor. *Am J Pathol* 1990; 136(4): 949-56.
- Mayers I, Johnson D. The nonspecific inflammatory response to injury. *Can J Anaesth* 1998; 45(9): 871-9.
- Halliwell B. Lipid peroxidation, oxygen radicals, cell damage, and antioxidant therapy. *Lancet* 1984; 23: 1396-97.
- Stein U. Free radicals and anti oxidants. *Rev Bras Neurol* 1994;30(supl 1): 12-7.
- Southorn PA. Free Radicals in Medicine. 1. Clinical Nature and Biological Reactions. *Mayo Clin Proc* 1988; 63: 381-9.
- Goode HF, Webster NR. Free radicals and antioxidants in sepsis. *Crit Care Med* 1993; 21(11): 1770-76.
- Hunter MIS, Nlemadim BC, Davidson DLW. Lipid peroxidation products and antioxidant proteins in plasma and cerebrospinal fluid from multiple sclerosis patients. *NeurochemRes*. 1985;10: 1645-52.
- Dunzendorfer S, Schratzberger P, Reinisch N, et al. Pentoxifylline differentially regulates migration and respiratory burst activity of the neutrophil. *Ann NY Acad Sci* 1997; 15: 832:330-40.
- Simms HH, D'Amico R. Intraabdominal sepsis alters tumor necrosis factor-alpha and interleukin-1 beta binding to human neutrophils. *Crit Care Med* 1992; 20(1): 11-6.
- Wu CC, Liao MH, Chen SJ, Yen MH. Pentoxifylline improves circulatory failure and survival in murine models of endotoxaemia. *Eur J Pharmacol* 1999; 28;373:41-9.
- Krakauer T, Stiles BG. Pentoxifylline inhibits superantigen-induced toxic shock and cytokine release. *Clin Diagn Lab Immunol* 1999; 6:594-8.
- Yang S, Zhou M, Koo DJ, Chaudry IH, Wang P. Pentoxifylline prevents the transition from the hyperdynamic to hypodynamic response during sepsis. *Am J Physiol* 1999; 277:1036-44.
- Curcoy AI, Alcorta I, Estella J, Rives S, Töll T, Tuset E. Cryopreservation of HPCs with high cell concentration in 5-percent DMSO for transplantation to children. *Transfusion* 2002, 42;962.
- Vezin H, Lamour E, Routier S, Villain F, Bailly C, Bernier JL, Catteau JP. Free radical production by hydroxyl-salen manganese complexes studied by ESR and XANES. *J Inorg Biochem* 2002, 25;92: 177.82.
- Schorharting MM, Schade UF. The effect of pentoxifylline in septic shock-new pharmacologic aspects of an established drug. *J Med* 1989; 20(1): 97-105.
- Essani NA, Fischer MA, Jaeschke H. Inhibition of NF-kappaB activation by dimethyl sulfoxide correlates with suppression of TNF-alpha formation, reduced ICAM-1 gene transcription, and protection against endotoxin induced liver injury. *Shock* 1997;7(2):90-6.
- Marinkovic D, Zuyderhoudt FM. Plasma lipid peroxides in murine sepsis-sex differences and effect of antioxidative/anti-inflammatory therapy. *Free Radic Res Commun* 1998;4(4):237-42.
- Pearce RA, Finley RJ, Mustard RA, Duff JH. 2,3 Dihydroxybenzoic acid. Effect on mortality rate in a septic rat model. *Arch Surg* 1985; 120(8):937-40.
- Simpson R, Alon R, Kobzik L, Valeri R, Stepro D, Hechtman HB. Neutrophil and nonneutrophil mediated injury in intestinal ischemia-reperfusion. *Ann Surg*, 1993;218:444-54.
- Schmelting DJ, Caty MG, Oldman KT, Guice KS, Hindshavv DB. Evidence for neutrophil-related acute lung injury after intestinal ischemia-reperfusion. *Surgey* 1989; 106(2): 195-201.
- Van Bebber IPT, Boekholz WKF, Goris RJA et al. Neutrophil function and lipid peroxidation in a rat model of multiple organ failure. *J Surg Res* 1989;47:471-5.
- Bringham KL. Role of free radicals in lung injury. *Chest*; 1986; 89:859-63.

29. Myers MJ, Baarsch MJ, Murtaugh MP. Effects of pentoxifylline on inflammatory cytokine expression and acute pleuropneumonia in swine. *Immunobiology* 2002, 205; 17-34.
30. Galat JA, Robinson A V, Rhodes RS. Oxygen free radical mediated renal dysfunction. *J Surg Res* 1989; 46:520-5.
31. Kajiwara I, Kawamura K, Hiratsuka Y, Takebayashi S. The influence of oxygen free radical scavengers on the reduction of membrane-bound Na-K ATPase activity in-

duced by ischemia/reperfusion injury in canine kidney. *Nephron* 1996; 72:637-43.

Received: July 12, 2002

Correspondence: Sakir TEKIN
Selcuk University Medical Faculty
Department of General Surgery
Konya, TURKEY
drstekin@hotmail.com