

Severe Left Ureterohydronephrosis Due to Giant Bladder Diverticulum in a Patient with Benign Prostatic Hyperplasia: Case Report

Dev Mesane Divertikülü Nedeniyle Sol Üreterohidronefroz Gelişen Benign Prostat Hiperplazili Bir Olgu

Zafer DEMİRER,^a
Bilal Fırat ALP,^b
Ali GÜRAĞAÇ,^b
Hasan Cem İRKİLATA,^b
İbrahim YILDIRIM^b

^aService of Urology,
Eskişehir Military Hospital,
Eskişehir

^bDepartment of Urology,
Gülhane Military Medical Academy,
Ankara

Geliş Tarihi/Received: 13.10.2013
Kabul Tarihi/Accepted: 26.03.2014

Yazışma Adresi/Correspondence:
Zafer DEMİRER
Eskişehir Military Hospital,
Service of Urology, Eskişehir,
TÜRKİYE/TURKEY
zaferdemir@mynet.com

ABSTRACT Bladder diverticula are herniations of the bladder mucosa between fibers of the detrusor muscle, and they can be classified as congenital (primary) and acquired (secondary). They usually occur in older men and its incidence about 12% in patients with obstructive lesions of the lower urinary tract. Although most bladder diverticula are small and asymptomatic, clinically significant bladder diverticula generally have uncommon findings. Accompanying ureterohydronephrosis rarely seen with this pathologic condition of bladder. We herein reported a case of severe left ureterohydronephrosis due to the secondary giant bladder diverticulum caused by benign prostatic hyperplasia in an older man and its surgical treatment by diverticulectomy using a combined intravesical and extravesical approach.

Key Words: Diverticulum; hydronephrosis; prostatic hyperplasia; urinary bladder

ÖZET Mesane divertikülü detrusor kas lifleri arasından mesane mukozasının herniasyonudur, doğumsal (primer) ve kazanılmış (sekonder) olarak sınıflandırılabilir. Genellikle ileri yaş erkeklerde ve alt üriner sistem obstrüksiyonu olan hastalarda yaklaşık %12 sıklığında görülür. Her ne kadar mesane divertikülleri sıklıkla küçük ve asemptomatik olsalar da klinik olarak önem arz eden mesane divertikülleri bazı sıradışı bulgulara neden olabilirler. Mesanenin bu patolojik durumuna üreterohidronefrozun nadiren eşlik ettiği görülür. Biz, bu makalede, yaşlı bir erkekte benign prostat hiperplazisinin neden olduğu dev mesane divertikülüne bağlı ciddi sol üreterohidronefroz olgusunu ve onun intravezikal ve ektravezikal yaklaşım birlikte kullanılarak divertikülektomiyle yapılan cerrahi tedavisini bildirdik.

Anahtar Kelimeler: Divertikül; hidronefroz; prostat hiperplazisi; mesane

Türkiye Klinikleri J Urology 2014;5(1):9-14

Herniation of the bladder urothelium through the muscularis propria of the bladder wall called as bladder diverticula (BD) and these urine-filled structures adjacent to and connecting with the bladder lumen via a narrow neck or ostium.¹ They can be classified as congenital (primary) and acquired (secondary).² Acquired diverticula, mostly multiple and typically accompanies with bladder trabeculation and generally occur after age 60, which is similar with the development of prostatic enlargement.¹ Its incidence is about 12% in patients with obstructive lesions of the lower urinary tract.²

Most BD are small and asymptomatic. However, this uncontractile portion of bladder may lead to large post-voiding residual volume of urine resulting in characteristic clinical findings, including recurrent infections, hematuria and passing of urine twice, once from bladder, followed by emptying of the diverticulum (Pis en deux).¹⁻⁴ Furthermore, clinically significant BD generally have uncommon findings, such as bowel obstruction, unilateral or bilateral ureteral obstruction, spontaneous rupture, venous obstruction, and adult-onset nocturnal enuresis.²⁻⁶ Surgical management is indicated in patients with refractory lower urinary tract symptoms (LUTS), recurrent urinary tract infections (UTIs), stones, ureteral obstruction, cancer in the diverticulum or other complicating factors such as ipsilateral vesicoureteral reflux.^{1,2} Surgical management options of BD currently include open, standard laparoscopic and robot assisted laparoscopic approaches.^{1,7,8}

We herein reported a case of severe left ureterohydronephrosis due to the secondary giant bladder diverticulum (GBD) caused by benign prostatic hyperplasia (BPH) in an older man and its surgical treatment by diverticulectomy using combined intravesical and extravesical approaches.

CASE REPORT

A 73-year-old man referred our clinic for recurrent UTIs history and several voiding complaints under treatment with tamsulosin which were including progressive urinary frequency and a sensation of incomplete bladder emptying. Voiding was reported to be abnormal with a frequency of 10 to 12 times during the day and 4 to 5 times at night. The preoperative International Prostate Symptom Score (IPSS) was 32+5. He also declared his lower abdominal pain, which was continuing since last two years.

On physical examination an abnormal puffiness in left quadrants of the abdomen was palpable and his digital rectal examination revealed a symmetrical enlargement of the prostate gland which was also marked protrusion to the rectal lumen and there was not suspicious of malignancy. Measurement of the urinary flow rates was as follows;

voided volume 280 ml, residual volume 670 ml, peak flow rate 6 ml/sec, mean flow rate 3.4 ml/sec, and voiding time 110 sec. Complete blood count, serum electrolytes, urine sediment and urine culture were normal. His serum creatinine was measured 2.56 mg/dl (normal 0.8 to 1.2) and serum prostate specific antigen (PSA) level was 5.23 ng/ml. He had also history of previous three transrectal ultrasound guided prostate biopsy for his elevated PSA level and the last one was two months before. Ultrasound revealed severe left ureterohydronephrosis and GBD and 177 mL volume of the prostate was measured on transrectal ultrasound.

Voiding cystourethrography (VCUG) revealed a GBD at the left posterolateral side of bladder without vesicoureteral reflux to any renal unit. Non-enhanced computerized tomography (CT) of the abdomen confirmed that the diverticulum was clearly separated from the bladder wall and measured 135x75x130 mL. It was also compressing the distal part of left ureter, and bladder was pushed to the right side of the pelvic cavity by the diverticulum (Figure 1). Urodynamic studies betrayed infravesical obstruction.

The patient received prophylaxis for thromboembolism with low molecule weight heparin; compressive bandage of the legs was performed and 30 minutes before surgery a second generation cephalosporin was given. After the induction of general anesthesia, the patient, firstly, placed in a lithotomy position for cystoscopy. The bladder examined cystoscopically and obstructive prostatic enlargement, heavily trabeculated with multiple cellules bladder floor and a wide mouthed diverticulum located in the left lateral bladder wall identified (Figure 2). Bilateral ureteral orifice could not be visualized because of heavy trabeculation of the bladder floor and inspection of the diverticulum demonstrated neither tumor nor stone formation. Then, sterile indigo carmine applied via intravenous tract and approximately 15 minutes later bilateral ureteral orifices visualized and a 5F ureteral localization stent was placed at cystoscopically in the ipsilateral ureter for better intraoperative identification to prevent ureteral injury.

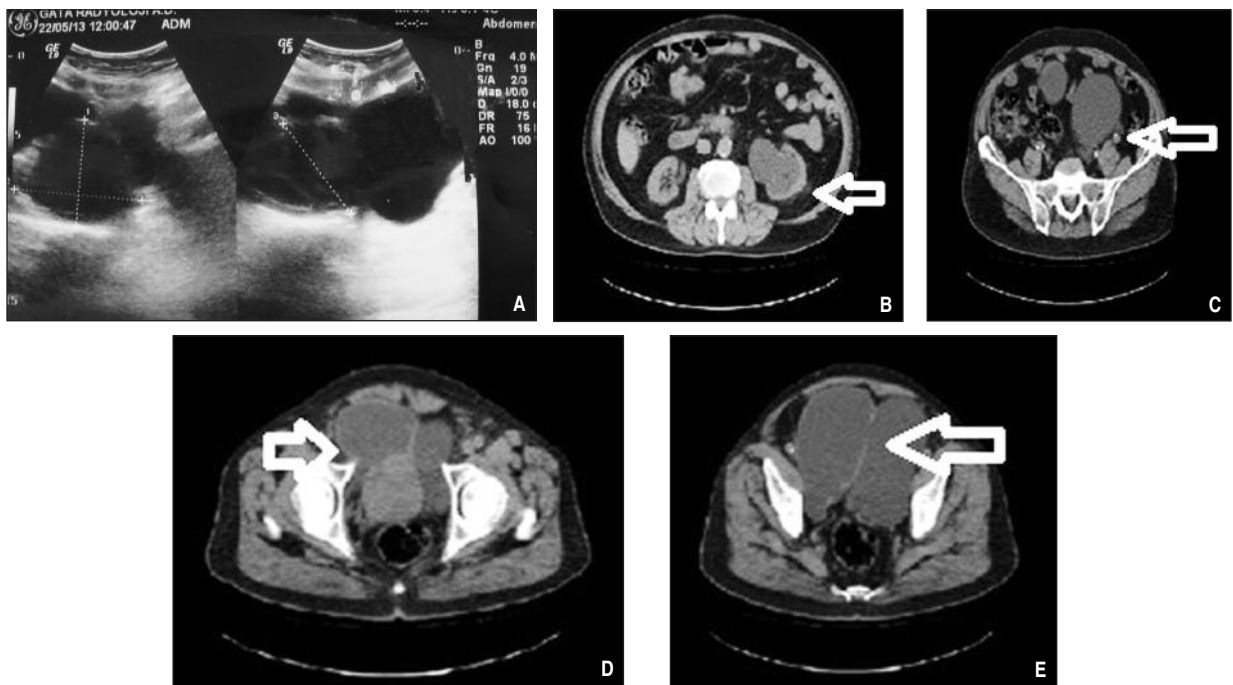


FIGURE 1: A) Bladder diverticulum on ultrasound; the diverticulum extends behind the bladder and has a wide mouth B) Severe left ureterohydronephrosis, C) Compressing of distal part of the left ureter D) Bladder being pushed at the right side of the pelvic cavity E) Diverticular neck.

Then the patient was placed supine position and combined intravesical and extravesical diverticulectomy approaches were used for his GBD through a low midline incision. Transvesical prostatectomy was performed at the same sitting, and reabsorbable sutures were used bladder closure in two layers (Figure 3). The bladder was filled with 120 cc saline via Foley catheter to test the repair, and no leaks were observed. A Jackson-Pratt drain was placed at the end of the surgery. The operating time was 196 minutes, and estimated blood loss was 550 mL. He had a smooth recovery period after surgery, and his hospital stay was 8 days. When he was discharging his creatinine level was 1.63 mg/dL. The pathological specimen demonstrated a BD with chronically inflamed mucosa and BPH. Postoperative 14th day cystogram performed and neither urine leak, nor vesicoureteral reflux was detected. Then catheters withdrawn after performing the cystogram. Postoperative 3rd month peak urinary flow rate was 22 mL. per second with postvoid residual of 20 mL, and the postoperative IPSS was 15+2 compared to 32+5 before the surgical therapy.

DISCUSSION

BD may be classified as either congenital or acquired and this rare condition occurs generally in males and is usually associated with BPH.¹ It is also to come across with secondary to outflow obstruction such as posterior urethral valves, urethral obstruction, prostate cancer, neurogenic bladder dysfunction or vesico-sphincter dyssynergia.⁵

Some residual smooth muscle fibers may exist outside surface of the BD; however, these are uncontractile, because of their disorganized structure and, which finally lead to urinary stasis.³ The large post-voiding residual volume of urine may cause characteristic findings on presentation and imaging.¹ However, their presentation, imaging and pathophysiology may range because of underlying factors.¹ Accompanying ureterohydronephrosis rarely is seen with this pathologic condition of bladder.¹

VCUG is the gold standard for diagnosis of BD, although a diverticulum may be diagnosed inci-

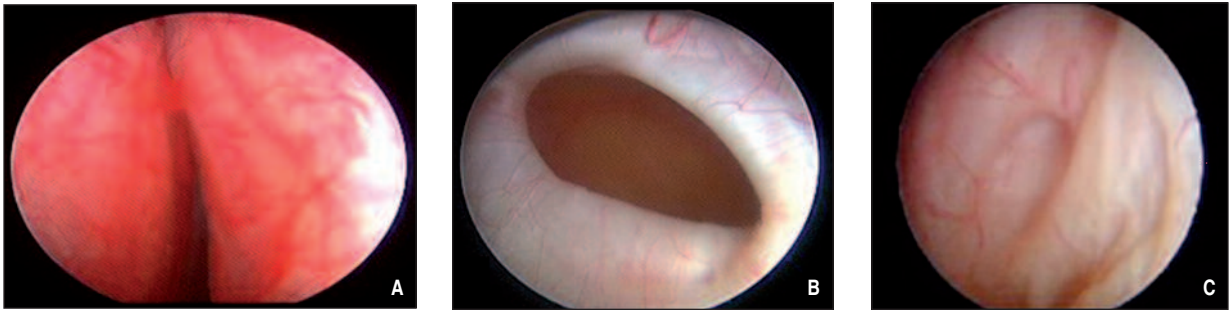


FIGURE 2: A) Obstructive prostatic enlargement B) Wide mouthed diverticulum C) Multiple cellules on the bladder floor.
(See color figure at <http://www.turkiyeklinikleri.com/journal/uroloji-dergisi/1309-632X/>)

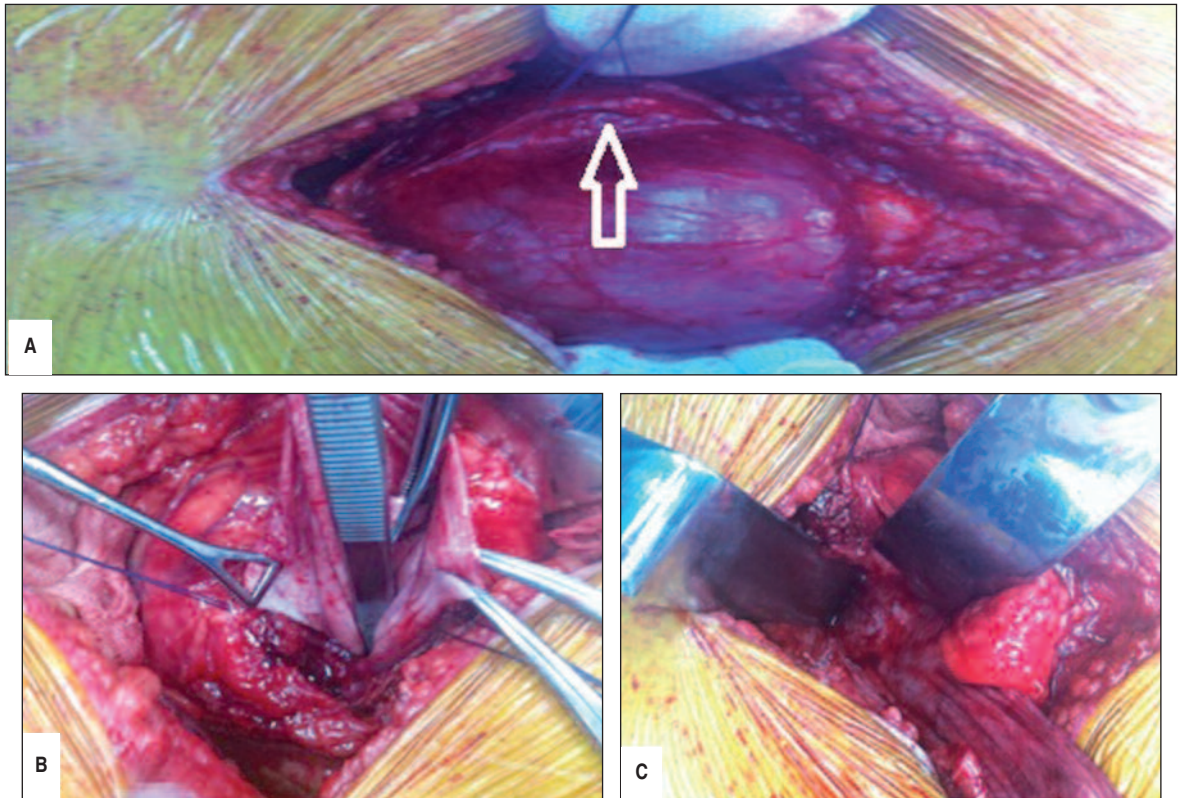


FIGURE 3: A) Diverticulum visualized by saline irrigation, detrusor (arrowhead) remained separate from herniated diverticulum B, C) Combined (intravesical and extravesical) approaches were used for the diverticulum excision.
(See color figure at <http://www.turkiyeklinikleri.com/journal/uroloji-dergisi/1309-632X/>)

dentally on cystoscopy, ultrasonography, urogram and intravenous pyelogram, computed tomography (CT) scans and radionuclide scintigraphy.⁸⁻¹⁰ The mouth of the diverticulum can be occasionally seen on computed tomography as demonstrated by break in the muscle layer of the bladder, CT scanning not only betrays the approximate laterality and location of the diverticulum but also a relationship of the adjacent structures, especially the

ipsilateral ureter and vas deferens can reveal in this imaging.^{9,11} We performed preoperative urodynamic studies and cystoscopy for our patient to reveal his bladder outlet obstruction to assess if he requires any bladder outlet procedure. Cystoscopic inspection not only reveals bladder outlet obstruction but also helpful to determine diverticulum orifice and its proximity to the native ureteral orifices and that can be guided for the surgical planning.¹²

BD is generally small and asymptomatic and do not require any treatment; however, a subset of those lesions grow into large sizes, and a subpopulation of patients develop severe problems, including refractory lower urinary tract symptoms, recurrent UTIs, calculi, urinary retention, ureteral obstruction, malignancy in diverticulum, or even other complicating factors such as concomitant hydronephrosis and ipsilateral vesicoureteral reflux.^{1,2} The first operations for BD were described by Alexander in 1884 and Crezny in 1897, and since then, surgical techniques have been described for the correction of bladder diverticula, and currently these techniques are including open (intravesical, extravesical and combined), endoscopic (fulguration or resection of the diverticular neck), standard laparoscopic (transperitoneal and extraperitoneal) and robot assisted laparoscopic approaches.^{1,2,7,8} On the other hand, there is a general agreement among urologists about to perform outlet procedure at the same setting of BD repairs or after bladder diverticulectomy.¹² Standard laparoscopic and robotic assisted bladder diverticulectomy techniques have not been typically used in patients with a large-size prostate gland.^{8,11} Open bladder diverticulectomy combined with open simple prostatectomy should be appropriate operative option for these patients as we did in our case. Large BD generally will be in close proximity to an ipsilateral ureter, and patients should be informed about the possible additional procedures like ureteral reimplantation and postoperative ureteral stenting. In our case, such procedures were not necessary, probably by means of the measure of intraoperatively inserting a ureteral catheter and stent manipulation for identification of the ureter.¹¹ We identified the diverticulum in our case by filling the bladder with saline via patient's urethral Foley catheter; however, numerous alternative techniques were described to aid the intraoperative identification of the BD such as placing a urethral catheter into the diverticulum and inflating the balloon to 20-30 ml or filling the diverticulum via a diverticular catheter with saline, use of intraoperative fluoroscopy, cystoscopic transillumination of diverticulum or use of intraoperative ultrasonography.^{12,13} We performed interrupted 2-0 vicryl suture in two layers for bladder recon-

struction in our case, also running suture lines have also described to provide successful cystostomy repairs.⁸ Once the closure was complete; bladder was filled with saline to ensure a watertight closure and diverticular sac was sent for pathologic examination. We indwelled him a Foley urethral catheter and suprapubic tube postoperatively to allow the repair to heal under low pressure and avoid persistent urinary leakage. Bladder diverticulectomy complications include the formation of abscess, ureteral injury, vas deferens ligation or devascularization and rectal injuries. Abscess formation must be treated promptly with culture specific antibiotic therapy and ureteral injuries can be managed conservatively with ureteral stent placement or primary repairment depending on the degree of injury.⁹ The vas deferens is at risk especially in young patients and rectal injuries are rarely occurs especially in the repair of posterior diverticula therefore surgeons must be careful when performing diverticular sharp and blunt dissection and also repairment of the diverticula.⁹

In our case, there was a severe left ureterohydronephrosis due to GBD in a patient with BPH, and it is managed by open diverticulectomy and concurrent transvesical prostatectomy. The BD probably developed as a pop-off mechanism secondary to the infravesical obstruction in our case. Similarly, patients with posterior urethral valves and large congenital type BDs have been reported previously.¹⁴ It is possible that this vesico-diverticular reflux prevented the upper urinary tract with avoiding the development of vesicoureteral reflux.¹⁵ However, when the diverticulum reaches such a large size, it obstructs the distal part of the left ureter and worsens the situation with severe left ureterohydronephrosis.

In conclusion, BD is one of the infrequent but clinically challenging urologic abnormalities that may affect not only bladder but also upper urinary tract and kidneys. Surgeons must be aware of patient selection, relief outlet obstruction, diverticulum identification and excision, watertight repair, identification of the ureters and possible postoperative complications; these are all imperative for successful surgery.

REFERENCES

1. Rovner ES. Bladder and female urethral diverticula. In: Wein AJ, Kavoussi LR, Campbell MF, eds. *Campbell-Walsh Urology*. Chapter 78. 10th ed. Philadelphia, PA: Elsevier Saunders; 2012. p.2262-89.
2. Prakash, Rajini T, Kumar Bhardwaj A, VJ, Kalayani Rao P, Singh G. Urinary bladder diverticulum and its association with malignancy: an anatomical study on cadavers. *Rom J Morphol Embryol* 2010;51(3):543-5.
3. Pandey S, Agarwal V, Mishra S, Thakur SK. Bilateral large diverticulae of urinary bladder. *Saudi J Kidney Dis Transpl* 2009;20(3):474-5.
4. Hernando Arteché A, San Jose Manso LA, Olivier Gomez C, Silmi Moyano AN. Bilateral obstructive uropathy secondary to giant peri-ureteral diverticulum. *Case Rep Urol* 2013; 2013:747412. doi: 10.1155/2013/ 747412
5. Torricelli FC, Chueh SC, Shen SJ, Levy DA, Monga M. Hydronephrosis secondary to juxta-ureterovesical junction bladder diverticula. *Urology* 2013;82(3):e26-7.
6. Vaddi S, Pogula VR, Devraj R, Sreedhar AV. Congenital bladder diverticulum-a rare adult presentation. *J Surg Case Rep* 2011;2011(4): 8.
7. Fox M, Power RF, Bruce AW. Diverticulum of the bladder--presentation and evaluation of treatment of 115 cases. *Br J Urol* 1962;34: 286-98.
8. Myer EG, Wagner JR. Robotic assisted laparoscopic bladder diverticulectomy. *J Urol* 2007;178(6):2406-10; discussion 2410.
9. Psutka SP, Cendron M. Bladder diverticula in children. *J Pediatr Urol* 2013;9(2):129-38.
10. Sharma R, Mondal A, Sherigar R, Popli M, Chopra MK, Kashyap R. Giant diverticulum of urinary bladder causing bilateral hydronephrosis in an adult. Diagnostic features on radionuclide scintigraphy. *Clin Nucl Med* 1997; 22(6):385-7.
11. Thiel DD, Young PR, Wehle MJ, Broderick GA, Petrou SP, Igel TC. Robotic-assisted bladder diverticulectomy: tips and tricks. *Urology* 2011;77(5):1238-42.
12. Kural AR, Atug F, Akpınar H, Tufek I. Robot-assisted laparoscopic bladder diverticulectomy combined with photoselective vaporization of prostate: a case report and review of literature. *J Endourol* 2009;23(8):1281-5.
13. Macejko AM, Viprakasit DP, Nadler RB. Cystoscope- and robot-assisted bladder diverticulectomy. *J Endourol* 2008;22(10):2389-91; discussion 2391-2.
14. Hoover DL, Duckett JW Jr. Posterior urethral valves, unilateral reflux and renal dysplasia: a syndrome. *J Urol* 1982;128(5):994-7.
15. Rittenberg MH, Hulbert WC, Snyder HM 3rd, Duckett JW. Protective factors in posterior urethral valves. *J Urol* 1988;140(5):993-6.