

Cataract Surgery and Customized Toric Intraocular Lens Implantation in Patients with Cataract and High Astigmatism After Penetrating Keratoplasty

Penetran Keratoplasti Sonrası Katarakt ve Yüksek Astigmatizması Olan Hastalarda Katarakt Cerrahisi ve Kişiyeye Özel Torik Göz İçi Lens İmplantasyonu

^a Derya DOĞANAY^a, ^b Cem ÇANKAYA^b, ^c Selim DOĞANAY^c

^aÇekirge State Hospital, Clinic of Ophthalmology, Bursa, Türkiye

^bİnönü University Faculty of Medicine, Department of Ophthalmology, Malatya, Türkiye

^cUludağ University Faculty of Medicine, Department of Ophthalmology, Bursa, Türkiye

ABSTRACT Phacoemulsification and implantation of a customized toric intraocular lens (IOL) Acryva BB T UDM 611 was performed in 3 eyes of 3 patients with cataract and more than 13 diopters of astigmatism after penetrating keratoplasty at least 6 months after complete suture removal. Pre- and postoperative uncorrected and corrected visual acuity, manifest refractions, corneal topographies, autorefractometric keratometry values, posterior segment examinations and intraocular pressure measurements were performed in all patients. The corneal astigmatism was a relatively regular bow-tie pattern in all three patients. Astigmatic changes were also evaluated. No complications were observed during surgery or at follow-up. Customized toric IOL implantation seems to be a predictable and safe procedure in patients with cataract and high astigmatism after penetrating keratoplasty. Longer follow-up is required to confirm these predictable clinical results, particularly with regard to IOL misalignment and bag stability.

ÖZET Penetran keratoplasti sonrası kataraktı ve 13 diyoptriden fazla astigmatizması olan 3 hastanın 3 gözüne, sütürlerin tamamen alınmasından en az 6 ay sonra fakoemülsifikasyon ve kişiyeye özelleştirilmiş torik göz içi lensi (GİL) "Acryva BB T UDM 611" implantasyonu yapıldı. Tüm hastaların ameliyat öncesi ve sonrası düzeltilmemiş ve düzeltilmiş görme keskinlikleri, manifest refraksiyonları, kornea topografileri, otorefraktometrik keratometri değerleri, arka segment muayeneleri ve göz içi basınç ölçümleri yapıldı. Ameliyat sonrası ölçümler ve komplikasyonlar kaydedildi. Korneal astigmatizma her üç hastada da nispeten düzenli bir papyon modeliydi. Astigmatik değişiklikler de değerlendirildi. Ameliyat sırasında veya takipte herhangi bir komplikasyon gözlenmedi. Penetran keratoplasti sonrası katarakt ve yüksek astigmatizması olan hastalarda özelleştirilmiş torik GİL implantasyonu öngörülebilir ve güvenli bir prosedür gibi görünmektedir. Bu öngörülebilir klinik sonuçların, özellikle de GİL rotasyonu ve kapsüller bag stabilitesi açısından doğrulanması için daha uzun süreli takiplere ihtiyacı vardır.

Keywords: Penetrating keratoplasty; cataract; customized toric intraocular lens; astigmatism

Anahtar Kelimeler: Penetran keratoplasti; katarakt; kişiyeye özel torik göz içi lensi; astigmatizma

One of the most important refractive problems following penetrating keratoplasty (PK) is astigmatism. Despite a clear graft, post-PK high astigmatism may significantly deteriorate the refractive outcomes.

Studies have reported regular astigmatism in 24% and irregular astigmatism in 72% after PK.¹ One study revealed that cylindrical refractive errors more than 3-4 diopters were not tolerated by patients and

TO CITE THIS ARTICLE:

Doğanay D, Çankaya C, Doğanay S. Cataract surgery and customized toric intraocular lens implantation in patients with cataract and high astigmatism after penetrating keratoplasty. Türkiye Klinikleri J Ophthalmol. 2024;33(2):128-32.

Correspondence: Cem ÇANKAYA

İnönü University Faculty of Medicine, Department of Ophthalmology, Malatya, Türkiye

E-mail: cem_cankaya@yahoo.com



Peer review under responsibility of Türkiye Klinikleri Journal of Ophthalmology.

Received: 07 Dec 2023

Received in revised form: 12 Mar 2024

Accepted: 18 Mar 2024

Available online: 22 Mar 2024

2146-9008 / Copyright © 2024 by Türkiye Klinikleri. This is an open access article under the CC BY-NC-ND license (<http://creativecommons.org/licenses/by-nc-nd/4.0/>).

that binocular vision was affected as a result of high anisometropia.² Many refractive methods such as laser in situ keratomileusis, photorefractive keratectomy, astigmatic keratotomy, wedge resection, corneal ring, traction suture have been described for the treatment of astigmatism after PK.³⁻⁶ However, these methods have low predictability and can cause serious complications. Although there are a limited number of publications in the literature on cylindrical toric intraocular lens (IOL) implantations of more than 13 diopters, there are no publications regarding the plate haptic foldable IOL implantation in these values, which we used in our cases.

CASE REPORT

Three patients with cataract who had previously undergone PK were included. All participants gave informed consent before the study and the tenets of the Declaration of Helsinki were followed. In all three cases the grafts were clear. None of the cases had undergone refractive or other ophthalmic surgery after PK. Complete suture removal took at least 6 months. The corneal astigmatism was a relatively regular bow-tie pattern (Figure 1).

Preoperative uncorrected and corrected visual acuity, manifest refractions, corneal topographies (ObScan

2, Bausch & Lomb Surgical), autorefractometry keratometry values, IOL master 500 (Carl Zeiss Meditec, Germany) keratometry values, posterior segment examinations and intraocular pressure measurements were performed in all patients. Pre- and postoperative cylinder magnitudes and axes were used to calculate vectorial analyses including target induced astigmatism vector, surgically induced astigmatism vector, difference vector and correction index of the cases using the AstigMATIC software program (Figure 2).⁷

The spherical calculation of the toric IOL was performed using the IOL Master 500, and the cylindrical and axial calculations were performed using the recommended calculation formula on the IOL manufacturer’s website (www.easytoriccalculator.com-AcrivaUD Easy Toric Calculator software for calculation of refractive power recommended by VSY Biotechnology BV). Customized intraocular lenses manufactured by the same company were implanted in all cases (Acriva BB T UDM 611, VSY Biotechnology, Türkiye). IOL power was calculated using the Haigis and SRK-T formulae together with keratometry values obtained from the IOL Master 500 and corneal topography.

All surgeries were performed by a single surgeon through a 2.2 mm clear corneal incision using a

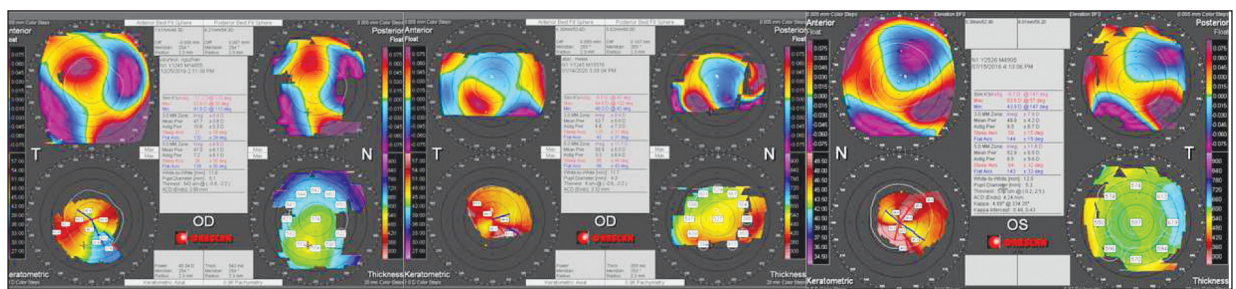


FIGURE 1: Preoperative corneal topography of the case 1, case 2 and case 3, respectively.

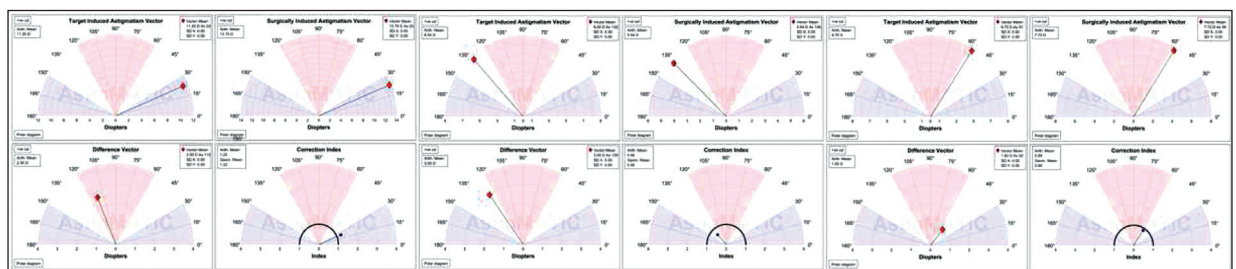


FIGURE 2: Vectorial analysis of the case 1, case 2 and case 3, respectively.

standard phaco procedure under topical anaesthesia. The limbus was marked at 3-9 and 6-12 o'clock with a coloured edge spatula using the slit lamp light just before surgery. Fourteen, 17 and 16 dioptres Acriva BB T UDM 611 (VSY Biotechnology, Türkiye) intraocular lenses were implanted at 25, 120 and 60 degrees axis, respectively. Cataract surgery was performed without any complications.

Pre- and postoperative ocular measurements, demographic characteristics and anterior segment photographs of the patients are shown in Table 1 and Figure 3.

A total of 3 patients with a mean age of 43±12.5 years were included in the study. Pre- and postoperative demographic and ocular characteristics of the patients are shown in Table 1. Mean BCVA was logMAR 1.2±0.17 preoperatively and increased to logMAR 0 postoperatively. The mean spherical equivalent was 1.8±0.66 diopters at 1 month postoperatively. The mean corneal astigmatism was 2.2±1.04 diopters and the mean manifest refraction was 0.8±0.14 diopters in the first postoperative month. In the first postoperative month, near vision was at J1 level with +1.00 diopter correction in 2 cases and at J1 level without correction in the other case. The mean IOL rotation at 1 month was 6.0±2.0 degrees. These rotation values were measured with the toriCAM (Apple iOS) smartphone application at 1 month postoperatively.

DISCUSSION

In the treatment of high astigmatism after PK, both ciliary sulcus-placed toric IOLs in pseudophakic cases and customized foldable IOLs combined with cataract surgery have been reported to be safe and effective. In the same study, the authors reported successful results with the use of a foldable three-piece silicone IOL with Z-shaped haptics and sharp-edged optic (Torica-s IOL, Humanoptics, Erlangen, Germany) for 12.63 and 12.67 diopters of corneal astigmatism in 2 of the cases.⁸ However, this IOL requires a 3.5 mm corneal incision due to its design and has the potential to cause surgical astigmatism. However, these toric intraocular lenses are now available in a foldable C-loop shape and hydrophilic acrylic one-piece cylinder up to 30 diopters and it has become possible to implant them through smaller incisions. The toric IOL used in our study has a plate haptic shape and can be implanted into the capsule through a 2.2 mm corneal incision using an injector system. Therefore, surgical astigmatism was minimized with a 2.2 mm corneal incision.

Swampillai et al. reported very successful results in patients with more than 3 dioptres of astigmatism after PK and also with ocular comorbidities.⁹ de Sanctis et al. reported successful results using a customized foldable hydrophilic T-flex 623T toric IOL in three patients with astigmatism between 6.75 and 8.75 diopters after PK.¹⁰ As mentioned above, successful results can be achieved both after PK surgery and with high regular astigmatism occurring for any reason with the use of customized toric in-

TABLE 1: Ocular and demographic characteristics of the cases.

P	Age	Gender	Dx	Preop BCVA	Preop AR	Preop MR	Int (month)	Preop BCVA	Mean Preop k		Cyl power of implanted IOL	Final visit AR (Postop 1 month)	MR (Postop 1 month)	Postop BCVA (Postop 1 month)	Periop complication	Postop Near BCVA	Type of cataract	Postop IOL rotation amount (Postop 1 month)
									eratomic cyl (topographic data)	eratometric cyl								
1	23	M	KC	LogMar 1.3	error	-5.00	6	LogMar 1.3	11.2	10.74	15.50	-2.50x22°	-0.75	LogMar 0	-	J1(+)	PSC	4°
2	43	M	KC	LogMar 1.3	error	-3.50	14	LogMar 1	8.5	9.31	13.50	-3.00x35°	-0.75	LogMar 0	-	J1(+)	PSC	8°
3	20	M	KC	LogMar 1	error	-4.00	132	LogMar 0.5	8.7	9.96	14.50	-1.50-1.00x142	-1.00-0.75x140	LogMar 0	-	J1	PSC	6°

Dx: Diagnosis; BCVA: Best corrected visual acuity; AR: Auto keratb-refractometer; MR: Manifest refraction; IOL: Intraocular lens; KC: Keratoconus.

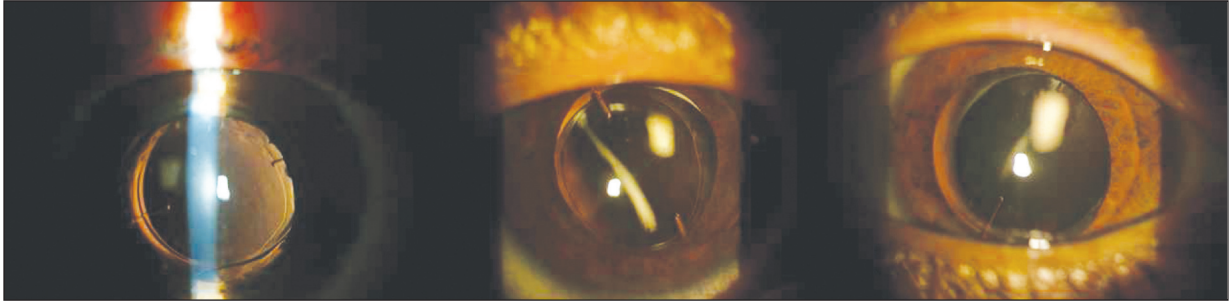


FIGURE 3: Anterior segment photograph of the case 1, case 2 and case 3 with toric intraocular lens, respectively.

traocular lenses produced by some companies in different designs and materials. In our study, we obtained very successful results in 3 post-PK cases with regular corneal astigmatism using a plate-haptic toric IOL made of hydrophilic acrylic material (Acryva UDM T 611, cylindrical values of the cases were 15,5, 13,5 and 14,5 diopters, respectively). In the range of intraocular lenses we use, there is a cylindrical production of up to 10 dioptres. The company has made these lenses for our cases in a special production.

The rotation that can occur after implantation of a toric IOL can cause a change in cylindrical power. Small rotations do not affect the astigmatic power, but larger rotations reduce the power of the IOL, for example, the correction effect is eliminated when the IOL is rotated more than 30 degrees.¹¹ Therefore, larger rotations, generally 10 degrees, require surgical intervention to reposition the IOL.¹² In our cases an average rotation of 6° on the axis was observed during the follow-up periods. The plate haptic structure of the lens and its contact with the capsule at 4 points may have been effective in this condition.

Pellegrini et al. reported a mean BCVA of 20/25 after cataract and toric IOL implantation in a series of 37 patients who underwent DALK and PK.¹³ In the study by Lackington et al, 20/40 BCVA was achieved in 93.3% of patients after cataract and toric IOL implantation in patients performed DALK and PK, while in the study by Wade et al, 20/30 BCVA was achieved in 90% of patients after PK.^{14,15} In our case report study, although the number of patients was much smaller, 20/20 BCVA was achieved in the post-operative period.

There are increasingly effective techniques for managing corneal astigmatism at the time of cataract surgery. Careful preoperative and intraoperative assessment of corneal astigmatism using new technologies is likely to improve surgical outcomes for astigmatic correction in cataract surgery. The role of toric IOLs will become more important with time. In conclusion, we believe that in cases of high, relatively regular astigmatism and cataract after PK, customized toric intraocular lenses are a good option for postoperative refractive status. Considering that our results were obtained at 1 month postoperatively, it should be known that longer follow-up periods are needed, in particular for IOL rotation and capsular stability.

Source of Finance

During this study, no financial or spiritual support was received neither from any pharmaceutical company that has a direct connection with the research subject, nor from a company that provides or produces medical instruments and materials which may negatively affect the evaluation process of this study.

Conflict of Interest

No conflicts of interest between the authors and / or family members of the scientific and medical committee members or members of the potential conflicts of interest, counseling, expertise, working conditions, share holding and similar situations in any firm.

Authorship Contributions

Idea/Concept: Selim Doğanay; **Design:** Derya Doğanay; **Control/Supervision:** Selim Doğanay, Cem Çankaya; **Data Collection and/or Processing:** Derya Doğanay, Cem Çankaya; **Analysis and/or Interpretation:** Derya Doğanay; **Literature Review:** Derya Doğanay, Cem Çankaya; **Writing the Article:** Derya Doğanay; **Critical Review:** Selim Doğanay; **References and Fundings:** Derya Doğanay, Cem Çankaya.

REFERENCES

1. Karabatsas CH, Cook SD, Sparrow JM. Proposed classification for topographic patterns seen after penetrating keratoplasty. *Br J Ophthalmol.* 1999;83(4):403-9. [[Crossref](#)] [[PubMed](#)] [[PMC](#)]
2. Brooks SE, Johnson D, Fischer N. Anisometropia and binocularity. *Ophthalmology.* 1996;103(7):1139-43. [[Crossref](#)] [[PubMed](#)]
3. Drouglazet-Moalic G, Levy O, Goemaere I, Borderie V, Laroche L, Bouheraoua N. Deep Intrastromal Arcuate Keratotomy With In Situ Keratomileusis (DIAKIK) for the Treatment of High Astigmatism After Keratoplasty: 2-Year Follow-up. *J Refract Surg.* 2019;35(4):239-46. [[Crossref](#)] [[PubMed](#)]
4. Bandeira E Silva F, Hazarbassanov RM, Martines E, Güell JL, Hofling-Lima AL. Visual outcomes and aberrometric changes with topography-guided photorefractive keratectomy treatment of irregular astigmatism after penetrating keratoplasty. *Cornea.* 2018;37(3):283-9. [[Crossref](#)] [[PubMed](#)]
5. Ghanem RC, Azar DT. Femtosecond-laser arcuate wedge-shaped resection to correct high residual astigmatism after penetrating keratoplasty. *J Cataract Refract Surg.* 2006;32(9):1415-9. [[Crossref](#)] [[PubMed](#)]
6. Koay PY, McGhee CN, Crawford GJ. Effect of a standard paired arcuate incision and augmentation sutures on postkeratoplasty astigmatism. *J Cataract Refract Surg.* 2000;26(4):553-61. [[Crossref](#)] [[PubMed](#)]
7. Gauvin M, Wallerstein A. AstigMATIC: an automatic tool for standard astigmatism vector analysis. *BMC Ophthalmol.* 2018;18(1):255. [[Crossref](#)] [[PubMed](#)] [[PMC](#)]
8. Srinivasan S, Ting DS, Lyall DA. Implantation of a customized toric intraocular lens for correction of post-keratoplasty astigmatism. *Eye (Lond).* 2013;27(4):531-7. [[Crossref](#)] [[PubMed](#)] [[PMC](#)]
9. Swampillai AJ, Khanan Kaabneh A, Habib NE, Hamer C, Buckhurst PJ. Efficacy of toric intraocular lens implantation with high corneal astigmatism within the United Kingdom's National Health Service. *Eye (Lond).* 2020;34(6):1142-8. Erratum in: *Eye (Lond).* 2020;: PMID: 31844167;: PMC7253472. [[Crossref](#)] [[PubMed](#)] [[PMC](#)]
10. de Sanctis U, Eandi C, Grignolo F. Phacoemulsification and customized toric intraocular lens implantation in eyes with cataract and high astigmatism after penetrating keratoplasty. *J Cataract Refract Surg.* 2011;37(4):781-5. [[Crossref](#)] [[PubMed](#)]
11. Felipe A, Artigas JM, Díez-Ajenjo A, García-Domene C, Alcocer P. Residual astigmatism produced by toric intraocular lens rotation. *J Cataract Refract Surg.* 2011;37(10):1895-901. [[Crossref](#)] [[PubMed](#)]
12. Rubenstein JB, Raciti M. Approaches to corneal astigmatism in cataract surgery. *Curr Opin Ophthalmol.* 2013;24(1):30-4. [[Crossref](#)] [[PubMed](#)]
13. Pellegrini M, Furioli L, Yu AC, Giannaccare G, Scuteri G, Gardeli I, et al. Outcomes of cataract surgery with toric intraocular lens implantation after keratoplasty. *J Cataract Refract Surg.* 2022;48(2):157-61. [[Crossref](#)] [[PubMed](#)]
14. Lockington D, Wang EF, Patel DV, Moore SP, McGhee CN. Effectiveness of cataract phacoemulsification with toric intraocular lenses in addressing astigmatism after keratoplasty. *J Cataract Refract Surg.* 2014;40(12):2044-9. [[Crossref](#)] [[PubMed](#)]
15. Wade M, Steinert RF, Garg S, Farid M, Gaster R. Results of toric intraocular lenses for post-penetrating keratoplasty astigmatism. *Ophthalmology.* 2014;121(3):771-7. [[Crossref](#)] [[PubMed](#)]