

Surgically Treated Foreign Body Ingestion in a Psychiatric Patient

BİR PSİKİYATRİ HASTASINDA CERRAHİ OLARAK TEDAVİ EDİLMİŞ YABANCI CİSİM ALIMI

Burhan EYÜPOĞLU*, Teoman COŞKUN*, Erhan REİS*, Hasan YAVUZ*, Mutlu DOĞANAY*, Nuri Aydın KAMA*

* 4th Department of Surgery, Ankara Numune Hospital, Ankara, TURKEY

Summary

Foreign body ingestion seen in adults usually occurs in psychiatric patients. We report a case of abundant foreign body ingestion of a 31-year-old, psychiatric male patient who was admitted to the hospital with abdominal pain, nausea and vomiting. Foreign bodies were detected on abdominal X-ray. Following gastrotomy, 179 nails and 2 coins were taken out of the stomach. Since the patient had a giant benign ulcer located at the lesser curvature, a subtotal gastrectomy was performed. He recovered uneventfully and was discharged without symptoms.

Key Words: Foreign body ingestion

T Klin J Med Sci 1998, 18:136-137

Özet

Yetişkinlerde yabancı cisim alımı genellikle psikiyatri hastalarında görülür. Karın ağrısı, bulantı ve kusma şikayeti ile hastaneye başvuran ve devamlı yabancı cisim alma öyküsü olan 31 yaşında erkek psikiyatri hastasını yayınladık. Yabancı cisimler, direk abdominal grafide saptandı. Gastrotomiye takiben 179 çivi ve 2 vida mideden çıkarıldı. Hastaya küçük kurvattürde yer alan benign ülseri nedeniyle subtotal gastrektomi yapıldı. Ek sorun çıkmaksızın hasta iyileşti ve taburcu edildi.

Anahtar Kelimeler: Yabancı cisim alımı

T Klin Tıp Bilimleri 1998, 18:136-137

The first case of foreign body ingestion reported in the literature was a man who swallowed a knife in 1602 (1). In 1896, Benno Crede published an account of the removal of 26 foreign bodies from the stomach through gastrotomy (1). In the United States of America, 1500 people die annually of ingested foreign bodies of the upper gastrointestinal tract (2). Ingested foreign bodies are most commonly encountered in the pediatric age group, followed by edentulous adult prisoners, and psychiatric patients. Herein, a case of foreign body ingestion, which was treated surgically, is reported.

Case Report

A 35-year-old male patient was admitted to the emergency department with the complaints of ab-

dominal pain, nausea and vomiting. On the plain abdominal X-ray, radioopaque materials suggesting nail located at the lower abdomen were seen (Fig. 1). It was learned from his relatives that he was a psychiatric patient and had swallowed these nails within one week, about three months ago. On the physical examination, a painful mass was palpated on epigastrium. There were no signs of abdominal guarding and rebound tenderness. On laparotomy, the stomach was found to be dilated and located in the pelvis. Following gastrotomy, 179 nails of different sizes (range 6-12 cm) and two coins were taken out of the stomach. Nails were in irregular shape and their total weight was 440 g. Additionally, a giant benign ulcer (5 cm in diameter) located on the lesser curvature of the stomach was found during the evacuation of the foreign bodies. A biopsy obtained from the ulcer reported as benign on frozen section. Following truncal vagotomy and Billroth II resection, abdomen was closed. The patient recovered uneventfully and was discharged without symptoms. On his follow up it

Geliş Tarihi: 10.12.1996

Yazışma Adresi: Dr.Nuri Aydın KAMA
6. Cadde 29/2
06500 Bahçelievler, ANKARA

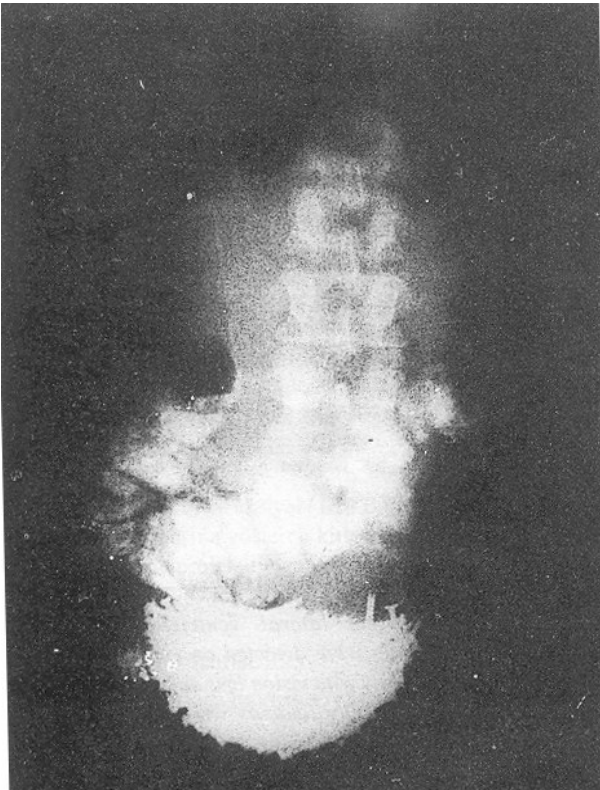


Figure 1. Metallic foreign bodies seen on the abdominal X-ray.

was learned from his relatives that he went on eating foreign material, especially cloths at this time.

Discussion

In general, foreign bodies are found in several distinct groups of patients: 1) children who ingest toys, coins, and etc., 2) psychologically deranged people who repetitively ingest objects ranging from coins, nails, pins, and small tools to paper and cloth, 3) workmen who accidentally ingest tools such as nails, screws, tacks, or even small batteries in the course of their work, and 4) a group of patients who ingest medical appliances such as dentures, partial plates, and tubes during treatment (3).

There is little question that the overwhelming majority (80-90%) of ingested foreign bodies pass through the stomach after some period and are eventually excreted. Of the foreign bodies that remain in the stomach, a considerable number (10-20%) can be removed via endoscope. Only relatively

small number of patients (1%) require operative removal of gastric foreign bodies. These patients usually ingested an enormous number of objects that cause secondary mechanical gastric outlet obstruction (4).

As many as 2533 foreign bodies have been reported in the stomach of a single patient (5). In our patient, 181 foreign bodies were found in the stomach. The length of the swallowed foreign material is the most important factor which predict the lodgment of the material in the stomach. Koch (6) stated that objects thicker than 2 cm and longer than 5 cm tend to lodge in the stomach. In the present case, all of foreign bodies were longer than 5 cm.

Recurrent episodes of foreign body ingestion may occur, especially in prisoners, psychiatric patients, and patients with peptic strictures with a rate of 2.7-10% (7, 8). Similarly, we observed recurrent attacks in our patient.

Although foreign body ingestion into the gastrointestinal tract is a rare entity, it should be kept in mind in the differential diagnosis of the abdominal masses and acute abdomen, especially in psychiatric patients.

REFERENCES

1. Herrington JL Jr. Historical aspects of gastric surgery. In: Scott HW Jr, Sawyers JL, eds. Surgery of the stomach, duodenum, and small intestine. Boston: Blackwell, 1992: 1-28.
2. Schwartz GF, Polsky HS. Ingested foreign bodies of the gastrointestinal tract. *Am Surg*, 1976, 42: 236-38.
3. Sachatello CR. Benign gastric tumors, foreign bodies, and bezoars. In: Scott HW Jr, Sawyers JL, eds. Surgery of the stomach, duodenum, and small intestine. Boston: Blackwell, 1992: 376-91.
4. Webb WA. Management of foreign bodies of the upper gastrointestinal tract. *Gastroenterology*, 1988, 94: 204-16.
5. Chalk SG, Faucher H. Foreign bodies in the stomach. *Arch Surg* 1928; 16: 494-500.
6. Koch H. Operative endoscopy. *Gastrointest Endosc* 1977; 24: 65-8.
7. Rosenow EC. Foreign bodies of the esophagus. In: Payne WS, Olsen AM, eds. The esophagus. Philadelphia: Lea & Febiger, 1974: 159-70.
8. Webb WA, Mc Daniel L, Fones L. Foreign bodies of the upper gastrointestinal tract: current management. *South Med J*, 1984; 77: 1083-6.