

# Asymptomatic Giant Pericardial Cyst Next to Right Atrium: Case Report

## Sağ Atriyuma Komşu Asemptomatik Dev Perikardiyal Kist

Hüseyin ŞAŞKIN,<sup>a</sup>  
Mustafa İDİZ,<sup>b</sup>  
Hüseyin MAÇIKA,<sup>c</sup>  
Çağrı DÜZYOL<sup>a</sup>

<sup>a</sup>Clinic of Cardiovascular Surgery,  
Derince Training and Research Hospital,  
Clinics of

<sup>b</sup>Cardiovascular Surgery,

<sup>c</sup>Anaesthesiology and Reanimation,  
Private Acıbadem Hospital,  
Kocaeli

Geliş Tarihi/Received: 26.08.2014

Kabul Tarihi/Accepted: 24.10.2014

Yazışma Adresi/Correspondence:

Hüseyin ŞAŞKIN

Derince Training and Research Hospital,  
Clinic of Cardiovascular Surgery, Kocaeli,  
TÜRKİYE/TURKEY

sueda\_hs@yahoo.com

**ABSTRACT** The incidence of pericardial cysts among all mediastinal masses is 7% approximately. Mediastinal cysts are lesions which may be found in children as well as adults. The ratio of these usually congenital lesions to all mediastinal space occupying lesions is 20-32%. A 28 years old male patient without any complaint was referred to cardiology clinic with a mass image in direct thorax x-ray imaging during routine control for appointment for a job. Cardiologic examination, transthoracic and transoesophageal echocardiography and computerized tomography imaging revealed a giant pericardial cyst next to the right atrium. The cyst was surgically excised with success. In this report, we aimed to present an interesting case of a giant pericardial cyst, which was asymptomatic despite its size and location.

**Key Words:** Pericardium; cysts; surgery

**ÖZET** Perikardiyal kistlerin tüm mediastinal kitleler içinde görülme insidansı yaklaşık %7'dir. Mediastinal kistler erişkinler kadar çocuklarda da görülebilir. Genellikle doğumsal olan bu lezyonların tüm mediastinal yer kaplayıcı kitlelere oranı %20-32 arasındadır. 28 yaşında, herhangi bir yakınması olmayan erkek hasta, iş başvurusu için yapılan rutin tetkikler sırasında, direkt toraks grafisinde saptanan bir kitle görüntüsü nedeniyle kardiyoloji kliniğine yönlendirilmiş. Kardiyolojik muayene, transtorasik ve transözofageal ekokardiyografi ve bilgisayarlı tomografi görüntülemeleri ile sağ atriyuma komşu dev perikardiyal kist saptandı. Kist, cerrahi olarak başarılı bir şekilde eksize edildi. Bu yazıda, büyüklüğüne ve yerleşim yerine rağmen asemptomatik olan ilginç bir dev perikardiyal kist olgusunu sunmayı amaçladık.

**Anahtar Kelimeler:** Perikard; kistler; cerrahi

Türkiye Klinikleri J Cardiovasc Sci 2014;26(3):128-32

Mediastinal cysts are lesions which may be found in children as well as adults. Despite the fact that these lesions are usually congenital with a rate of 20-32% among all mediastinal space occupying lesions, they are often detected after the second decade of life since most of the cases remain asymptomatic.<sup>1</sup> The incidence of pericardial cysts among all mediastinal masses is 7% approximately.<sup>2</sup> One third of the mediastinal cysts in the adults are pericardial cysts, however they are not seen in childhood very often. Pericardial cysts are formations which are usually asymptomatic, benign in nature, round and uniform. They are often detected during routine studies like chest radiography or tomography, and usually located on the cardiophrenic angle, especially on the right side.<sup>3</sup> These lesions usually have a

thin wall containing a clear fluid component and they are held by a region of pericardium.<sup>4</sup> Due to their relation with pericardium, they are named as pericardial diverticulum.<sup>5</sup> They may be confused with Morgagni hernias for their location. Pericardial fat tissue, benign and malign pathologies of diaphragm, coronary artery aneurysms should be kept in mind for differential diagnose. For these mostly asymptomatic lesions, cardiac compression, arrhythmia, bleeding inside the cyst, cardiac tamponade following cyst rupture, pulmonary compression and retrosternal discomfort are very rare. These lesions, which are seen as well bounded radioopacities on bilateral cardiophrenic sinuses with direct chest x-ray, may be evaluated better with computerized tomography (CT) and magnetic resonance imaging (MRI) and their interference with surrounding tissues may be understood. Differential diagnose should be made with other pathologies originating from pleura as well as Morgagni hernias, for which tomography is helpful.<sup>6</sup> The suggested therapeutic approaches for pericardial cystic lesions are excision and aspiration. There is a common opinion that aspiration is an insufficient therapy in mediastinal cysts, and all of these cysts should be completely excised regardless of their origin. Since their malignancy potential is very low, these lesions may comfortably be excised with sternotomy, thoracotomy or video assisted thoracoscopic surgery. Mortality and morbidity are almost none.<sup>7</sup> In the recent presentation, we report a case of an atypically located giant pericardial cyst which was asymptomatic although it was located next to the right atrium.

## CASE REPORT

28 years old male patient was referred to cardiology clinic with increased cardiothoracic ratio detected with direct thorax x-ray imaging during routine control for appointment for job. The cardiologic examination revealed an ejection fraction of 60% with normal ventricle and valvular structure and functions and a cyst formation of 15 x 10 cms full of fluid located next to the right atrium without any connection to atrium or ventricle. Following further examination with transoesophageal echocardiography and coronary angiography, decision for an operation

was made since the cystic structure was found not to have any connection with the cardiac chambers. The patient's physical examination was normal. 12 lead electrocardiography was normal. There was a mass image showing equivalent opacity to the heart located at the right paracardiac area (Figure 1A). Using CT with intravenous contrast, a mass was detected in the size of 15 x 10 cms with a thin and uniform wall structure which was in the density of a homogenous and hypodens fluid, located in the right inferior portion of the anterior mediastinum, connected to the surface of the pericardium on the right inferior side next to the right atrium (Figure 1B).

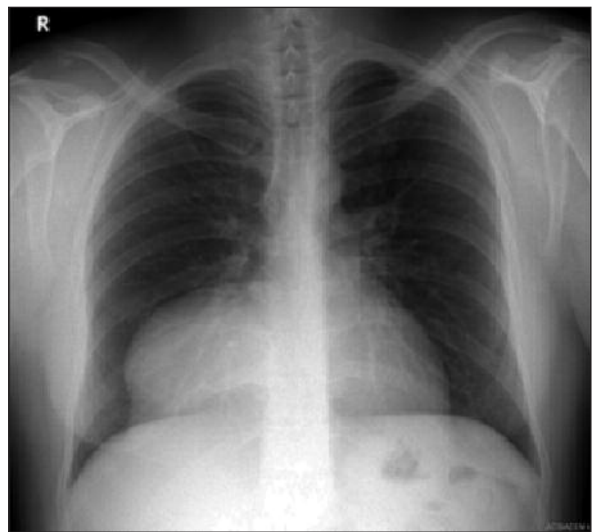


FIGURE 1A: Preoperative posteroanterior direct chest x-ray image.

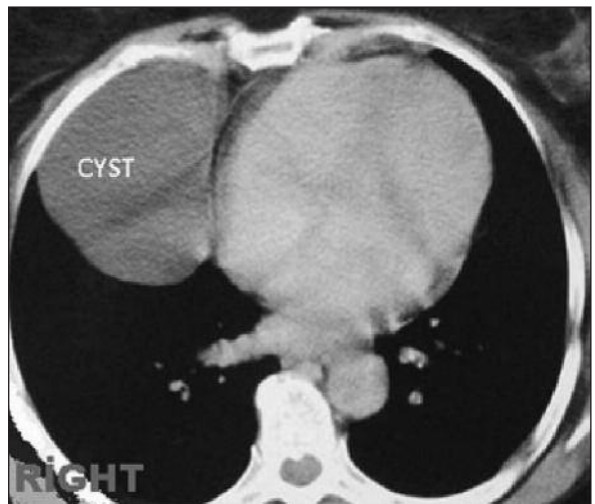
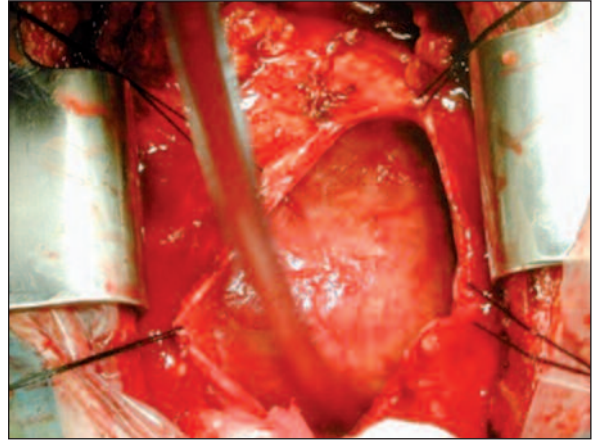


FIGURE 1B: Preoperative computerized tomographic image. A mass of 15 x 10 cms is seen next to pericardium.

Whole blood analyze and biochemical tests including metabolic components of the patient were normal. The radiologic images were consulted with the thoracic surgery department with suspicious extrapericardial localization and the cyst was decided to exist in the pericardial cavity, therefore open surgery was suggested. Written informed consent was obtained and the patient was operated with these findings. Mediastinum was reached with median sternotomy under general anaesthesia. Following pericardiotomy, the mass in the same size and location shown in previous CT, which was connected to the right inferior pericardial surface elongated to the right pleura, was explored (Figure 2A). Without any need for cardiopulmonary bypass, the mass and right inferior portion of the pericardium was opened and liberated from the surrounding adhesions and without any rupture of the cyst, the mass was totally excised together with the pericardial patch which it was in connection with (Figure 2B). The cystic fluid was yellow and clear, and the internal surface of the cyst wall was pink-white and uniform with macroscopic examination. The microscopic examination showed a fibrous wall including mononuclear inflammatory cells and a single layer squamous epithelium. Pathologic diagnose was a pericardial cyst (Figure 2C). The operation ended uneventfully and the patient was taken to the intensive unit without any problems. The follow-up period was uneventful. The patient was extubated on the 3rd postoperative hour. His total drainage was 200 ml. The direct x-ray imaging on the 1st postoperative day revealed the loss of the previous mass image on the right paracardiac area (Figure 3). Control transthoracic echocardiography on the 4th postoperative day showed normal cardiac functions, loss of mass image and no pericardial effusion. The patient was discharged from hospital on the 5th postoperative day.

## DISCUSSION

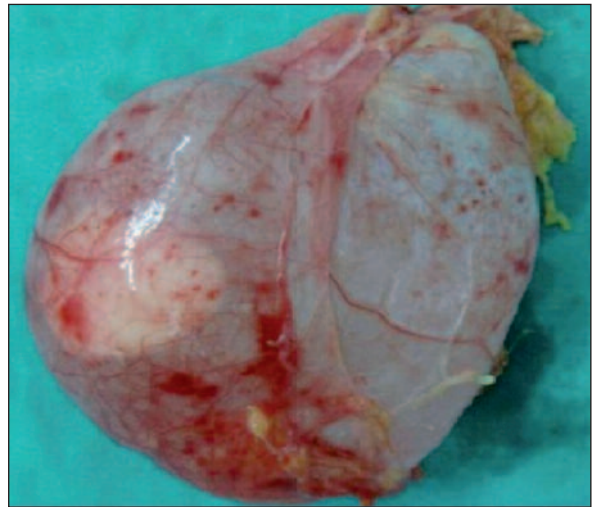
Pericardial cysts are rare and usually benign lesions. About one in every 100.000 individuals may have a pericardial cyst.<sup>8</sup> They may not be clinically significant unless they reach to great sizes. Peri-



**FIGURE 2A:** Peroperative image of the pericardial cyst during operation held by the right inferior pericardium.

(See color figure at

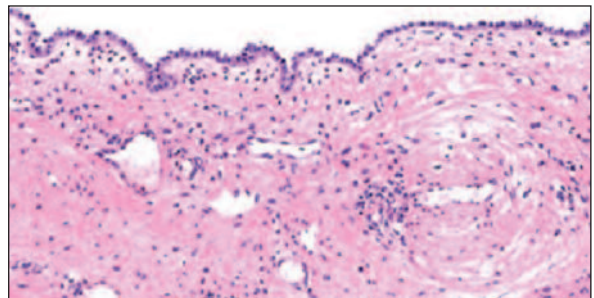
<http://www.turkiyeklinikleri.com/journal/cardiovascular-sciences/1306-7656/>)



**FIGURE 2B:** Excised pericardial cyst.

(See color figure at

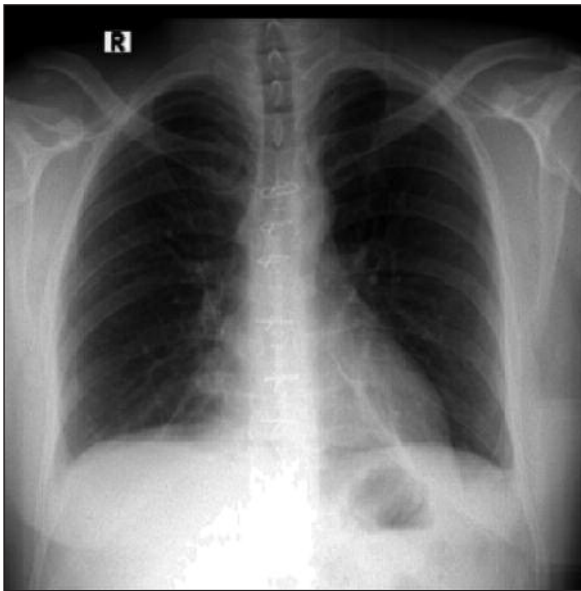
<http://www.turkiyeklinikleri.com/journal/cardiovascular-sciences/1306-7656/>)



**FIGURE 2C:** Hematoxylin and eosin (H & E) stain  $\times 100$ , Microscopic image of the excised cyst wall which shows a fibrous wall including mononuclear inflammatory cells and a single layer squamous epithelium.

(See color figure at

<http://www.turkiyeklinikleri.com/journal/cardiovascular-sciences/1306-7656/>)



**FIGURE 3:** Posteroanterior direct chest x-ray image in the first postoperative day.

cardial cysts are believed to exist due to aberrant fusion of anterior pericardial recess. They may originate from diaphragm or anterior pericardium but are rarely related to pericardial sac.<sup>7</sup>

Pericardial cyst locations in thorax show heterogeneity, however the most frequent locations are reported as the right (70%) and left (22%) cardiophrenic angles in the anterior mediastinum.<sup>9</sup> There is a 8 to 10% possibility of an atypical location. Atypical locations are reported much often recently which may suggest improvements in diagnostic studies.

Pericardial cysts are usually asymptomatic, therefore the diagnosis is coincidental.<sup>10,11</sup> Symptoms occur in 20% of the patients; these may vary in a broad spectrum from nonspecific symptoms like dyspnea, cough or chest pain to severe symptoms due to compression of the cyst to surrounding organs like cardiac failure, hemorrhage or herniation.<sup>12</sup> Atypically located pericardial cysts may become symptomatic according to their growth rate or compression to surrounding tissues.<sup>3</sup> In this case, the patient had no symptoms.

Pericardial cysts should be distinguished from angioma, lipoma, neurogenic tumors, sarcoma, lymphoma, various solid masses like metastatic

and bronchogenic tumors, granulomatous lesions, hydatid cyst, oesophageal lesions and abscess. Lateral direct chest X-ray imaging is an efficient method for differential diagnose of masses particularly localized in the paravertebral area like our case. Bronchogenic cysts, foregut cysts and lymphangiomas are other types of cysts to be distinguished from pericardial cysts. Furthermore, diaphragmatic and hiatal hernia, aneurysms of the heart and major vessels may mimic the image of pericardial cyst. Especially, combination of imaging methods may be beneficial in differential diagnose for atypically localized or complicated cases.<sup>9</sup> Rarely, symptoms like dyspnea, cough, hypotension, tachycardia and cardiac tamponade may become prominent regarding the surrounding sites of compression.<sup>10</sup>

Pericardial cyst diameters are reported to vary from 3 to 30 cms in the literature. Karlıkkaya had presented a case of which a cyst with a 22 cms diameter was excised.<sup>13</sup>

Diagnosis for pericardial cysts are usually made coincidentally with studies like direct x-ray imaging, echocardiography, CT and MRI.<sup>11</sup>

Surgical excision is the primary therapy for pericardial cysts which can be done with low morbidity and mortality rates. Many authors suggest complete excision of the cyst even for asymptomatic patients. Esmen and colleagues reported successful results of surgical excision with low morbidity, mortality and recurrence rates in their study. Recently, minimally invasive techniques are applied with increasing frequency for cyst excision. Transtracheal or percutaneous cyst aspirations have been tried as an alternative to surgery, however these have not been widespread acceptable due to possible cyst recurrence and increased morbidity.<sup>14</sup> A case of pericardial cyst operated with mediastinoscopy was reported by Yazici and colleagues in 2010 which introduced an alternative excision method for cysts localized in the paratracheal area. Operations with VATS are also performed with increasing frequency in the recent years which are applied with success for cases of pericardial cyst.



Despite a rare possibility of complications in pericardial cysts, severe complications have been reported in the literature.<sup>14</sup> Complications may occur due to increase in cyst size for cases which have not been surgically managed. These include hemorrhage, hemodynamic instability and cardiac tamponade due to spontaneous intrapericardiac rupture of the cyst, cardiac herniation and infection of the cyst.<sup>15</sup>

In conclusion, pericardial cysts are benign and completely curable lesions with surgical management which carries low morbidity and mortality. These lesions may become evident with various symptoms regarding their location. They should be operated when detected before a serious complication occurs due to growth to an enormous size, and malignancy should be sought with histobiochemical study of the excision material.

## REFERENCES

1. Takeda S, Miyoshi S, Minami M, Ohta M, Masaoka A, Matsuda H. Clinical spectrum of mediastinal cysts. *Chest* 2003;124(1):125-32.
2. Sugita T, Yasuda R, Magara T, Nishikawa T, Katsuyama K, Hanaoka J. Pericardial cyst in the midline position. *J Cardiovasc Surg (Torino)* 1994;35(1):87-8.
3. Güler M, Toker ME, Eren E, Özdemir A, Yakut C. [Atypically located pericardial cyst causing pulmonary hypertension]. *Türk Toraks Derg* 2006;7(3):209-11.
4. Lillie WI, McDonald JR, Clagett OT. Pericardial celomic cysts and pericardial diverticula; a concept of etiology and report of cases. *J Thorac Surg* 1950;20(3):494-504.
5. Kutlay H, Yavuzer I, Han S, Cangir AK. Atypically located pericardial cysts. *Ann Thorac Surg* 2001;72(6):2137-9.
6. Jost RG, Sagel SS, Stanley RJ, Levitt RG. Computed tomography of the thorax. *Radiology* 1978;126(1):125-36.
7. Strollo DC, Rosado-de-Christenson ML, Jett JR. Primary mediastinal tumors: part II. Tumors of the middle and posterior mediastinum. *Chest* 1997;112(5):1344-57.
8. Hoover P, Maisin J, Lacquet A. Congenital pleuro-pericardial cysts. *Thorax* 1963;18(2):146-50.
9. Feigin DS, Fenoglio JJ, McAllister HA, Madewell JE. Pericardial cysts. A radiologic-pathologic correlation and review. *Radiology* 1977;125(1):15-20.
10. Gür Ö, Gürkan S, Gür Özkaramanlı D, Ege T. [Symptomatic giant pericardial cyst: Case report]. *Journal of Adnan Menderes University Medical Faculty* 2013;14(2):25-6.
11. Yekeler E, Gündoğdu C. Giant pericardial cyst causing compression atelectasis of the lower lobe. *Turkish Journal of Thoracic and Cardiovascular Surgery* 2009;17(2):129-31.
12. Yazıcıoğlu A, Bıçakçıoğlu P, Yekeler E, Yazıcı Ü, Karaoğlanoğlu N. [Pericardial cysts: Analysis of 41 cases]. *J Clin Anal Med* 2013;4(5):369-71.
13. Kaklıkkaya I. A giant pericardial cyst. *Cardiovasc J Afr* 2011;22(6):e1-3.
14. Esmel H, Eren S, Sezer M, Solak O. Primary mediastinal cysts: clinical evaluation and surgical results of 32 cases. *Tex Heart Inst J* 2011;38(4):371-4.
15. Yazıcı Ü, Ege T, Gülhan E, Tastede İ. A case of pericardial cyst with an atypical location (Paratracheal) which was removed by mediastinoscopy. *Türk Toraks Derg* 2010;11(4):184-6.