

# A Case Report of Giant Adrenal Myelolipoma with Beta-Thalassemia: Removal by Retroperitoneal Laparoscopic Approach

## Beta Talasemili Olguda Dev Adrenal Miyelolipomun Retroperitoneal Laparoskopik Yöntemle Çıkarılması

Cemil AYDIN,<sup>a</sup>  
 Ramazan TOPAKTAŞ,<sup>a</sup>  
 Aykut AYKAÇ,<sup>b</sup>  
 Zeynep Banu AYDIN,<sup>c</sup>  
 Ali AKKOÇ,<sup>a</sup>  
 Mahir KARTALMIŞ,<sup>a</sup>  
 Erdem KISA,<sup>d</sup>  
 M. Uğur ALTUĞ<sup>d</sup>

Clinics of,  
<sup>a</sup>Urology,  
<sup>b</sup>Radiology,  
 Diyarbakır Training and  
 Research Hospital,  
<sup>c</sup>Clinic of Urology,  
 Ergani State Hospital, Diyarbakır  
<sup>d</sup>Clinic of Urology,  
 Dışkapı Yıldırım Beyazıt Training and  
 Research Hospital, Ankara

Geliş Tarihi/Received: 02.07.2013  
 Kabul Tarihi/Accepted: 01.12.2013

Yazışma Adresi/Correspondence:  
 Aykut AYKAÇ  
 Ergani State Hospital,  
 Clinic of Urology, Diyarbakır,  
 TÜRKİYE/TURKEY  
 aykutdr@gmail.com

**ABSTRACT** Myelolipoma is an uncommon, mostly nonfunctioning and benign tumor composed of adipose tissue and normal hematopoietic elements. It is most often found in the adrenal glands. Most lesions are small, unilateral and asymptomatic, discovered incidentally at autopsy or on imaging studies performed for other reasons. 39-year-old female patient, known type 2 diabetes mellitus and thalassemia major on treatment presented with nonspecific right flank pain since 2 months. On evaluation, she was found to have a large right adrenal myelolipoma. The patient underwent a successful resection under retroperitoneal laparoscopic surgery. Histopathological examination of surgical specimen confirmed the diagnosis of adrenal myelolipoma.

**Key Words:** Adrenal incidentaloma; adrenal gland neoplasms; laparoscopy

**ÖZET** Miyelolipoma yağ dokusu ve normal hematopoetik yapılar içeren, nadir görülen, çoğunlukla nonfonksiyone benign tümörlerdir. Miyelolipoma çoğunlukla adrenal bezde görülür. Çoğu tümör küçük, iyi huylu, tek taraflı ve asemptomatiktir, tesadüfen otopside ya da başka sebeplerden dolayı yapılan görüntülemeler sırasında tespit edilir. Tanıya yardımcı olması için ultrason, bilgisayarlı tomografi ve manyetik rezonans gibi farklı görüntüleme teknikleri kullanılabilir. Bilinen tip 2 diyabeti ve talasemi majör hastalığı olan 39 yaşındaki kadın hasta son iki aydır spesifik olmayan sağ yan ağrısı ile başvurdu. Yapılan incelemelerde büyük bir sağ adrenal miyelolipoma tespit edildi. Tümör retroperitoneal laparoskopik cerrahi ile başarılı bir şekilde çıkarıldı. Histopatolojik incelemede adrenal miyelolipoma tanısı doğrulandı.

**Anahtar Kelimeler:** Adrenal insidentalom; adrenal bez tümörleri; laparoskopi

**Türkiye Klinikleri J Urology 2013;4(3):147-50**

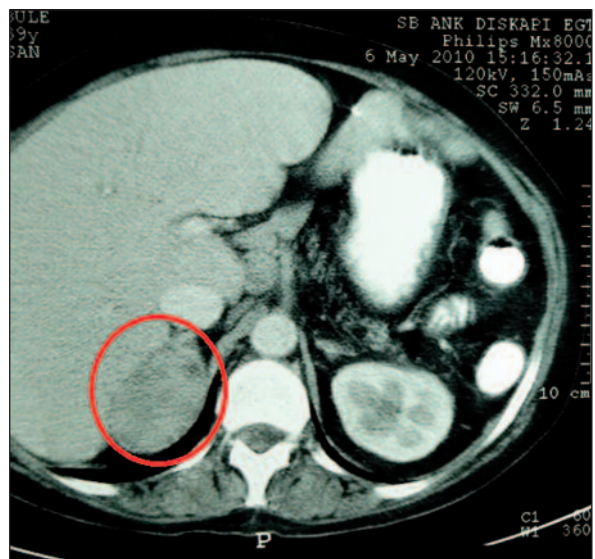
**A**drenal myelolipomas are uncommon, benign, non-functional tumours, including different amounts of mature adipose tissue and normal hematopoietic elements. They are usually small, unilateral, and asymptomatic even if their sizes are massive. Adrenal myelolipomas are usually reported in older age and affect both females and males, equally. Before new imaging techniques, they were determined only at autopsy with an incidence of 0.08% to 0.2%.<sup>1</sup> Today, they are detected much more frequently and incidentally, constituting up to 10-15% of incidental adrenal masses because of the more common use of modern imaging studies.<sup>2</sup> Their prevalence seems to be rising up to 10% with the modern imaging techniques.<sup>3</sup> We describe a case of symptomatic adrenal myelolipoma in a female with a history of splenectomy,  $\beta$ -thalassemia major and diabetes mellitus.

This is the third case of adrenal myelolipoma with  $\beta$ -thalassemia major, in our knowledge.

## CASE REPORT

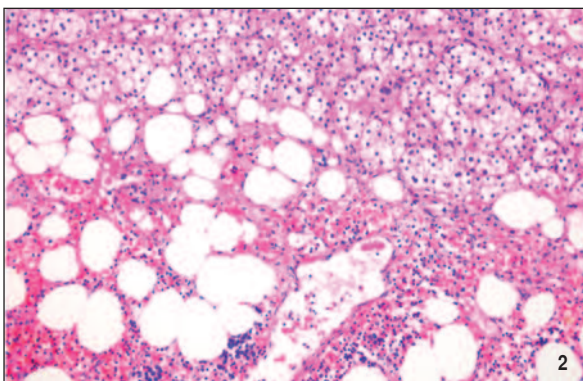
A 39-year-old female with type 2 diabetes mellitus,  $\beta$ -thalassemia major and prior splenectomy, was admitted to our clinic complaining right lumbar pain for the last 2 months. She had lost approximately 10 kg of weight over a 3-year period. The patient was asymptomatic, with no need of transfusion for the last nine years, and stable levels of haemoglobin: 12 g/dL and haematocrit: 35%. On physical examination, there were no positive findings. During the ultrasonography (US) well demarcated mass, with a maximum diameter of 8.5-cm was detected. Contrast-enhanced computed tomography and magnetic resonance imaging revealed a large heterogeneous enhancing soft tissue density lesion in the right adrenal region, measuring 48x82x70 mm (Figure 1). There was no detected lymphadenopathy. Endocrine evaluation was done which included serum catecholamine, serum cortisol, serum dopamine, testosterone levels, 17-ketosteroid and urinary vanillylmandelic acid levels; all were within normal limits. From the clinical history, physical examination and laboratory results, there was no evidence to suggest the patient had a metabolic disorder, associated with adrenal tumours, like hyperaldosteronism, Cushing's syndrome and catecholamine hypersecretion.

The patient had a clinically non-functional adrenal incidentaloma. Retroperitoneal laparoscopic adrenalectomy was performed. At surgery, the mass was totally dissected from the right kidney and excised. The procedure took approximately 1.5 hours and was associated with no transfusion requirement. The macroscopic examination of specimen measured 5x7x8 cm and weighed 147 g surrounded by a thin capsule. The cut section showed a yellowish appearance, well-differentiated fat as well as areas of haemorrhage. The lesion arose from the adrenal gland and consisted of ex-



**FIGURE 1:** Adrenal myelolipoma CT image.

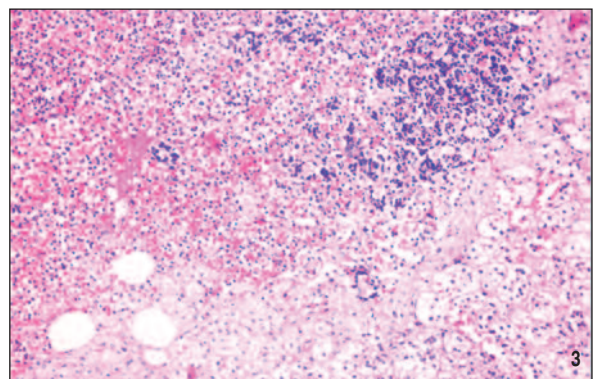
(See color figure at <http://www.turkiyeklinikleri.com/journal/uroloji-dergisi/1309-632X/>)



**FIGURE 2,3:** Lipocytes and bone marrow elements in adrenal cortex (HE x200).

Microscopical findings: Adult fat tissue containing active bone marrow elements was observed in neighborhood of non-neoplastic adrenal cortex. Immunohistochemical examination demonstrated Leucocyte common antigen (LCA) positivity in myeloid cells throughout the tumor.

(See color figure at <http://www.turkiyeklinikleri.com/journal/uroloji-dergisi/1309-632X/>)



tramedullary haematopoietic tissue including myeloid cells and mature adipocytes in the common areas of haemorrhage. These findings suggested the diagnosis of a myelolipoma (Figure 2, 3). There was no evidence of malignancy. The patient had an uneventfully postoperative course and was discharged on postoperative day 3. Six months after surgery, patient was pain free, and no recurrent mass was seen on computed tomography.

## DISCUSSION

Adrenal myelolipomas are relatively rare, usually asymptomatic, biochemically non-functioning and benign tumors composed of variable amounts of mature adipose tissue and hematopoietic elements resembling bone marrow. The tumor was first described by Gierke in 1905, and later given the name "myelolipoma" by Oberling in 1929.<sup>4</sup> The tumor mostly affects patients in their fifth and seventh decades of life with incidence in autopsy studies vary from 0.03-0.2%.<sup>1</sup> They generally get noticed incidentally during imaging studies of abdomen or in autopsy hence referred to as "incidentaloma". Male and females are equally affected and right sided lesions are more common.<sup>5</sup>

The aetiology and pathogenesis of adrenal myelolipoma remains unclear; various theories have been proposed including degeneration of the epithelial cells of the adrenal cortex, embolism of bone marrow cells, metaplasia of mesenchymal cells and autonomous proliferation of bone marrow cells during embryogenesis.<sup>4</sup> The diseases characterized by chronic haemolysis such as thalassemia, hereditary spherocytosis and sickle cell anaemia are often related to adrenal myelolipomas and they are also possible that hematopoietic stimulus by chronic anaemia of thalassemia might induce compensatory haematopoiesis in the adrenal gland. There is a documented association of myelolipoma and thalassemia that has been previously reported by Kelekis.<sup>6</sup> Extramedullary adrenal haematopoiesis may contribute to the pathogenesis of adrenal myelolipomas. The association of myelolipoma with obesity, hypertension, chronic disease and malignancies has been described.<sup>2</sup> Our patient's comorbidity was diabetes mellitus and thalassemia major.

Adrenal myelolipomas are usually asymptomatic however giant tumors may cause compressive symptoms and may present with palpable mass, haematuria, nonspecific flank and abdominal pain probably due to haemorrhage.<sup>7</sup> Our patient presented with lumbar pain and weight loss.

Adrenal myelolipoma is mostly diagnosed imaging procedures performed for other purposes. Magnetic resonance imaging (MRI), ultrasound (US) and computed tomography (CT) are effective in diagnosing more than 90% of adrenal myelolipomas based on identification of fat, with CT being the most sensitive.<sup>2</sup> The classic myelolipoma is radiolucent on plain films and avascular on angiography. US is a cheap and rapid imaging method for diagnosis showing hyperechoic image in lipid rich tumors while tumors with predominant myeloid cells appear hypoechoic. Our patient also performed US and CT.

A fatty adrenal mass is diagnostic of myelolipoma with a possible differential diagnosis of adrenal adenoma, teratoma, angiomyolipoma, lipoma and retroperitoneal sarcoma. In case a diagnosis has not been established, fine needle biopsy can be helpful to definitely rule out malignancy. Endocrine dysfunction is occasionally reported and usually occurs due to underlying adrenocortical pathology.<sup>8</sup> In our case, all functional hormones of adrenal gland had been checked and revealed no specific findings.

The management of adrenal myelolipomas should be individualised. When the tumor is 4 cm or smaller and asymptomatic, should be followed up over 6-12 months period with US or CT. A symptomatic lesion or a large >5 cm myelolipoma should be excised as spontaneous rupture of the lesion with haemorrhage is possible. If laparoscopic expertise is available, then the excision is done laparoscopically. We prefer the extraperitoneal laparoscopic approach rather than an open extraperitoneal incision and a midline incision because this procedure minimizes postoperative pain, earlier return to normal activity, improved cosmesis, lower hospital costs and leads to quicker recovery. However, it is not indicated for masses larger

than 10 cm or with adhesions and infiltration of the surrounding structures.<sup>9</sup>

Simultaneous thalassemia major and adrenal myelolipoma is rare. Surgery is indicated for symp-

tomatic, large, hormonally active myelolipomas or if malignancy is suspected. Physician should be aware about radiological imaging findings may exist between malignant tumors and myelolipomas.

## REFERENCES

1. Mukherjee S, Pericleous S, Hutchins RR, Freedman PS. Asymptomatic giant adrenal myelolipoma. *Urol J* 2010;7(1):66-8.
2. Daneshmand S, Quek ML. Adrenal myelolipoma: diagnosis and management. *Urol J* 2006;3(2):71-4.
3. Tyrizis SI, Adamakis I, Migdalis V, Vlachodimitropoulos D, Constantinides CA. Giant adrenal myelolipoma, a rare urological issue with increasing incidence: a case report. *Cases J* 2009;2:8863. doi: 10.4076/1757-1626-2-8863.
4. Wilhelmus JL, Schrodtt GR, Alberhasky MT, Alcorn MO. Giant adrenal myelolipoma: case report and review of the literature. *Arch Pathol Lab Med* 1981;105(10):532-5.
5. Lam KY, Lo CY. Adrenal lipomatous tumours: a 30 year clinicopathological experience at a single institution. *J Clin Pathol* 2001;54(9):707-12.
6. Kelekis NL, Alexopoulou E, Brountzos EN, Ladis V, Boussioutou A, Kelekis DA. Giant adrenal myelolipoma with minimal fat content in a patient with homozygous beta-thalassemia: appearance on MRI. *J Magn Reson Imaging* 2003;18(5):608-11.
7. Patel VG, Babalola OA, Fortson JK, Weaver WL. Adrenal myelolipoma: report of a case and review of the literature. *Am Surg* 2006;72(7):649-54.
8. Zieker D, Königsrainer I, Miller S, Vogel U, Sotlar K, Steurer W, et al. Simultaneous adrenal and extra-adrenal myelolipoma - an uncommon incident: case report and review of the literature. *World J Surg Oncol* 2008;6:72. doi: 10.1186/1477-7819-6-72.
9. Kenney PJ, Wagner BJ, Rao P, Heffess CS. Myelolipoma: CT and pathologic features. *Radiology* 1998;208(1):87-95.