

Low-Grade Tubulopapillary Adenocarcinoma of Sinonasal Tumors: Diagnosis and Follow-up

Sinonazal Tümörlerden Düşük Dereceli Tübülopapiller Adenokarsinomu: Tanı ve Takip

Özkan MİLOĞLU^a, Muhammet Enes NARALAN^a, Gözde DERİNDAG^b, Sare SİPAL^c

^aDepartment of Oral, Dental and Maxillofacial Radiology, Atatürk University Faculty of Dentistry, Erzurum, TURKEY

^bDepartment of Oral, Dental and Maxillofacial Radiology, Pamukkale University Faculty of Dentistry, Denizli, TURKEY

^cDepartment of Pathology, Surgical Sciences, Atatürk University Faculty of Dentistry, Erzurum, TURKEY

ABSTRACT Low grade tubulopapillary adenocarcinoma is one of the rare sinonasal tumors. A 65-year-old male patient was admitted to our clinic with painless intraoral and extraoral swelling and speech disorder. Radiological examination of the patient revealed a lesion suggesting malignancy. The area of the lesion spread from the left maxillary area to the maxillary sinus, nasal cavity, zygomatic bone and the base of the eye, causing resorption of the bones in the regions. As a result of biopsy, the lesion was diagnosed as well-differentiated low-grade tubulopapillary adenocarcinoma. The patient was referred to the oncology department of the medical faculty and the radiotherapy was started by the medical faculty board, indicating that it was not suitable for surgical treatment. After 1.5-year follow-up, the patient was re-biopsied and diagnosed as poorly differentiated tubulopapillary adenocarcinoma. We think that the aggressive lesion may show heterogeneous differentiation as a possible reason for the differentiation between the two biopsies.

ÖZET Düşük dereceli tübülopapiller adenokarsinom, çok nadir görülen sinonazal tümörlerden birisidir. Altmış beş yaşında erkek hasta, kliniğimize ağrısız intraoral ve ekstraoral şişlikle beraber konuşma bozukluğu şikâyetiyle başvurmuştur. Yapılan radyolojik muayenede, malignite düşündürülen lezyon görülmüştür. İlgili lezyon alanı sol maksiller alandan başlayarak, sol maksiller sinüs, nazal kavite, zigoma ve göz tabanına kadar yayılmış olup, bölgedeki kemiklerde ileri seviyede rezorpsiyona sebebiyet vermiştir. Yapılan immünokimyasal tetkikler sonucunda lezyona, iyi diferansiye düşük dereceli tübülopapiller adenokarsinom tanısı konmuştur. Hasta; tıp fakültesi onkoloji servisine yönlendirilmiş ve yapılan konsültasyonlar sonucu cerrahi tedavi için uygun olmadığı bildirilerek, radyoterapiye başlanmıştır. Hastanın 1,5 yıllık takibinden sonra tekrar biyopsi alınmıştır ve biyopsi sonucunda kötü diferansiye gösteren tübülopapiller adenokarsinom teşhisi konulmuştur. İki biyopsi arasında diferansiyasyon farkının olmasının muhtemel sebebi, ilk teşhis anında “düşük dereceli” olan yüksek yıkılım gösteren lezyonun, farklı diferansiye alanları bulundurmasından kaynaklandığı düşünülmektedir.

Keywords: Low grade tubulopapillary adenocarcinoma; sinonasal tumors; ultrasonography; magnetic resonance imaging

Anahtar Kelimeler: Düşük dereceli tübülopapiller adenokarsinom; sinonazal tümörler; ultrasonografi; manyetik rezonans görüntüleme

Nasal and sinonasal neoplasms are about 0.4% of all tumors seen in humans and 46% of sinonasal tumors are squamous cell carcinoma, 14% are malignant lymphoma, 13% are adenocarcinoma and 13% are malignant melanoma.¹

Non-intestinal type adenocarcinomas (NIAC) are classified under the heading of adenocarcinomas in the nasal cavity, paranasal sinuses and skull base tumors in the World Health Organization (WHO) classification. It is one of the tumors with morpho-

Correspondence: Özkan MİLOĞLU

Department of Oral, Dental and Maxillofacial Radiology, Atatürk University Faculty of Dentistry, Erzurum, TURKEY/TÜRKİYE

E-mail: omiloglu@hotmail.com



Peer review under responsibility of Türkiye Klinikleri Journal of Dental Sciences.

Received: 05 Oct 2020

Received in revised form: 18 Nov 2020

Accepted: 21 Nov 2020

Available online: 12 Feb 2021

2146-8966 / Copyright © 2021 by Türkiye Klinikleri. This is an open access article under the CC BY-NC-ND license (<http://creativecommons.org/licenses/by-nc-nd/4.0/>).

logy showing heterogeneous images and therefore has many synonyms. These synonyms are; terminal tubulus adenocarcinoma, tubulopapillary low-grade adenocarcinoma, low-grade adenocarcinoma, seromucinous adenocarcinoma, renal cell-like carcinoma.² NIAC can be low-grade NIAC (LNIAC) or can be seen as high-grade NIAC (HNIAC).²

LNIAC is very rare and they are seen in a very wide age range but most patients are around 6th decade of their lives.^{1,2} HNIAC is rarely seen in a wider age range and more aggressive than LNIAC.^{1,3-10} LNIAC and HNIAC have no known etiology and LNIAC's prognosis is better than HNIAC.¹⁻⁶

In the case that we want to present, the patient was diagnosed with LNIAC which is a higher chance of life and our patient died after 2 years of follow-up. By sharing the follow-up information, we want to reveal how important early diagnosis and correct treatment are for patients with a tumor known to be long in life and not receiving the necessary treatment.

CASE REPORT

A 65-year-old male patient applied to our clinic in January 2018 for severe swelling in the palatal area. As a result of the examination made to the patient who applied to the outer center for a millimeter-sized swelling in the same area in 2016, the teeth in the left maxillary posterior region are extracted after prescribing antibiotics for dental infection. After the extraction procedure, the patient states that the swelling has never passed and has grown increasingly. When his speech becomes impaired 6 months after the first extraction, he applies to our clinic.

He has been retiring and living alone since he lost his wife 5 years ago. The patient who smoked 2 packs of cigarettes a day stated that he did not use any alcohol and drugs during his life. The patient had myocardial infarction 2 years ago and he uses antihypertensive and anticoagulant drugs. Informed consent form was obtained from the patient.

In extraoral examination, there was asymmetry in the left zygoma region due to expansion. In the intraoral region, poor oral hygiene and expansion in the left palatal region were observed. On intra-oral examination, there were multiple fistula-like openings

on the lesion and they were covered with a mucous fluid (Figure 1). The swelling in the left zygoma region was rubbery on palpation and bone tissue was not felt in any way. In the intraoral expansion region, fluctuation and tissue in the consistency of the rubbery were felt. No lymphadenopathy was observed in the patient during palpation examination.

In the radiological examination of the patient, orthopantomography was first taken. In the radiograph, perforated bone image, in which the left sinus integrity, especially the sinus anterior wall, could not be fully observed (Figure 2). In conical beam computed tomography (NewTom FP QR-DVT 9000, 110 kVp, 15 mA, 36 s scan time, 5.4 s typical X-ray emission time, 17 cm diameter-13 cm height scan volume, Verona, Italy) it was clearly seen that most of the palatal area were resorbed. Resorption with complete loss of aeration was observed in all the walls of the left maxillary sinus and in most of the left and right ethmoid sinuses. The left zygoma bone of the patient cannot be traced. The lesion area, showing isodensity with soft tissue, extended to the medial wall of the right maxillary sinus (Figure 3). In extraoral and intraoral ultrasonography (USG) (Toshiba Aplio 300, Toshiba Medical Systems Corpo-

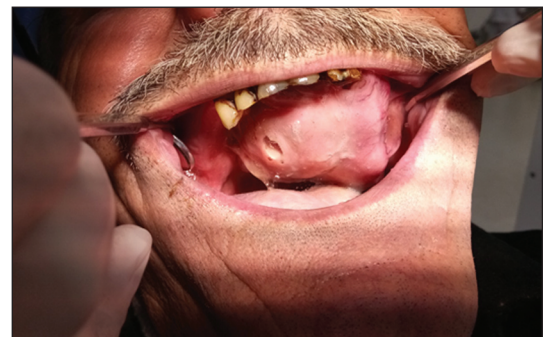

FIGURE 1: Intraoral picture of the patient at the first admission.

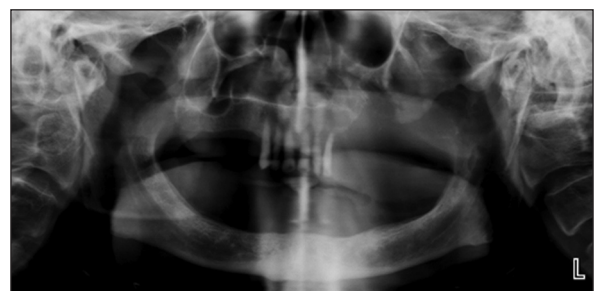

FIGURE 2: Panoramic view of the patient.

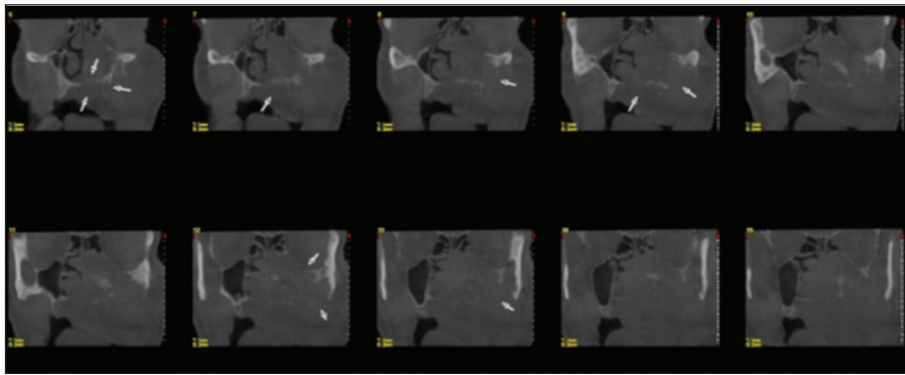


FIGURE 3: Cone beam computed tomography examination of the patient.

ration, Tokyo, Japan), in the submucosal localized, irregularly bounded, anechoic nature, containing hyperechoic foci in the left maxillary sinus region and in the palatal region, containing perforation and expansion in the bone was observed. The lesion size could not be measured because of the size. In addition, peripheral blood supply was observed in color Doppler USG examination (Figure 4). In the magnetic resonance (MR) examination [1.5 Tesla, Siemens Magnetom Avanto (Siemens Medical Systems, Erlangen, Germany)], the lesion were extending the nasal cavity and left maxillary sinus, destroyed the

bone structures, from the nasal cavity to the oral cavity, destroyed the palatine bone and the size of the lesion was approximately 9x7 cm. In MR sequences, hypointense in the T1 sequence, hyperintense in the T2 sequence, and marked heterogeneous contrasting lesion area in the post contrast series were observed. The lesion fills the left maxillary sinus and the left section of the nasal cavity, extending from this level to the palatal fossa, the oral cavity, the subcutaneous tissue at the anterior level of the maxillary sinus. The lesion causes destruction in ethmoid bone, maxillary bone and palatine bone (Figure 5).

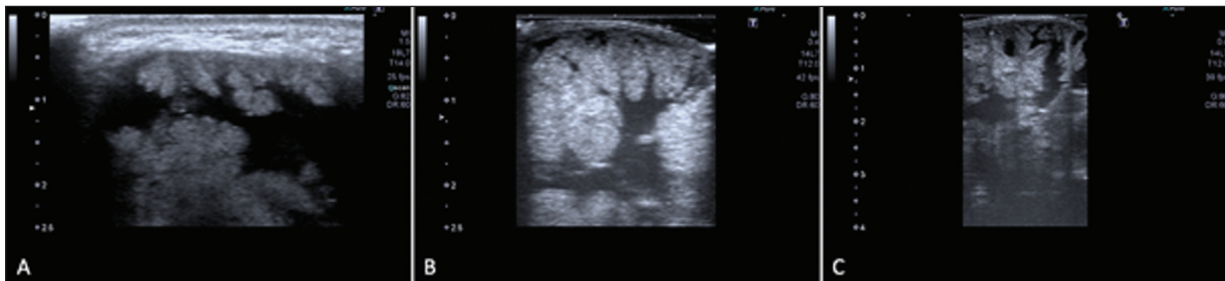


FIGURE 4: Images of the patient's extraoral (A) and intraoral (B, C) USG examination.

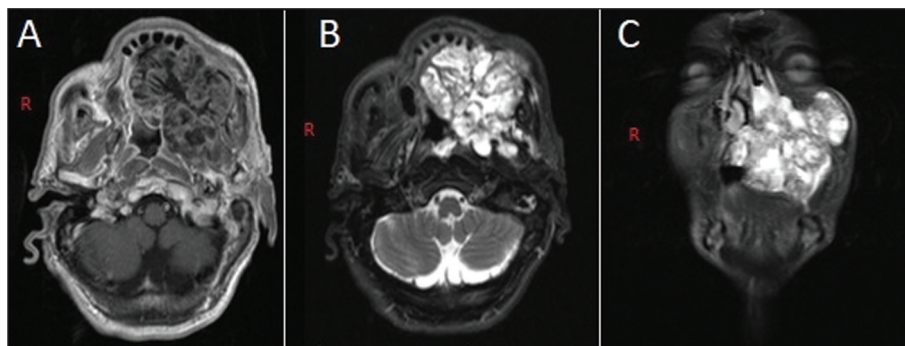

FIGURE 5: Magnetic resonance images (MRI) of the patient. A) Axial MRI section of the hypointense lesion area observed in the T1 sequence. B) Axial MRI section of the hyperintense lesion area observed in the T2 sequence. C) Coronal MRI section of the hyperintense lesion area in the T2 sequence.

According to the first biopsy, the patient was diagnosed with LNIAC at the Department of Pathology, Atatürk University, and Faculty of Medicine (Figure 6). The patient was referred to the faculty of medicine hospital of the same university for the treatment, because of the size of the neoplasm, the patient was recommended radiotherapy at the first stage, and radiotherapy treatment was started in the radiation oncology service. One month later, the patient was referred to our clinic with severe intraoral pain that would affect his nutrition. Due to radiotherapy, according to the WHO calcification grade 3 mucositis was observed (Figure 7). The patient was prescribed chlorhexidine+benzydamine HCl gargle with flurbiprofen oral spray as a symptomatic treatment and to prevent secondary infection. In March 2019, the patient re-applied to our clinic with complaints of bleeding and increased pain in the intraoral and nasal

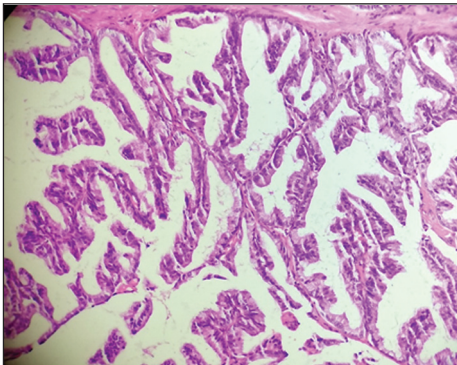


FIGURE 6: Low-grade non-intestinal type adenocarcinomas as a result of H&E (x200) staining.

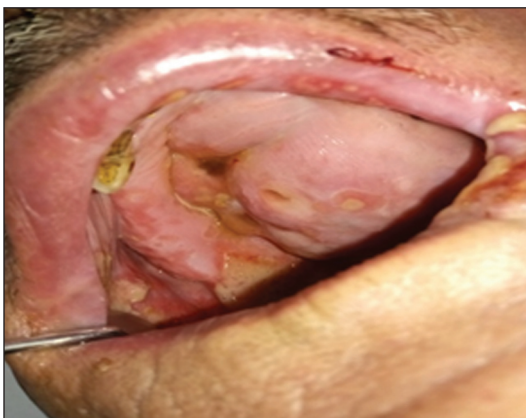

FIGURE 7: World Health Organization classification grade 3 severe mucositis from radiotherapy.

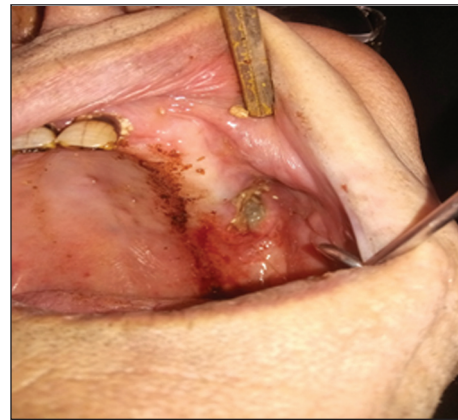

FIGURE 8: Bleeding foci observed in the intraoral region.

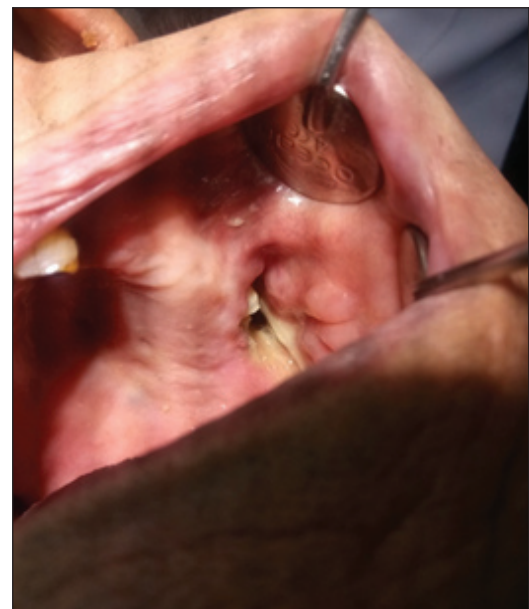


FIGURE 9: Oroantral fistula like structure with pus discharge in the lesion area.

region (Figure 8). The patient stated that mouthwash or sprays are good for their pain but not sufficient. He also stated that he was taking non-steroidal anti-inflammatory drugs regularly. As a result of the examination, it was observed that the expansion areas were completely lost. However, multiple bleeding foci were observed in the intraoral region. In addition to all of these, the smelly lesion area with a large pus discharge in the buccal area corresponding to the molar tooth area was identified and the patient was directed to the otolaryngology service. As a result of the examination performed there, surgery was recommended, but the patient refused the operation for personal reasons. The patient applied to our clinic again in June 2019, it was

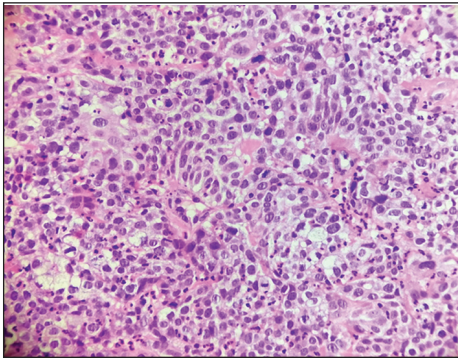


FIGURE 10: The image of poorly differentiated adenocarcinoma was observed in H&E(x200) staining obtained as a result of the second biopsy.

observed that the previously detected lesion area returned to the oroantral fistula (Figure 9). The patient complained that he could no longer have a vacuum effect in his mouth and therefore suffers from eating and drinking. A serious collapse is observed in the patient, physically and psychologically. The patient underwent a second biopsy, resulting in poorly differentiated structure (Figure 10). The patient applied to Atatürk University Medical Faculty Hospital, and Emergency Department due to severe respiratory failure. After the intervention, the patient was taken to the intensive care unit and died due to respiratory failure. Autopsy was not performed on the patient.

DISCUSSION

Although sinonasal adenocarcinomas appear in the nasal cavity, maxillary and ethmoid sinuses, they are most common in the paranasal sinuses.^{2,4} Although their etiology is not fully known, it has been reported to be more common in workers exposed to wood dust.^{2,7-10} They are more common in men over 60 years old.^{2,4} Nasal obstruction, pain, mass deformation, proptosis, epistaxis and bleeding may appear in patients depending on their location.

As a prognosis, 5-year lifetime is higher in LNIAC than HNIAC.² Approximately 6% of LNIAC patients die, while most HNIAC patients die within 5 years.¹⁻⁶ While LNIAC does not show metastasis, there are few relapses in the literature.^{3-6,11} LNIAC does not show metastasis, but there are few relapses in the literature.^{4,5,12} Skalova et al. and Luna reported that LNIAC patients in their case series died due to other reasons.^{3,5}

Franquemont et al. mention that all sinonasal neoplasms can cause death, and it is stated that the prognosis of cases with less differentiation in immunohistochemical examination is worse.¹¹ Although WHO classification mentions LNIAC and HNIAC clinically, it has been shown that there are many subtypes in pathological studies.^{4,11,13} As a result of these pathological typologies, the prognosis of those with papillary pattern has been shown to be worse.⁵ For these reasons, the pathological type of the tumor should be well determined and patients should be evaluated accordingly.

Polymorphism low grade adenocarcinoma and acinic cell carcinoma, which are minor salivary gland tumors, should be considered in the differential diagnosis of NIAC.⁵ Polymorphism low grade adenocarcinoma differs from NIAC with its morphology and perinoral invasion.⁵ The fact that acinic cell carcinoma is seen more rarely and aggressively enables it to be separated from NIAC. However, whether NIAC is low grade or high grade plays an important role especially in determining aggression.^{1,2,4-6,12}

In their case study, Franchi et al. mentioned that NIACs exhibit morphologically and pathologically heterogeneous appearance.¹² Lloreta et al. obtained different differentiation results as a result of two different biopsies in the patient, and reported that this may be due to the change of a single neoplasm over time rather than the appearance of two separate neoplasms at the same time and place.¹⁴ In the case we presented, serious differences were observed between the two biopsies of the same neoplasm. We think that this situation is due to the heterogeneous structure of advanced LNIAC. Due to this heterogeneous structure, the 1st and 2nd biopsies showed different differentiation and structure since they were performed from different regions of the neoplasm.

Radiotherapy following surgical treatment has been suggested in the studies.^{6,7} Heffner et al. stated that irradiation without surgery will worsen the prognosis.⁷ Surgical treatment, which is the recommendations of the authors, plays an important role in the treatment of patients, but in our case, since the tumor size in the patient was too large, it could not be operated at the first stage, and then the patient did not ac-

cept the surgical treatment of the neoplasm that reached the operable size after radiotherapy.

In conclusion, patients diagnosed with neoplasia should be followed carefully and for a long time. The benign character of the tumor does not change this. As in our case, if a neoplasm with benign characteristics cannot be directed to appropriate treatment, it may cause the patient to die.

Source of Finance

During this study, no financial or spiritual support was received neither from any pharmaceutical company that has a direct connection with the research subject, nor from a company that provides or produces medical instruments and materials which may negatively affect the evaluation process of this study.

Conflict of Interest

No conflicts of interest between the authors and/or family members of the scientific and medical committee members or members of the potential conflicts of interest, counseling, expertise, working conditions, share holding and similar situations in any firm.

Authorship Contributions

Idea/Concept: Özkan Miloğlu, Gözde Derindağ; **Design:** Özkan Miloğlu, Muhammet Enes Naralan; **Control/Supervision:** Özkan Miloğlu; **Data Collection and/or Processing:** Muhammet Enes Naralan, Gözde Derindağ; **Analysis and/or Interpretation:** Özkan Miloğlu, Sare Sipal; **Literature Review:** Özkan Miloğlu; **Writing the Article:** Muhammet Enes Naralan, Özkan Miloğlu; **Critical Review:** Sare Sipal; **References and Fundings:** Özkan Miloğlu; **Materials:** Muhammet Enes Naralan, Gözde Derindağ.

REFERENCES

- Abecasis J, Viana G, Pissarra C, Pereira T, Fonseca I, Soares J. Adenocarcinomas of the nasal cavity and paranasal sinuses: a clinicopathological and immunohistochemical study of 14 cases. *Histopathology*. 2004;45(3):254-9. [[Crossref](#)] [[PubMed](#)]
- El-Naggar AK, Chan JKC, Grandis JR, Takata T, Sliotweg PJ. WHO Classification of Head and Neck Tumours. 4th ed. Lyon: WHO Press; 2017. [[Link](#)]
- Luna MA. Sinonasal tubulopapillary low-grade adenocarcinoma: a specific diagnosis or just another seromucous adenocarcinoma? *Adv Anat Pathol*. 2005;12(3):109-15. [[Crossref](#)] [[PubMed](#)]
- Cathro HP, Mills SE. Immunophenotypic differences between intestinal-type and low-grade papillary sinonasal adenocarcinomas: an immunohistochemical study of 22 cases utilizing CDX2 and MUC2. *Am J Surg Pathol*. 2004;28(8):1026-32. [[Crossref](#)] [[PubMed](#)]
- Skalova A, Cardesa A, Leivo I, Pfaltz M, Ryska A, Simpson R, et al. Sinonasal tubulopapillary low-grade adenocarcinoma. *Histopathological, immunohistochemical and ultrastructural features of poorly recognised entity*. *Virchows Arch*. 2003;443(2):152-8. [[Crossref](#)] [[PubMed](#)]
- Choi HR, Sturgis EM, Rashid A, DeMonte F, Luna MA, Batsakis JG, et al. Sinonasal adenocarcinoma: evidence for histogenetic divergence of the enteric and nonenteric phenotypes. *Hum Pathol*. 2003;34(11):1101-7. [[Crossref](#)] [[PubMed](#)]
- Heffner DK, Hyams VJ, Hauck KW, Lingeman C. Low-grade adenocarcinoma of the nasal cavity and paranasal sinuses. *Cancer*. 1982;50(2):312-22. [[Crossref](#)] [[PubMed](#)]
- Klintonberg C, Olofsson J, Hellquist H, Sökjer H. Adenocarcinoma of the ethmoid sinuses. A review of 28 cases with special reference to wood dust exposure. *Cancer*. 1984;54(3):482-8. [[Crossref](#)] [[PubMed](#)]
- Kleinsasser O, Schroeder HG. What's new in tumours of the nasal cavity? Adenocarcinomas arising after exposure to wood dust. *Pathol Res Pract*. 1989;184(5):554-8. [[Crossref](#)] [[PubMed](#)]
- McKinney CD, Mills SE, Franquemont DW. Sinonasal intestinal-type adenocarcinoma: immunohistochemical profile and comparison with colonic adenocarcinoma. *Mod Pathol*. 1995;8(4):421-6. [[PubMed](#)]
- Franquemont DW, Fechner RE, Mills SE. Histologic classification of sinonasal intestinal-type adenocarcinoma. *Am J Surg Pathol*. 1991;15(4):368-75. [[Crossref](#)] [[PubMed](#)]
- Franchi A, Palomba A, Massi D, Biancalani M, Sardi I, Gallo O, et al. Low-grade salivary type tubulo-papillary adenocarcinoma of the sinonasal tract. *Histopathology*. 2006;48(7):881-4. [[Crossref](#)] [[PubMed](#)]
- Alessi DM, Trapp TK, Fu YS, Calcaterra TC. Nonsalivary sinonasal adenocarcinoma. *Arch Otolaryngol Head Neck Surg*. 1988;114(9):996-9. [[Crossref](#)] [[PubMed](#)]
- Lloreta J, Serrano S, Corominas JM, Ferrés-Padró E. Polymorphous low-grade adenocarcinoma arising in the nasal cavities with an associated undifferentiated carcinoma. *Ultrastruct Pathol*. 1995;19(5):365-70. [[Crossref](#)] [[PubMed](#)]