

Killian Nasal Speculum-Assisted Tonsillectomy Under Local Anesthesia

Killian Nazal Spekülüm Yardımıyla Lokal Tonsillektomi

Adnan ÜNAL,^a
Samet ÖZLÜGEDİK,^a
Ali TİTİZ,^a
Yavuz Fuat YILMAZ,^a
Kamran SARI,^a
Mehmet GAMLI^b

Clinics of
^aOtorhinolaryngology,
^bAnesthesiology,
Ankara Numune Training and
Research Hospital, Ankara,

Geliş Tarihi/Received: 15.12.2011
Kabul Tarihi/Accepted: 31.12.2012

*This study was presented as a poster at
29th Turkish National Congress of
Otorhinolaryngology and Head and
Neck Surgery, 26-31 May 2007, Antalya,
Türkiye*

Yazışma Adresi/Correspondence:
Samet ÖZLÜGEDİK
Ankara Numune Training and
Research Hospital,
Clinic of Otorhinolaryngology, Ankara,
TÜRKİYE/TURKEY
sametozlugedik@yahoo.com

ABSTRACT Objective: To describe Killian nasal speculum-assisted tonsillectomy under local anesthesia in detail and to question the experience of our patients with this surgical procedure. **Material and Methods:** Group 1 included patients that underwent Killian nasal speculum-assisted tonsillectomy under local anesthesia (n=44) and Group 2 those who underwent classical cold dissection tonsillectomy under general anesthesia (n=28). **Results:** Among the patients in Group 1, 59.1% (26/44) reported mild, 27.3% (12/44) moderate, and 13.6% (6/44) excessive levels of anxiety preoperatively. All patients in Group 1 reported that they felt safe during surgery; 84.1% (37/44) reported that the surgery was easier than they had anticipated, whereas 15.9% (7/44) reported it was more difficult than anticipated. Duration of surgery in Groups 1 and 2 was 22.7 ± 7.0 minutes and 63.7 ± 16.3 minutes, respectively (p<0.001), and the median volume of intraoperative bleeding was 5 mL (range, 1-90 mL) and 180 mL (range, 40-400 mL), respectively (p < 0.001). No intraoperative complication developed in either group and the amount of postoperative bleeding did not show a significant difference between the groups. **Conclusion:** In selected adult patients, Killian nasal speculum-assisted tonsillectomy under local anesthesia is a time saving procedure, which produces less intra-operative blood loss compared to cold dissection tonsillectomy under general anesthesia.

Key Words: Tonsillectomy; anesthesia, local; blood loss, surgical

ÖZET Amaç: Killian nazal spekülüm yardımıyla lokal anestezi altında yapılan tonsillektomiye detaylı olarak tanımlamak, hastaların bu ameliyat hakkındaki deneyimlerini değerlendirmek. **Gereç ve Yöntemler:** Grup 1 lokal anestezi altında killian nazal spekülüm yardımıyla tonsillektomi yapılan hastaları (n=44) ve Grup 2 genel anestezi altında klasik soğuk diseksiyon ile tonsillektomi yapılan hastaları (n=28) içermektedir. **Bulgular:** Ameliyattan önce Grup 1'deki hastaların %59,1 (26/44)'i az, %27,3 (12/44) orta, %13,6'sı da (6/44)'ü şiddetli derecede kaygı hissettiklerini belirtti. Yine aynı gruptaki hastaların tümü, ameliyat sırasında kendilerini güvende hissettiklerini, %84,1'i (37/44) operasyonu beklediklerinden kolay, %15,9'u (7/44) ise daha zor bulduklarını belirtti. Ameliyat süresi grup 1 ve 2'de sırasıyla 22,7±7,0 dk ve 63,7±16,3 dk (p<0,001), ameliyat sırasındaki kanama miktarının ortanca değeri sırasıyla 5 mL (aralık, 1-90 mL) ve 180 mL (aralık, 40-400 mL) idi (p<0,001). İki grupta da intraoperatif komplikasyon gelişmedi ve postoperatif kanama açısından iki grup arasında farklılık saptanmadı. **Sonuç:** Seçilmiş erişkin hastalarda, lokal anestezi altında Killian nazal spekülüm yardımıyla yapılan tonsillektomi, genel anestezi altında soğuk diseksiyon ile yapılan tonsillektomiye göre zamanın daha verimli kullanıldığı ve intraoperatif kanamanın daha az olduğu bir cerrahi yöntemdir.

Anahtar Kelimeler: Tonsillektomi; anestezi, lokal; kan kaybı, cerrahi

Türkiye Klinikleri J Med Sci 2013;33(3):607-12

doi: 10.5336/medsci.2011-27871

Copyright © 2013 by Türkiye Klinikleri

Türkiye Klinikleri J Med Sci 2013;33(3)

Although the history of tonsillectomy dates back to 3000 BC, the pioneering techniques of modern tonsillectomy began to develop in the 18th century.^{1,2} Until the introduction of ether as a general anes-

thetic, tonsillectomy was performed without anesthesia.¹ Since the introduction of local anesthetics, tonsillectomy performed under local anesthesia has been a common surgical procedure, particularly in adult patients. Currently, many otorhinolaryngologists consider tonsillectomy under local anesthesia to be uncomfortable for patients and therefore prefer general anesthesia during tonsillectomy;³ however, tonsillectomy under local anesthesia has been reported to be a safe, comfortable, and cost-effective procedure in selected adult patients.²⁻⁷

Cold dissection is the most frequently used surgical technique for tonsillectomy under local anesthesia.²⁻⁶ Although currently not as common, tonsillectomy in adult patients has been performed with the aid of a large Killian nasal speculum under local anesthesia in our clinic for 50 years. Nevertheless, the literature supporting this approach is limited. The purposes of the present study were to describe Killian nasal speculum-assisted tonsillectomy under local anesthesia in detail, to evaluate the surgical experience of the patients, and to prospectively compare the volume of intraoperative bleeding, duration of surgery, and complications in patients that underwent Killian nasal speculum-assisted tonsillectomy under local anesthesia and those that underwent classical cold dissection tonsillectomy under general anesthesia.

MATERIALS AND METHODS

The study included 72 patients with recurrent and/or chronic tonsillitis, 44 of whom underwent Killian nasal speculum-assisted tonsillectomy under local anesthesia (Group 1) and 28 of whom underwent classical cold dissection tonsillectomy under general anesthesia (Group 2). Group 1 included 16 males and 28 females with a mean age of 25.5 ± 8.2 years, versus 12 males and 16 females with a mean age of 25.4 ± 7.7 years in Group 2. All the surgical procedures were undertaken by specialists or experienced residents under the supervision of specialists. The study protocol was approved by the Institutional Ethics Committee.

Patients with a history of peritonsillar abscess, excessive gag reflex, and history of epilepsy were not included in Group 1. Overall, 30 patients in

Group 1 were premedicated with intramuscular pethidine HCl (1 mg kg^{-1}) and atropine (0.007 mg kg^{-1}), and 14 were premedicated with intravenous midazolam ($0.07\text{-}0.1 \text{ mg kg}^{-1}$). Duration of surgery in Group 1 was considered the time from the injection of local anesthetic to discharge from the surgical suite, versus the time from the initiation of induction anesthesia to discharge from the surgical suite in Group 2.

SURGICAL TECHNIQUE

All patients in Group 1 underwent surgery in the sitting position. Initially, mucosal anesthesia was induced by spraying topical pontocaine 2% on the oropharynx and oral cavity. For infiltration anesthesia, lidocaine 2%, which includes 0.125% adrenalin 2 mL^{-1} was used. To achieve local anesthesia first submucosal, and then approximately 1-cm depth injections were made. Using a bent syringe needle, additional injections were given to the posterior plicae and inferior pole of the tonsil. The mean amount of local anesthetics administered was 12 mL.

The tongue was pressed inferiorly to tense the anterior plica of the tonsil, and then using a Henke tonsil dissector, a mucosal incision was made approximately 2 mm lateral to the plica (Figure 1a). Adjacent to the uvula, the upper end of the incision was extended to the posterior plica of the tonsil using scissors (Figure 1b). Following traction of the tonsil in the inferomedial direction via a Blohmke tonsil forceps (Figure 2a), a large Killian nasal speculum was inserted between the tonsil capsule and tonsillar bed (Figure 2b), and with the aid of the nasal speculum, blunt dissection was made in order to dissect the tonsil inferiorly and medially (Figure 3a). As the tonsil mostly separated from the surrounding tissues, it was then dissected with a dissector (Figure 3b) so that the only connection of the tonsil to the pharynx would be at its inferior pole. The tonsil was removed with an Eves tonsil snare. In Group 2, the classical cold dissection technique was used. Hemorrhage was controlled in all patients with bipolar electrocautery.

The patients in Group 1 were administered a questionnaire on postoperative day one in order to

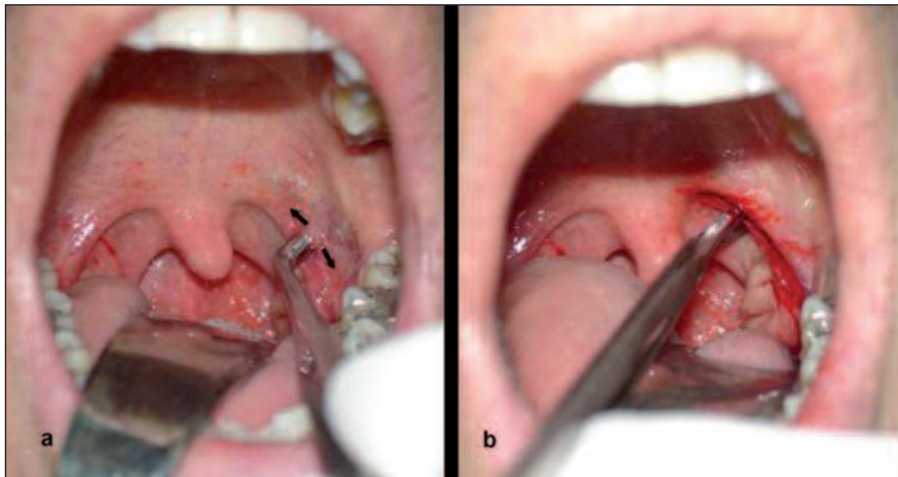


FIGURE 1a,b: **1a.** Mucosal incision using a Henke tonsil dissector. **1b.** Incision of the posterior plica of the tonsil using scissors.
(See color figure at <http://tipbilimleri.turkiyeklinikleri.com/>)

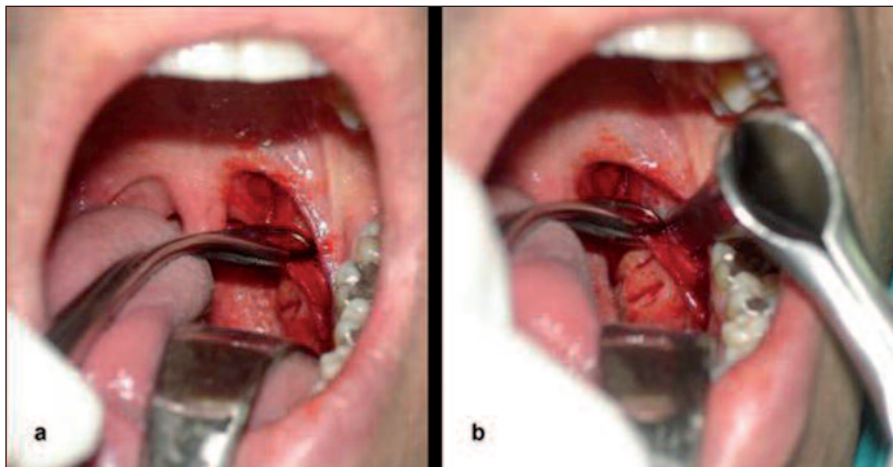


FIGURE 2a,b: **2a.** Traction of the tonsil towards the inferomedial direction with Blohmke tonsil forceps. **2b.** Insertion of a large Killian nasal speculum between the tonsil capsule and tonsillar bed.
(See color figure at <http://tipbilimleri.turkiyeklinikleri.com/>)

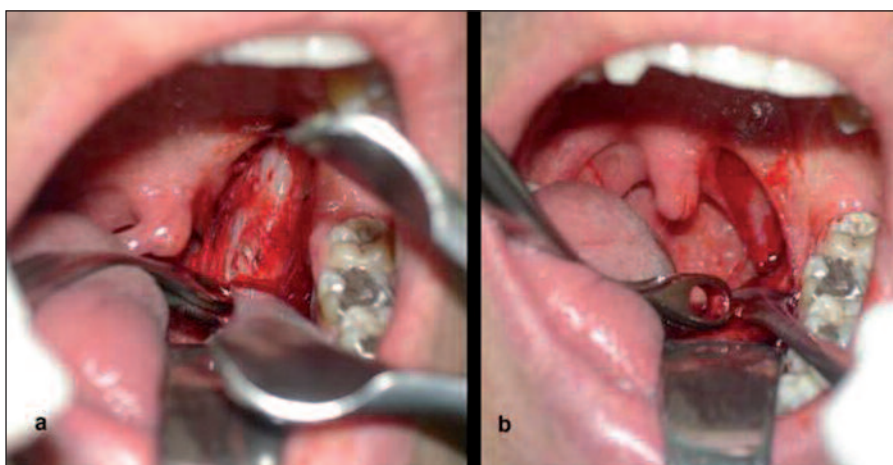


FIGURE 3a,b: **3a.** Blunt dissection using a large Killian nasal speculum in order to dissect the tonsil inferiorly and medially. **3b.** The tonsil is dissected with a dissector.
(See color figure at <http://tipbilimleri.turkiyeklinikleri.com/>)

evaluate their surgical experiences (Table 1). In addition, the volume of intraoperative bleeding, duration of surgery, and intraoperative and postoperative complications were prospectively compared between Groups 1 and 2. Duration of surgery was analyzed with the Student's t test; logarithmic transformed blood loss was analyzed with the Mann-Whitney U test, and nominal variables were evaluated with the Yates's continuity correction test, the chi-square test or Fisher's exact test, where applicable. The level of significance was set at 0.05.

RESULTS

Among the patients in Group 1, 59.1% (26/44) reported mild, 27.3% (12/44) moderate, and 13.6% (6/44) extreme levels of anxiety preoperatively. All patients in Group 1 reported that they felt safe during surgery; 84.1% (37/44) reported that the surgery was easier and the remaining 15.9% (7/44) reported that it was more difficult than they had expected. Overall, 86.4% (n=38) of Group 1 reported that they would consider undergoing tonsillectomy under local anesthesia again, whereas 13.6% (n=6) reported that they would not, due to intraoperative pain (n=4) and although having been satisfied with tonsillectomy, previously having undergone septoplasty under local anesthesia (n=2).

In Groups 1 and 2, respectively, the mean duration of surgery was 22.7 ± 7.0 min and 63.7 ± 16.3 min, and the median volume of intraoperative bleeding was 5 mL (range, 1-90 mL) and 180 mL (range, 40-400 mL). The differences in duration of surgery ($p < 0.001$) and intraoperative bleeding ($p < 0.001$) between Groups 1 and 2 were significant. Patient characteristics, mean duration of surgery, median volume of intraoperative bleeding, intraoperative complications, postoperative bleeding, and non-surgical complications in both groups were shown in Table 2. No intraoperative complication occurred in either group and there was no significant difference in postoperative bleeding between the groups. One patient in Group 2 developed pneumonia as the sole non-surgical complication during the postoperative period, whereas no non-surgical complications were noted in Group 1 (Table 2).

DISCUSSION

In selected adult patients Killian nasal speculum-assisted tonsillectomy under local anesthesia is a time saving procedure which produces less intraoperative blood loss than cold dissection tonsillectomy under general anesthesia. Some of the most important factors affecting patient satisfaction with tonsillectomy under local anesthesia are preoperative anxiety and intraoperative pain. In the presented series, despite the presence of excessive preoperative anxiety in 13.6% (n=6) and moderate preoperative anxiety in 27.3% (n=12) of the pa-

TABLE 1: English translation of the questionnaire used to evaluate the surgical experiences of the patients in Group 1.

Q1: How anxious were you prior to the surgery?	
Not anxious	Mildly anxious
Moderately anxious	Extremely anxious
Q2: Did you feel safe during surgery?	
Yes	No
Q3: As compared to what you expected, how was the surgery?	
Easy	Difficult
Q4: Would you consider undergoing tonsillectomy under local anesthesia again?	
Yes	No
Q5: 4. If you answered "No" to question 4, why?	
Pain	Mild
Moderate	Severe
Anxiety	Other:.....

TABLE 2: Characteristics of patients and surgery.

	Group 1 (n=44)	Group 2 (n=28)	p
Gender M/F	16/28	12/16	0.762
Age (years)			
Mean±SD	25.5±8.2	25.4±7.7	0.923
Duration of surgery (min)			
Mean±SD	22.7±7.0	63.7±16.3	<0.001
Volume of intraoperative bleeding			
Median (range)	5(1-90)	180 (40-400)	<0.001
Intraoperative complications, n (%)	-	-	-
Postoperative bleeding, n (%)	3 (6.8)	2 (7.1)	1.000
Non-surgical complications, n (%)	0 (0.0)	1 pneumonia (3.6)	0.389

F: Female; M: Male; SD: Standard deviation.

tients in Group 1, all the Group 1 patients reported that they felt safe during surgery. Because the patients in Group 2 were not given the same questionnaire, a comparison cannot be made between the groups; however, preoperative anxiety is a significant problem in patients scheduled for surgery under general anesthesia^{3,4} the most common cause of anxiety being general anesthesia in 54%.⁸ The most effective methods of reducing preoperative anxiety is educating patients about the surgical procedure⁹ and preoperative administration of anxiolytics,¹⁰ therefore, all the patients in the present study were informed in detail about the surgical procedure, and midazolam was used for premedication.

Intraoperative pain may be experienced to varying degrees of severity in accordance with the dose of local anesthetics administered, the infiltration technique, and previous experiences of the patient. Patients experience pain most commonly during dissection of the middle and inferior portions of the tonsil; therefore, not only the dose of local anesthetic, but its administration deep into the tonsil bed in the middle and inferior portions of the tonsil is critical in reducing intraoperative pain. The experience of excessive pain in this region might be related to the innervation pattern within the tonsil capsule.¹¹

The most appropriate patients for tonsillectomy under local anesthesia are those with low gag reflex and a high level of cooperation.⁵ In such patients, palpation of the anterior plica of the tonsil with a tongue depressor may provide a sufficient idea about the gag reflex. As tonsil atrophy and a history of peritonsillar abscesses may complicate dissection, they can also negatively affect patient satisfaction. Moreover, the choice of surgical technique is also important for the comfort of both the patient and the surgeon.

The most common method of tonsillectomy under local anesthesia is cold dissection.^{1-4,6,7} Although the technique described in this report is a modification of cold dissection, it has some noteworthy advantages. First, incision of the anterior plica using a Henke knife with an angle of 90° pro-

jects the tonsil tissue from iatrogenic trauma that might occur at the beginning of the surgery (Figure 1a), hence preventing early hemorrhage. The Killian nasal speculum employed for detaching the upper pole of the tonsil from the tonsil bed facilitates recognition of the tonsil capsule, so that dissection is made rapidly in the correct plane, which reduces the duration of surgery (Figures 2b and 3a). As such, we think that this surgical technique is useful for the prevention of intraoperative complications, particularly during resident training. Additionally, the force exerted during tonsil dissection and the traction that occurs in the tonsil bed are more controlled than those associated with classic dissection, which together might be effective in reducing the pain felt by patients during surgery.

In the present study, tonsillectomy under local anesthesia resulted in a significantly lower volume of intraoperative bleeding and significantly shorter duration of surgery. Similar results have been previously reported.^{2,3,5,6} It was also reported that lower volume of bleeding during tonsillectomy under local anesthesia might be attributable to the epinephrine included in local anesthetic, lower venous pressure due to the patient being in a sitting position, and higher vasoconstriction, as muscle tone is high.⁵ Tonsillectomy under local anesthesia is not only associated with shorter duration of surgery but it is also cost-effective regarding postoperative recovery.

In the present study, no intraoperative complication developed in either group and there was no significant difference in postoperative complications between the groups. Tonsillectomy under local anesthesia has also been reported to be a safe procedure that does not increase the frequency of serious complications such as postoperative hemorrhage.^{2,5,6} Pekkarinen et al reported that tonsillectomy under local anesthesia was also a cardiologically safe procedure; however, tonsillectomy under local anesthesia should always be performed in a surgical suite under the supervision of an anesthetist as unexpected intraoperative hemorrhage due to vascular anomalies might require intervention under general anesthesia.¹¹ Moreover, it should be kept in mind that large arterial vessels

might exist adjacent to the tonsillar fossa and the piston of the syringe should be pulled back prior to each injection in order to prevent intra-arterial injections.

In selected adult patients, Killian nasal speculum-assisted tonsillectomy under local anesthesia is a time saving procedure which result in less intraoperative blood loss compared to cold dissection tonsillectomy under general anesthesia. This sur-

gical technique can be used alternatively in patients who do not prefer tonsillectomy under general anesthesia. The most important factors associated with patient satisfaction are patient selection, careful evaluation and selection of the optimal surgical technique.

The authors wish to thank Atilla H. Elhan PhD, for his contribution to the statistical analysis of this study.

REFERENCES

1. Younis RT, Lazar RH. History and current practice of tonsillectomy. *Laryngoscope* 2002;112(8 Pt 2 Suppl 100):3-5.
2. McClairen WC Jr, Strauss M. Tonsillectomy: a clinical study comparing the effects of local versus general anesthesia. *Laryngoscope* 1986;96(3):308-10.
3. Agren K, Engquist S, Danneman A, Feychting B. Local versus general anaesthesia in tonsillectomy. *Clin Otolaryngol Allied Sci* 1989; 14(2):97-100.
4. Apostolopoulos K, Labropoulou E, Samaan R, Bogris K. Ropivacaine compared to lidocaine for tonsillectomy under local anaesthesia. *Eur Arch Otorhinolaryngol* 2003; 260(7):355-7.
5. Bredekamp JK, Abemayor E, Wackym PA, Ward PH. Tonsillectomy under local anesthesia: a safe and effective alternative. *Am J Otolaryngol* 1990;11(1):18-22.
6. Tami TA, Parker GS, Taylor RE. Post-tonsillectomy bleeding: an evaluation of risk factors. *Laryngoscope* 1987;97(11):1307-11.
7. Unlü Y, Tekalan SA, Cemiloğlu R, Ketenci I, Kutluhan A. Guillotine and dissection tonsillectomy in children. *J Laryngol Otol* 1992; 106(9):817-20.
8. Mitchell M. Psychological preparation for patients undergoing day surgery. *Ambulatory Surgery* 2000;8 (1):19-29.
9. Mitchell M. Patient anxiety and modern elective surgery: a literature review. *J Clin Nurs* 2003;12(6):806-15.
10. Bernard JM, Faintreny A, Lienhart A, Souron R. Patient-controlled premedication by i.v. midazolam for ambulatory surgery. *Acta Anaesthesiol Scand* 1996;40(3):331-7.
11. Pekkarinen H, Kärjä J. Results of long-term ECG monitoring in patients submitting to tonsillectomy under local anaesthesia. *J Laryngol Otol* 1982;96(8):725-30.