

# Fabricating Toe Prostheses Using 3-D Modeling Technique: Case Report

## 3-Boyutlu Modelleme Tekniği Kullanarak Ayak Başparmağı Protezi Yapımı

Mustafa KOCACIKLI,<sup>a</sup>  
Fatih Mehmet KORKMAZ,<sup>b</sup>  
Hüseyin YAZICIOĞLU,<sup>a</sup>  
Suat YALUĞ<sup>a</sup>

<sup>a</sup>Department of Prosthodontics,  
Gazi University, Faculty of Dentistry,  
Ankara

<sup>b</sup>Department of Prosthodontics,  
Karadeniz Technical University,  
Faculty of Dentistry,  
Trabzon

*This case report was presented in  
31st Annual Conference of  
European Prosthodontic Association (EPA)  
in October 11-13th, 2007  
in Athens, GREECE.*

Geliş Tarihi/Received: 10.10.2008  
Kabul Tarihi/Accepted: 19.12.2008

Yazışma Adresi/Correspondence:  
Fatih Mehmet KORKMAZ  
Karadeniz Technical University,  
Faculty of Dentistry,  
Department of Prosthodontics,  
Trabzon,  
TÜRKİYE/TURKEY  
fmkorkmaz@hotmail.com  
korkmazfm@yahoo.com

**ABSTRACT** This article describes a technique for making toe prostheses using CAD-CAM technology and a rapid prototyping machine. A laser scanner was used to develop an integrated 3D digital image of the existing toe of a patient subjected to toe ablative surgery. The image was mirrored and used to manufacture the solid toe cast by means of a rapid prototyping machine. Subsequently, the definitive prosthesis was obtained through conventional procedures. Recent studies have focused on computer-assisted rapid prototyping machines to sculpture facial prostheses. Several techniques have been reported to fabricate a mirror-image wax cast for maxillofacial prostheses; however these techniques are costly and may require more time than manual fabrication. Several research protocols have proposed technical computer assisted solutions, however this article describes a simple, inexpensive, and repeatable method of obtaining a definitive wax cast of toe prosthesis.

**Key Words:** Toes; prosthesis design; computer-aided design; imaging, three-dimensional

**ÖZET** Bu makalede CAD-CAM teknolojisi ve hızlı prototipleme makinası kullanılarak ayak baş parmağı protezi yapımı anlatılmaktadır. Cerrahi yöntemle ayak başparmağı çıkarılmış hastanın alınan kısmının 3 boyutlu görüntüsü lazer tarayıcı kullanılarak entegre edilmiştir. Görüntü aynalanarak hızlı prototipleme makinası ile asıl ayak başparmağı modeli üretilmiştir. Daha sonra esas protez geleneksel yöntemlerle elde edilmiştir. Son çalışmalar fasiyal protezlerin modelajı için bilgisayar destekli hızlı prototipleme makinaları üzerine odaklanmıştır. Maksillo fasiyal protezlerin aynalanmış mum modelinin üretilmesinde pek çok teknik rapor edilmiştir; ancak, bu teknikler elle üretime göre daha pahalı ve zaman alıcıdır. Pekçok araştırma protokolü, bilgisayar destekli teknik çözümleri önermektedir; buna rağmen bu makale parmak protezinin esas mum modelinin elde edilmesi için basit, pahalı olmayan ve tekrar edilebilir bir yöntemi açıklamaktadır.

**Anahtar Kelimeler:** Ayak başparmağı; protez dizaynı; bilgisayar destekli tasarım; üç boyutlu görüntüleme

**Türkiye Klinikleri J Med Sci 2010;30(5):1750-5**

Today, many severely injured and traumatically amputated digits can be saved by different flap techniques and microsurgical replantation.<sup>1-4</sup> In some cases, however, reconstruction is contraindicated or has an unsuccessful outcome. It is in this group of patients that a quality prostheses can be provided and may offer great functional and psychological benefit.<sup>1,4-6</sup>

There are few reports in the literature on the benefit of finger prosthesis. Early reports stated that there were limited indications and little de-

mand for these devices. Following improvement in the technical quality of the digital prostheses, later reports indicated that these prostheses could serve a substantial psychological and functional role for the amputee.<sup>5,7</sup>

The level of amputation and length of stump preserved are important in determining the functional capability of the prosthesis.<sup>2,4,6,8</sup> Prosthetic considerations according to the level of amputation can be at three levels: loss of finger nail, phalangeal amputations, and metacarpal amputations. A precisely fitting prosthesis can improve function by restoring normal length, providing an opposition for the remaining digits, maintaining sensitivity through a thin lamina, protecting a sensitive stump, and transmitting pressure and position-sense activities.<sup>1,2</sup>

Retention is the most important factor for esthetics, function, and comfort of the digital prostheses, thereby improving patient's quality of life.<sup>2,9</sup> Normally the vacuum effect on the stump of digital prostheses is sufficient to retain the finger.<sup>4,6,10</sup> To improve appearance and aid retention a dress ring can be worn to disguise the junction line on short stumps. If a stump is too short for vacuum retention alone, then a double ring can be worn.<sup>4</sup> The stump of the amputated finger should be minimally 1.5 cm in length to fit the standard digital prosthesis.<sup>4</sup> An alternative method is an osseointegrated implant with prosthesis for finger reconstruction.<sup>11</sup> The success of most non-implant-retained digit prostheses depends on retention which in turn depends on the skin adhesive used.<sup>12</sup>

Several methods have been used to fabricate toe prosthesis when a preoperative cast is not available.<sup>1,13,14</sup> Although some of these methods have become routine, matching and sculpting the symmetrical morphology of the remaining toe remains a challenge. The present report describes a methodology that produces a mirror-image wax pattern for a toe prosthesis, using a cast made from the patient's remaining toe and rapid-prototyping computer technology.

Specifically, we describe an accurate and simple method for obtaining a mirror-image wax pat-

tern of a toe for fabrications of a toe prosthesis using computer-aided technology and rapid prototyping.

## CASE REPORT

A 35-year-old white woman who had lost her left toe at the base of the proximal phalanx (Figure 1) in an accident when she was 6-year-old was admitted for treatment.

Impressions were made with the patient seated and her arms held in a relaxed posture on either side of the chair. The most commonly used impression material is an irreversible hydrocolloid or dental alginate.<sup>1</sup> Impressions of the left and right foot were made with dental alginate (Hydrogum 5; Zhermack SpA, Badia Polesine, Italy) (Figure 2). ADA type V dental stone material (Die Keen; Heraeus Kulzer, Armonk, NY) which was

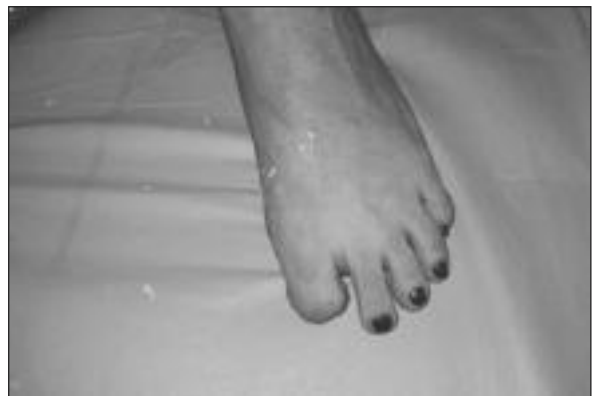

FIGURE 1: The defective foot.

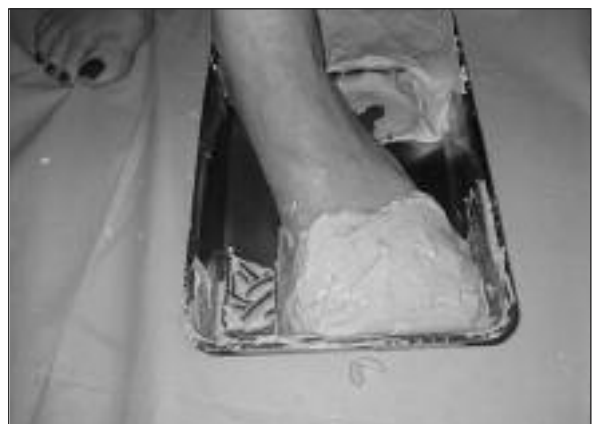
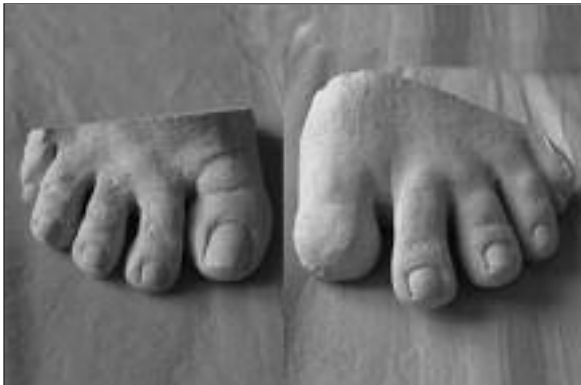
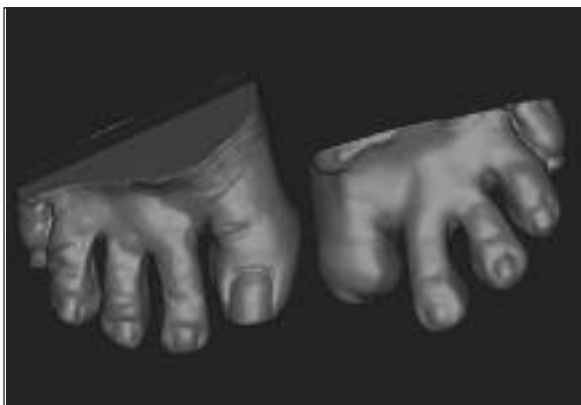FIGURE 2: Making the impression.

poured into the negative molds to produce the cast of foot with lost toe and the opposite foot (Figure 3).

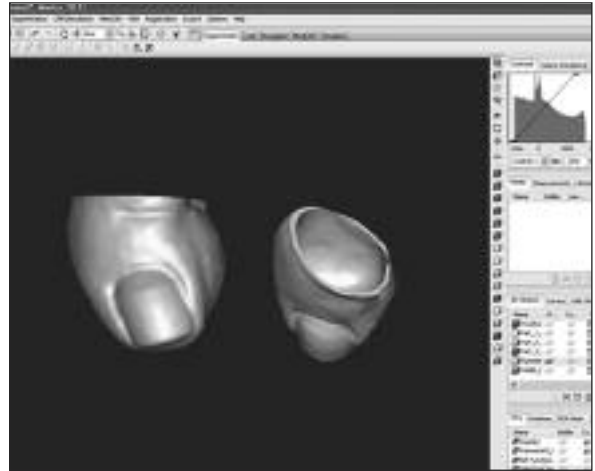
Dental casts of the defective and normal foot were scanned with the aid of a laser scanner (Z Scanner 700; Z Corp, Burlington, MA, USA). A 3-D computer model of the cast was obtained using a 3-D laser scanning system that was developed to produce a 3-D dental cast called an "emodel". A laser scanner connected to a personal computer (Toshiba Satellite A200-230, Toshiba Europe GMBH, China) was used to acquire the 3-D spatial coordinates of the models using software purchased from Mimics (Materialise, Belgium) which loaded the 3-D data points into the scanning system's proprietary emodel software. The triangular mesh output was visualized using a stereolithography (STL) file (STL file format; 3-D Systems Inc, Valencia, Calif).



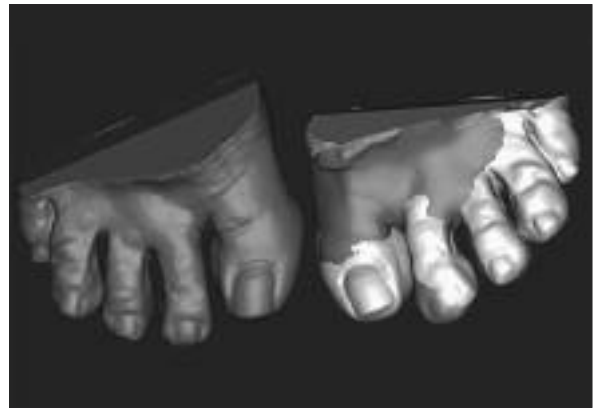**FIGURE 3:** Casts of normal and defective foot.



**FIGURE 4:** 3-D digital models of normal and defective foot.



**FIGURE 5:** Mirror image of the part of right toe, which will be accommodated.



**FIGURE 6:** Right toe was accommodated to the opposite left defective area using 3-D digital data.

3-D digital models were acquired on a STL-file format (Figure 4).

An mirror image of the normal toe was obtained on digital base using 3-D digital models (Figure 5).

A 3-D mirror image of the normal toe was accommodated to the defective toe and absent region of the defective toe was treated on digital base (Figure 6).

The definitive acrylic toe prosthetic model was obtained by manufacturing the absent area of the defective toe (Figure 7).

The definitive acrylic toe prosthetic model was manufactured using the Z Printer (Z Printer 310;

Z Corp, Burlington MA, USA). By using the Z Printer 310 machine, a layer of sealant with a layer of resin powder was provided and the entire volume was developed through layer-by-layer manufacturing. The acrylic resin was allowed to polymerize for one hour. The cast was extracted from the powder and then the surface of the manufactured model of toe prosthesis was infiltrated with cyanoacrylate (496; Loctite Italia, Brugherio, Italy) to further harden the acrylic resin model of the toe prosthesis. A polysiloxane material [Zetaplus; Zhermack, Badia Polesine (Rovigo), Italy] was used to transform the acrylic resin cast into a wax toe. A mold of the toe was made using silicone, leaving an opening in the mold all around the base of the prototyped toe. Wax (Set up Wax; Cavex, Haarlem, Holland) was poured into the negative mold to duplicate the prosthetic toe model. Once the wax hardened, the cast was extracted from the separated two parts of the silicone mold.<sup>15</sup> Margins of the wax pattern were adapted on the stump cast. The size, shape, and contours of the wax pattern were evaluated on the patient (Figure 8).

Next, another wax pattern was duplicated for the acrylic resin nail and base for the final prosthesis. This wax pattern was duplicated with the transparent, heat-polymerized acrylic resin (Akribel; Atlas Enta AS, Izmir, Turkiye) using a conventional method.<sup>1</sup>

Excess area of the nail and retention area was trimmed with the aid of a carbide bur (Laboratory Carbide Bur; GC Corp, Tokyo, Japan) from the clear acrylic resin finger. This procedure differs from McKinstry's technique because not only the nail but also the nail and the retention side of the nail which planned inside of the silicone finger prosthesis were both made 1-2 mm thick together. Thus, we did not need to make any wax relief on the wax model for nail.

Wet and dry sandpaper with water were used to finish the nail to a smooth, polished surface. The nail became more translucent as it was polished. The wax prototype was smoothed with solvent and the final characteristics (skin folds, wrinkles, and print patterns) were added with sculpting tools. A traditional multipiece mold technique was used.

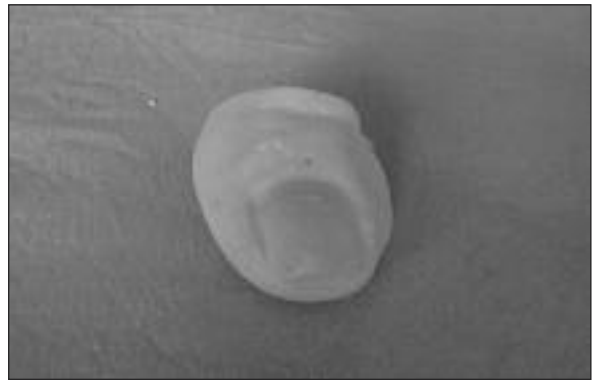


FIGURE 7: The definitive acrylic toe.

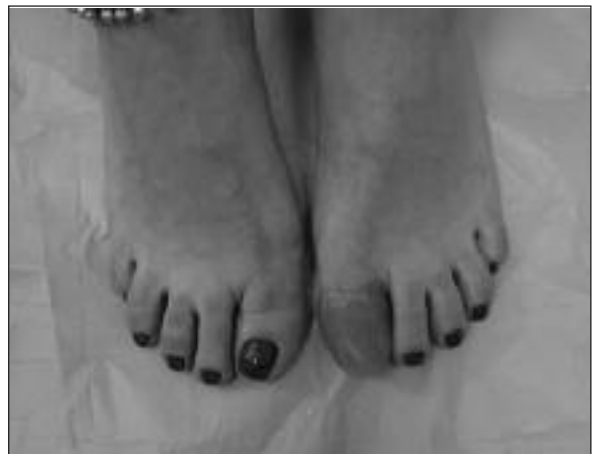

FIGURE 8: The wax pattern of toe prosthesis fitted to the patient.

An individual stone mold was fabricated using the lost wax technique.<sup>2</sup> The acrylic resin substructure of the nail and retained part were cleaned with acetone, and the silicone primer (Platinum Primer; Principality Medical Ltd, South Wales, UK) was applied. The substructure was placed in an oven (FN 500; Nuve AS, Ankara, Turkey) at 100 °C for 10 minutes. The clear acrylic nail with the retention side was placed on the nail area of the mold using cyanoacrylate. The base color of the skin was achieved using intrinsic pigments mixed with the silicone base (Cosmesil; Principality Medical Ltd, South Wales, UK) to match the different shades of the patient's own skin. Colored silicone was layered into the mold in the appropriate locations. The molds were closed, light pressure was applied to remove excess material, and the molds were transfer-



**FIGURE 9:** Toe prosthesis evaluated on the patient.

red to a clamp. The silicone was held at 100 °C for one hour. When the molds were sufficiently cool, the prosthesis was carefully removed. Excess material was trimmed with the aid of scissors. The nail was then colored with nail polish. The fit and the contours of the marginal areas of the toe prosthesis and overall design were evaluated on the patient (Figure 9). Extrinsic colors were applied and acetoxy silicone adhesive (Cosmesil; Principality Medical Ltd, South Wales, UK) was used to fix the coloration onto the silicone. The prosthesis was inserted using adhesives and tissue undercuts. The patient was instructed regarding home care, use of adhesive, and prosthesis maintenance. Home care included mechanical debridement of the skin with a soft tooth brush and irrigation with soap and water. After each daily use, the prosthesis should be removed and cleaned with a mild soap in preparation for the next wearing. Dye stains can be easily removed, depending on the care or abuse the prosthesis receives. With reasonable care, an average of two to three years of regular use can be expected.

## DISCUSSION

Since not every patient may be suitable for a prosthesis, patient selection is very important. An adequate stump and patient's realistic expectations are critical decision-making factors for a successful fit, acceptance, and subsequent use of the prosthesis.<sup>2,6</sup> We were successful in this case because we fulfilled the patient's prosthetic expectations.

The psychological effects of good-quality prostheses have received scant attention in the literature. With the use of modern materials, improved methods of fabrication; and attention to the detail,

a high-quality cosmetic result can be achieved.<sup>4</sup> In this case, prosthetic rehabilitation is made for phalangeal amputations. Even when the toe prosthesis is not functional, it may be beneficial for esthetic reasons.

Pereira reported that about one quarter of the patient experienced a poor or loose fit of the prosthesis.<sup>6</sup> This was one of the main reasons given by the patients for not using their prostheses. They were apprehensive about the prostheses dropping off.<sup>6</sup> Our patient did not have this fear because she believed she had good retention.

An osseointegrated implant with prosthesis offers an alternative method for finger reconstruction.<sup>10,11</sup> Other alternatives are bone grafting with a flap, which is bulky, or bone distraction, which is very difficult when the stump is short and usually unsuitable for standard digital prostheses.<sup>9-11</sup> In patients who can be fitted with either a standard or osseointegrated prosthesis, the standard prosthesis is usually preferred because: 1) the patient wants to avoid surgery, 2) the implant is expensive, 3) it is difficult to have a functional prosthesis with a long stump, and 4) grip strength is less than desired. The implant retained prosthesis provides a good post for prosthesis fixation, transfer motor function and perception of sensation. However, toe transfer usually yields better functional results and an acceptable appearance, but it is reserved for only selected cases.<sup>11</sup> In our patient, the dimensions of the finger were suitable for vacuum retention. She has worn her prosthesis for two years with satisfaction.

A recent article by Ciocca et al. described a similar technique.<sup>16</sup> The method described in this article requires only one scan, eliminating the need for eight random scans to record all of the undercut areas because, the scanner that we used was more advanced.

Several techniques have been reported to fabricate a mirror-image wax cast for digital prostheses; however, these techniques are costly and may require more time than manual fabrication.<sup>16,17</sup> The present report describes a simple, inexpensive, and repeatable method for obtaining a definitive wax cast for a toe prosthesis. The custom-made color-

matched toe prosthesis is esthetically acceptable and comfortable for use in patients who have lost a finger.

Other recent studies have proposed use of scanning methods which employ custom-made laser scanners or expensive rapid prototyping devices.<sup>18,19</sup> This technique requires only a conventional laser scanner and a commercial 3-D printer and is also faster and less expensive than the work of an anaplastologist which is done by hand. The method described in the present report does not require any scanning of the patient's tissue; it requires just making an impression of the remaining toe on the opposite foot. The primary advantage of this technique is virtual 3-D integration of the defective surface with the mirrored and digitalized normal toe. A drawback of fabricating toe prostheses using a 3-D modeling technique is the lack of detailed color information.

Future developments should include a color map of the definitive prosthesis by means of spec-

trophotometer-assisted color calibration of the surface.<sup>16</sup>

Mardini et al.<sup>15</sup> used CAD-CAM and Rapid Prototyping technology in production of auricular prostheses. We modified this technique for fabricating toe prostheses.

This article presents a technique developed to fabricate a custom made digital prosthesis that is hygienic, easy to use and esthetically acceptable to the patient by incorporating an artificial nail into a medical grade silicone digit prosthesis.

### Acknowledgements

*The authors kindly express their gratitude to Türkiye Bilimsel ve Teknik Araştırma Kurumu-Bilim İnsanı Destekleme Daire Başkanlığı (TÜBİTAK-BİDEB) for inviting to Prof. Dr. Robert H. GLEW and wish to thank to Prof. Dr. Robert H. GLEW for reviewing English language proficiency.*

*The authors also thank to Prof. Dr. Bayram YILMAZ for reviewing English language proficiency.*

## REFERENCES

1. Alison A, Allen R, Cerullo L, Erb RA, Gion GG, Habakuk SW, et al. Digital prostheses. In: Mc. Kinstry RE, ed. *Fundamentals of Facial Prosthesis*. 1<sup>st</sup> ed. Arlington: ABI Professional Publications; 1995. p.181-92.
2. Pillet J. Esthetic hand prostheses. *J Hand Surg Am* 1983;8(5 Pt 2):778-81.
3. Markal Ertaş N, Çelebioğlu S. [The treatment of complicated digital defects by cross-finger adipofascial flap]. *Türkiye Klinikleri J Med Sci* 2004;24(2):153-8.
4. Pilley MJ, Quinton DN. Digital prostheses for single finger amputations. *J Hand Surg Br* 1999;24(5):539-41.
5. Hopper RA, Griffiths S, Murray J, Manktelow RT. Factors influencing use of digital prostheses in workers' compensation recipients. *J Hand Surg Am* 2000;25(1):80-5.
6. Pereira BP, Kour AK, Leow EL, Pho RW. Benefits and use of digital prostheses. *J Hand Surg Am* 1996;21(2):222-8.
7. Alison A, Mackinnon SE. Evaluation of digital prostheses. *J Hand Surg Am* 1992;17(5):923-6.
8. Lifchez SD, Marchant-Hanson J, Matloub HS, Sanger JR, Dzwierzynski WW, Nguyen HH. Functional improvement with digital prosthesis use after multiple digit amputations. *J Hand Surg Am* 2005;30(4):790-4.
9. Scolozzi P, Jaques B. Treatment of midfacial defects using prostheses supported by ITI dental implants. *Plast Reconstr Surg* 2004; 114(6):1395-404.
10. Aydin C, Karakoca S, Yilmaz H. Implant-retained digital prostheses with custom-designed attachments: a clinical report. *J Prosthet Dent* 2007;97(4):191-5.
11. Manurangsee P, Isariyawut C, Chatuthong V, Mekraksawanit S. Osseointegrated finger prosthesis: An alternative method for finger reconstruction. *J Hand Surg Am* 2000;25(1):86-92.
12. Kiat-Amnuay S, Gettleman L, Khan Z, Goldsmith LJ. Effect of adhesive retention of maxillofacial prostheses. Part 2: Time and re-application effects. *J Prosthet Dent* 2001;85 (5):438-41.
13. Lemon JC, Chambers MS, Wesley PJ, Martin JW. Technique for fabricating a mirror-image prosthetic ear. *J Prosthet Dent* 1996;75(3): 292-3.
14. Penkner K, Santler G, Mayer W, Pierer G, Lorenzoni M. Fabricating auricular prostheses using three-dimensional soft tissue models. *J Prosthet Dent* 1999;82(4):482-4.
15. Al Mardini M, Ercoli C, Graser GN. A technique to produce a mirror-image wax pattern of an ear using rapid prototyping technology. *J Prosthet Dent* 2005;94(2):195-8.
16. Ciocca L, Scotti R. CAD-CAM generated ear cast by means of a laser scanner and rapid prototyping machine. *J Prosthet Dent* 2004; 92(6):591-5.
17. Coward TJ, Watson RM, Wilkinson IC. Fabrication of a wax ear by rapid-process modeling using stereolithography. *Int J Prosthodont* 1999;12(1):20-7.
18. Reitemeier B, Notni G, Heinze M, Schöne C, Schmidt A, Fichtner D. Optical modelling of extraoral defects. *J Prosthet Dent* 2004;91(1): 80-4.
19. Cheah CM, Chua CK, Tan KH, Teo CK. Integration of laser surface digitizing with CAD/CAM techniques for developing facial prostheses. Part 1: Design and fabrication of prosthesis replicas. *Int J Prosthodont* 2003;16(4): 435-41.