



# The Story of an Uncommon Aspiration “Where is the Voice Prosthesis?”

## “Ses Protezimin Nerede?” Nadir Bir Aspirasyon Olgusu

 Neslihan ÖZÇELİK,<sup>a</sup>  
 Funda ÖZTUNA<sup>b</sup>

<sup>a</sup>Clinic of Chest Diseases,  
Kaçkar State Hospital,  
Rize, TURKEY

<sup>b</sup>Department of Chest Diseases,  
Karadeniz Technical University  
Faculty of Medicine,  
Trabzon, TURKEY

Received: 19.03.2018

Received in revised form: 09.08.2018

Accepted: 10.08.2018

Available online: 19.12.2018

Correspondence:

Neslihan ÖZÇELİK  
Kaçkar State Hospital,  
Clinic of Chest Diseases,  
Rize, TURKEY  
ozcelik.nesli@gmail.com

**ABSTRACT** Tracheo-esophageal speech prosthesis are devices used for voice rehabilitation of patients with total laryngectomy. This device is placed between the trachea posterior wall and the esophagus frontal wall by a surgical procedure. Although there are various complications related to the use of the device, aspiration of the device is a rare situation. A patient undergoing total laryngectomy 14 years ago, when woken up one morning he noticed that the voice prosthesis was not in place and he applied to the otorhinolaryngology clinic. The patient had no respiratory complaints. The patient was not aware that he had aspirated his prosthesis. Hyperlucency at the right lung was detected on chest film. Diagnostic flexible fiberoptic bronchoscopy showed Provox voice prosthesis at the main carina. The device was removed with forceps without complication. In conclusion, Even without respiratory complaints, the possibility of aspiration with lost voice prosthesis in patients should always be considered.

**Keywords:** Voice prosthesis; aspiration; bronchoscopy

**ÖZET** Trakeo-özofageal konuşma protezleri, total larenjektomili hastaların ses rehabilitasyonu için kullanılan cihazlardır. Cerrahi bir işlem ile trakea arka duvarı ile özofagus ön duvarı arasında yerleştirilir. Cihaz kullanımına bağlı çeşitli komplikasyonlar olmakla birlikte cihazın aspire edilmesi nadir görülen bir durumdur. Bizim vakamızda; yaklaşık 14 yıl önce total larenjektomi yapılan hasta bir sabah uyandığında ses protezinin yerinde olmadığını fark ederek kulak burun boğaz kliniğine başvurdu. Hastanın hiçbir solunumsal şikâyeti yoktu. Hasta protezi aspire edip etmediğinin farkında değildi. Çekilen akciğer filminde sağ akciğerde hiperlüksensi saptandı. Tanısal amaçlı yapılan fleksibl fiberoptik bronkoskopiye ses protezi ana karinaya yerleşmiş şekilde görüldü ve forceps yardımıyla komplikasyon gelişmeden çıkarıldı. Sonuç olarak solunumsal şikâyeti olmasa dahi, ses protezi kaybolan hastalarda aspirasyon ihtimali hekimlerin aklına gelmelidir.

**Anahtar Kelimeler:** Ses protezi; aspirasyon; bronkoskopi

The most successful method for speech rehabilitation in patients with total laryngectomy is voice prosthesis. These prostheses are surgically placed between the trachea posterior wall and the esophagus frontal wall. Various complications related to prosthesis usage can occur. Because voice prostheses are placed by a surgical procedure, aspiration into the bronchial system is a rare complication. In this study, we presented a case who referred to our clinic for voice prosthesis aspiration.

## CASE REPORT

A 55-year-old male patient who underwent total laryngectomy operation about 14 years ago due to laryngeal carcinoma was referred to our clinic because he could not find his voice prosthesis. The patient had received chemotherapy and radiation therapy after total laryngectomy. He had been using voice prosthesis for 10 years. When he woke up in the morning, he realized that there was no voice prosthesis and he applied to the otolaryngology outpatient clinic with this complaint. The patient had no symptoms and he did not realize that he was depriving his prosthesis, swallowing it, or aspirating it. Aspiration was suspected and the patient had no complaints such as shortness of breath or cough. There was hyperlucency in the right lung on chest X-ray (Figure 1). Respiratory physical examination was normal. Flexible bronchoscopy revealed that the two sheets of voice prosthesis were sitting at the carina and the stem part extended to the trachea and there was no fistula between trachea and esophagus were observed. The device was successfully removed with the help of biopsy forceps. Apparently it was a device about 6 cm in length (Figure 2). Signed patient consent was obtained for publication of the case.

## DISCUSSION

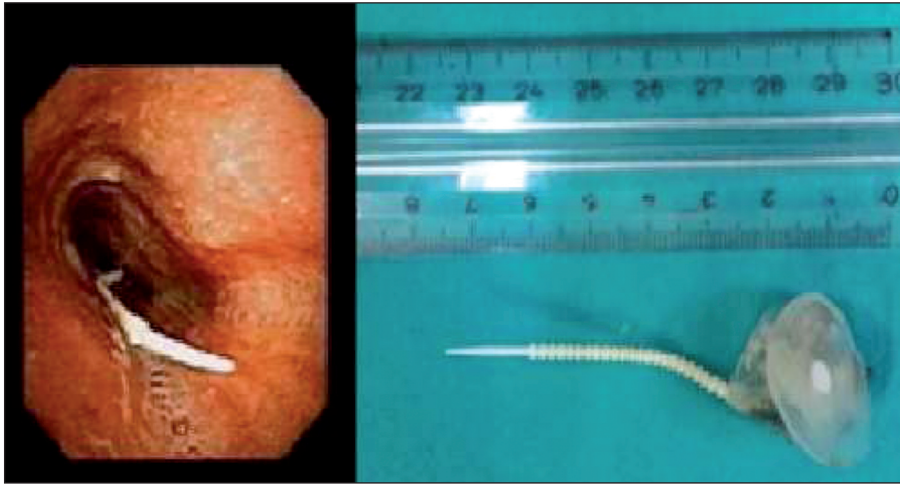
Total laryngectomy is a surgical procedure for advanced laryngeal tumors, in which hyoid bone and

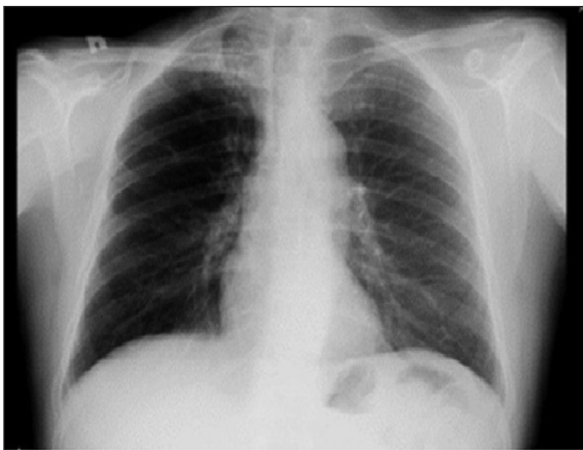

FIGURE 1: Chest X-ray of the patient, hyperlucency at the right lung.

epiglottia are removed from the laryngeal tissues including the muscles, hypopharynx, and part of the thyroid gland up to the tracheal ring below. Postoperative loss of voice is the most important factor affecting the quality of life of the patient. After the first total laryngectomy operation in America in 1879, the patient committed suicide because he lost his voice.<sup>1</sup> The ability to provide a clear talk in these patients has become a part of the cure. There are three methods for voice rehabilitation. These methods include artificial larynx speech, esophageal speech, and placement of the prosthesis after opening the tracheoesophageal fistula.<sup>2</sup> The choice of a method should be based on input from the surgeon, speech pathologist, and patient. The best decision is made by considering the patient's communication needs, physical and mental condition and personal preference. Artificial larynx speech is an external mechanical sound source that is substituted for the larynx. It is not preferred because the voice quality sounds mechanical and hard-to-understand. Esophageal sound takes about 6 months to learn and every patient can not succeed.<sup>3</sup> This method provides short-term sound generation. The third method is to place a mechanical speech prosthesis in this area by creating tracheoesophageal fistula. Tracheo-esophageal voice prostheses are the most commonly used method for making voice successfully.<sup>4</sup> Advantages of this method; It makes clear sound quickly and easy to use by the patient.<sup>5</sup> Fistula opening operation during laryngectomy (primary) or after (secondary) is performed. The need for additional surgical intervention, prosthetic complications and cost of prosthesis are significant disadvantages of this method.

Some complications are encountered during the use of these prostheses. These complications are divided into early (developing in the first week) and late (developing after one week). Early complications are; Hemorrhage, edema, infection, abscess development and mediastinitis, saliva and food leaks from around the prosthesis, and removal of the prosthesis.<sup>6</sup> Late complica-



**FIGURE 2:** Flexible bronchoscopy image and aspirated voice prosthetic device. (The stem of the voice prosthesis appears to extend towards the trachea).

tions are fungal colonization on the prosthesis, formation of granulation tissue and associated device shape changes, formation of saliva leaks and escape of the device to the stomach and the lung. Aspiration of the device is a rare condition.<sup>7</sup> In the literature, aspiration cases were reported to be located in the right main bronchus, but in our case, two leaf of the voice prosthesis was sitting on the main carina.<sup>8</sup>

In patients with voice prosthetic aspiration, patients may present with shortness of breath and cough symptoms. Some cases have been reported to be clinically asymptomatic, especially in the early period, as in our case.<sup>7</sup> If aspiration is not noticed in patients using such devices, it may cause complications such as atelectasis, bronchiectasis, bronchial stricture and pneumonia. More serious complications are aspiration pneumonia, mediastinitis and sepsis. Therefore, physicians should keep in mind the voice prosthesis aspiration.

#### **Source of Finance**

*During this study, no financial or spiritual support was received neither from any pharmaceutical company that has a direct connection with the research subject, nor from a company that provides or produces medical instruments and materials which may negatively affect the evaluation process of this study.*

#### **Conflict of Interest**

*No conflicts of interest between the authors and / or family members of the scientific and medical committee members or members of the potential conflicts of interest, counseling, expertise, working conditions, share holding and similar situations in any firm.*

#### **Authorship Contributions**

**Idea/Concept:** Funda Öztuna, Neslihan Özçelik; **Design:** Funda Öztuna; **Supervision/Consultancy:** Funda Öztuna, Neslihan Özçelik; **Data Collection and/or Processing:** Funda Öztuna, Neslihan Özçelik; **Analysis and/or Interpretation:** Funda Öztuna, Neslihan Özçelik; **Resource Scanning:** Neslihan Özçelik; **Critical Review:** Neslihan Özçelik, Funda Öztuna; **Materials:** Funda Öztuna, Neslihan Özçelik.

## REFERENCES

1. Erişir F, İnci E. [Vocal rehabilitation following total laryngectomy]. *Cerrahpaşa J Med* 2001;32(2):80-5.
2. Karlen RG, Maisel RH. Does primary tracheoesophageal puncture reduce complications after laryngectomy and improve patient communication? *Am J Otolaryngol* 2001; 22(5):324-8.
3. Kılıç C, Tunçel Ü, Cömert E. [Provox 2 use for voice restoration after total laryngectomy]. *Kulak Burun Bogaz İhtis Derg* 2013;24(6):339-43.
4. Akbaş Y, Dursun G. Voice restoration with low pressure blom singer voice prosthesis after total laryngectomy. *Yonsei Med J* 2003;44(4): 615-8.
5. Cömert E, Tunçel Ü, Kılıç C, Cengiz B, Seçkin E, Kaya M. [The complications of primary tracheoesophageal puncture and its effects on speech function]. *Ankara Üniversitesi Tıp Fakültesi Mecmuası* 2012;65(3):163-8.
6. Bozec A, Poissonnet G, Chamorey E, Demard F, Santini J, Peyrade F, et al. Results of vocal rehabilitation using tracheoesophageal voice prosthesis after total laryngectomy and their predictive factors. *Eur Arch Otorhinolaryngol* 2010;267(5):751-8.
7. Ostrovsky D, Netzer A, Goldenberg D, Joachims HZ, Golz A. Delayed diagnosis of tracheoesophageal prosthesis aspiration. *Ann Otol Rhinol Laryngol* 2004;113(10):828-9.
8. Conte SC, De Nardi E, Conte F, Nardini S. Aspiration of tracheoesophageal prosthesis in a laryngectomized patient. *Multidiscip Respir Med* 2012;7(1):25.