

Guyon's Canal Syndrome Secondary to Ulnar Artery Stenosis Caused by a Constricting Fibrous Band; a Rare Cause of Ulnar Nerve Compression

Fibröz Bant Basısına Bağlı Ulnar Arter Stenozu Sonucunda Gelişen Guyon Kanal Sendromu; Nadir Bir Olgu

Yunus DOĞRAMACI, MD,^a
Aydın KALACI, MD,^a
Erdoğan ESEN, MD,^a
Teoman T. SEVİNÇ, MD,^a
Anil EMİR, MD,^a
Ahmet Nedim YANAT, MD^a

^aDepartment of Orthopaedics and Traumatology, Mustafa Kemal University Faculty of Medicine, Hatay

Geliş Tarihi/Received: 11.05.2009
Kabul Tarihi/Accepted: 17.10.2009

Yazışma Adresi/Correspondence:
Erdoğan ESEN, MD
Mustafa Kemal University
Faculty of Medicine,
Department of
Orthopaedics and Traumatology,
Hatay,
TÜRKİYE/TURKEY
erdincesen@gmail.com

ABSTRACT Guyon's canal is not a common site of ulnar nerve compression at the wrist. Ganglia, lipoma, anomalous tendons and muscles, trauma related to an occupation, arthritis, and carpal bone fractures can cause ulnar nerve compression at the wrist. Ulnar nerve compression at Guyon's canal secondary to pathologic conditions involving the ulnar artery is also rare. Ulnar artery aneurysm, tortuous ulnar artery, hemangioma, and thrombosis have been reported in the literature as vascular lesions. However, ulnar nerve compression at Guyon's canal by a constricting fibrous band has not been reported. The authors experienced a case of ulnar nerve compression at Guyon's canal by a constricting fibrous band and the patient's symptoms improved after surgical resection. This report is, to the best of our knowledge, the first on ulnar neuropathy in the Guyon's canal caused by a constricting fibrous band of the ulnar artery. We can not easily predict constricting fibrous band as a cause of ulnar nerve compression at Guyon's canal. However, if there is not an obvious etiology, we should consider a constricting fibrous band as another possible etiology.

Key Words: Constriction, pathologic; hand; ulnar nerve compression syndromes

ÖZET Guyon kanalı, ulnar sinir basısının sık görüldüğü bir yer değildir. Sebep sıklıkla gangliyon, lipom, anomalili tendonlar ve kaslar, mesleğe bağlı travma, artrit ve bilek kemiği kırıklarıdır. Ulnar arteri ilgilendiren patolojik bir duruma bağlı gelişen Guyon kanalında ulnar sinir basısı nadirdir. Ulnar arter anevrizması, kıvrımlı ulnar arter, hemanjiyom ve tromboz literatürde vasküler lezyon olarak bildirilmiştir. Fakat Guyon kanalında fibröz bant nedeniyle gelişen ulnar sinir basısı rapor edilmemiştir. Yazarlar, Guyon kanalında fibröz bant nedeniyle gelişen ulnar sinir basısına rastlamışlar ve hastanın semptomları cerrahi rezeksiyondan sonra geçmiştir. Bu olgu, bildiğimiz kadarıyla, Guyon kanalında ulnar arterin fibröz bant basısına bağlı gelişen ilk ulnar nöropatidir. Fibröz bantın sıkmasıyla Guyon kanalında ulnar sinire bası gelişebileceği kolaylıkla öngörülemez. Bununla birlikte, eğer belirgin bir etiyoloji yoksa bu durum göz önünde bulundurulmalıdır.

Anahtar Kelimeler: Daralma, patolojik; el; ulnar sinir kompresyon sendromu

Türkiye Klinikleri J Med Sci 2011;31(4):1030-3

Guyon's canal syndrome secondary to space occupying lesions such as ganglia, lipomas and anomalous muscles are well recognized. On rare occasions, vascular lesions of the ulnar artery inside the Guyon's canal may result in ulnar nerve compression. These include hemangiomas, aneurysms, thromboses, a tortuous ulnar artery and arteriovenous malformations.¹⁻⁵ We report a case with dilatation of the ulnar artery in the Guyon's canal secondary to a constricting fibrous band, as the cause of ulnar nerve compression.

CASE REPORT

A 56-year-old housewife, presented with a one week history of acute pain and numbness in her fourth and fifth fingers as well as poor grip. Her past medical history revealed previously diagnosed bilateral carpal tunnel syndrome and systemic hypertension. The symptoms started after she had stopped taking her anti-hypertensive medications in the previous month. General examination revealed a high blood pressure of 170/110 mmHg. On local examination, there was sensory impairment to light touch in the right fifth finger and at the ulnar half of the fourth finger, Tinel's sign was positive on the ulnar (ulnar nerve) and radial side (median nerve) of the wrist and there was marked weakness of the finger adductor muscles. Radial and ulnar artery pulses were present. Laboratory studies including complete blood count, erythrocyte sedimentation rate, and blood biochemistry were all normal. Radiographs of the wrist and hand revealed normal findings. As she had experienced cervical pain a few months before, a magnetic resonance imaging (MRI) of the cervical spine was performed that showed no cervical myelopathy or compression of cervical roots. Nerve conduction studies revealed compression of the ulnar nerve at the Guyon's tunnel. A diagnosis of chronic carpal tunnel syndrome and acute Guyon's tunnel syndrome was established.

Surgical exploration of the carpal and Guyon's tunnels was performed under general anesthesia. The transverse carpal ligament was divided and the median nerve was found to be entrapped under the transverse carpal ligament. A distended pulsatile superficial palmar arch was observed at the distal part of the carpal canal. Further dissection revealed an abnormal scar tissue acting as a constricting fibrous band, originating from the transverse carpal ligament and extending to the palmar carpal ligament, causing subtotal obstruction of the ulnar artery in the middle third of Guyon's tunnel. The ulnar artery was found to be dilated, proximal and distal to the site of constriction and impinging on the ulnar nerve (Figures 1, 2).

The band was excised and the dilatation was resolved (Figure 3).

The symptoms resolved completely the next day. No recurrence was observed on six months follow-up period.

DISCUSSION

Ulnar nerve compression can occur anywhere along its course through Guyon's canal, giving rise to sensory and/or motor symptoms. Compressions in the wrist and hand have been divided into three types.⁶ The most common reported causes are the various types of acute or chronic trauma most likely related to occupation.⁷ There are many other possible causes including ganglia, carpal bone fractures, ulnar artery disease, anomalous muscles, rheumatoid arthritis and lipoma.^{8,9}

Several cases of ulnar nerve lesions at the wrist have been classically described in cyclists due to positioning of their hands on the handlebars.^{7,9} On the other hand, some of the cases with carpal tunnel syndrome developed a concomitant ulnar nerve compression at the wrist with an atypical fibrous band, which passed from the pisiform bone to the palmar carpal ligament; the nerve was constricted, proximal to the musculotendinous arch, and the superficial sensory branch and a part of the deep branch were affected which carried the branch supplying abductor digiti minimi.¹⁰

Lesions of the ulnar artery have been reported in association with symptoms of ulnar nerve compression in Guyon's canal.² The most common ulnar artery lesions are aneurysmal dilatations and thromboses. Guyon's tunnel syndrome secondary to arteriovenous malformation of the ulnar artery and vein has been reported.⁵ Another cause is a tortuous ulnar artery in association with ulnar nerve compression.⁴ The exact pathology is not clear. However, increased local pressure may result in ischemia and fibrosis of the ulnar nerve.⁵

Our patient had a sudden onset of motor and sensory deficits in the ulnar nerve following the

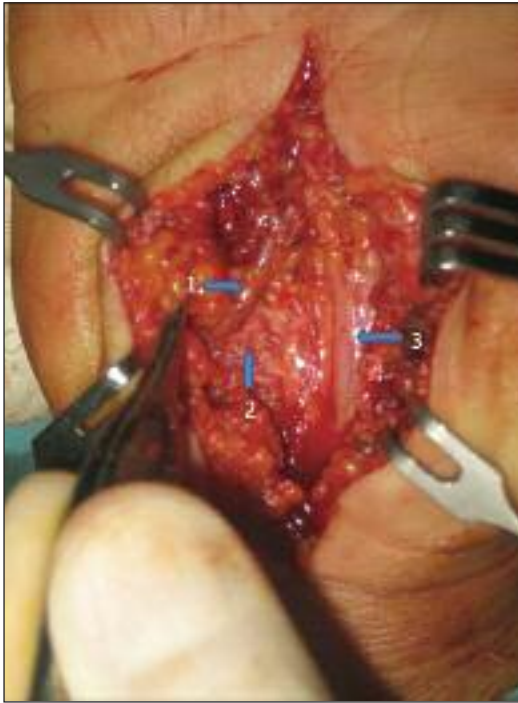


FIGURE 1: Fibrous band overlying the ulnar artery. Before resection of the fibrous band. (Arrow 1: ulnar artery, Arrow 2: fibrous band over the ulnar artery, Arrow 3: median nerve).

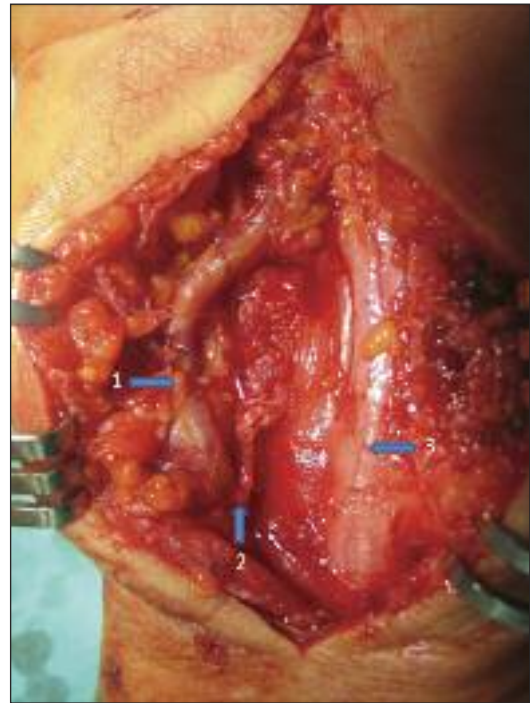


FIGURE 2: Lesion site after partial resection of the fibrous band. Note the ulnar artery distension proximal and distal to the band. (Arrow 1: fibrous band, Arrow 2: transverse carpal ligament, Arrow 3: median nerve).

discontinuation of the anti-hypertensive medications. It is most likely that acute dilatation of the pre-stenotic ulnar artery, which might have been provoked by high blood pressure, may account for the compression of the ulnar nerve. Early and complete resolving of the symptoms may indicate temporary ischemia of the ulnar nerve.

In this case we did not perform Adson test, angio-MR or angio-CT of the wrist which were necessary for preoperative planning.

In conclusion, we described a case of acute Guyon's tunnel syndrome in which a local abnormality, a constricting fibrous band, and a systemic disorder, high arterial blood pressure, might have played a possible role in the pathophysiology. Vascular compression should be suspected in hypertensive patients with symptoms of Guyon's tunnel syndrome, when no other etiologic factors are found.

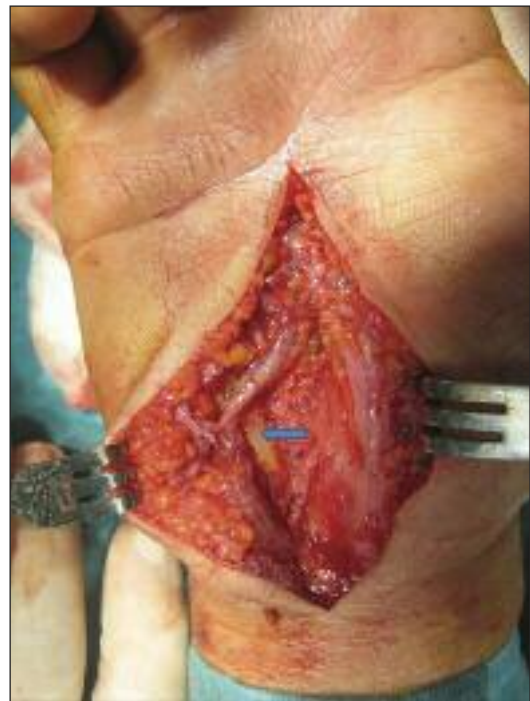


FIGURE 3: After resection of fibrous band, the ulnar artery stenosis was resolved. Ulnar nerve is shown (blue arrow).

REFERENCES

1. Koch H, Haas F, Pierer G. Ulnar nerve compression in Guyon's canal due to a haemangioma of the ulnar artery. *J Hand Surg Br* 1998;23(2):242-4.
2. Kalisman M, Laborde K, Wolff TW. Ulnar nerve compression secondary to ulnar artery false aneurysm at the Guyon's canal. *J Hand Surg Am* 1982;7(2):137-9.
3. Yoshii S, Ikeda K, Murakami H. Ulnar nerve compression secondary to ulnar artery true aneurysm at Guyon's canal. *J Neurosurg Sci* 1999;43(4):295-7.
4. Jose RM, Bragg T, Srivastava S. Ulnar nerve compression in Guyon's canal in the presence of a tortuous ulnar artery. *J Hand Surg Br* 2006;31(2):200-2.
5. Ozdemir O, Calisaneller T, Altinors N. Compression of the ulnar nerve in Guyon's canal by an arteriovenous malformation. *J Hand Surg Eur Vol* 2007;32(5):600-1.
6. Seror P. Ulnar conduction block at the wrist. *Arch Phys Med Rehabil* 1999;80(10):1346-8.
7. Subin GD, Mallon WJ, Urbaniak JR. Diagnosis of ganglion in Guyon's canal by magnetic resonance imaging. *J Hand Surg Am* 1989; 14(4):640-3.
8. Capitani D, Beer S. Handlebar palsy--a compression syndrome of the deep terminal (motor) branch of the ulnar nerve in biking. *J Neurol* 2002;249(10):1441-5.
9. Cassvan A, Rosenberg A, Rivera LF. Ulnar nerve involvement in carpal tunnel syndrome. *Arch Phys Med Rehabil* 1986;67(5):290-2.
10. Hirooka T, Hashizume H, Nagoshi M, Shigeyama Y, Inoue H. Guyon's canal syndrome. A different clinical presentation caused by an atypical fibrous band. *J Hand Surg Br* 1997;22(1):52-3.