

## CASE REPORT

DOI: 10.5336/caserep.2023-100227

# Surgical Site Infection After Cesarean Section in a Patient with Ichthyosis Vulgaris

Merve CELLEK<sup>a</sup>, Özlem MORALOĞLU<sup>b</sup>, Muzaffer CAYDERE<sup>c</sup><sup>a</sup>Kırıkkale Yüksek İhtisas Hospital, Clinic of Obstetrics and Gynecology, Kırıkkale, Türkiye<sup>b</sup>Ankara City Hospital, Clinic of Obstetrics and Gynecology, Ankara, Türkiye<sup>c</sup>Ankara Training and Research Hospital, Clinic of Pathology, Ankara, Türkiye

**ABSTRACT** Ichthyosis vulgaris, the most common type of ichthyoses, is characterized by filaggrin dysfunction, pathological keratinization and compromised barrier function that may results in microbial colonizations and skin infections. Despite its prevalence, surgical wound complications following cesarean section in these patients have not been described. This study aimed to report a patient with ichthyosis vulgaris who developed surgical site infection after cesarean section. A 26-year-old primigravida patient with history of ichthyosis vulgaris underwent cesarean section. Three days postoperatively, wound discharge was observed, leading to treatment with antibiotics and continuous dressing. Subsequently, debridement and secondary wound closure resulted in immediate healing. It is crucial to implement preventive measures and provide thorough care during both childbirth and surgical procedures to protect them from skin infections.

**Keywords:** Cesarean section; ichthyosis vulgaris; surgical site infection

The ichthyoses are large and heterogeneous group of genetic disorders of keratinization characterized by generalized scaling of the skin.<sup>1</sup> The most common form of nonsyndromic ichthyoses is ichthyosis vulgaris with an estimated incidence of 1 in 250 births, manifesting in early childhood, symptoms may even be present at birth.<sup>2</sup> Cutaneous findings range from xerosis to severe scaling. Lifelong treatment involving emollients, humectants, keratolytics, and retinoids is usually effective in alleviating symptoms.<sup>2,3</sup>

The pathogenesis of ichthyoses is intricately linked to the keratinization process, involving the regulated differentiation of keratinocytes across epidermal layers. To maintain epidermal homeostasis, the pace of keratinocyte proliferation in the stratum

basale must harmonize with the rate at which cornified cells are shed from the stratum corneum.<sup>3</sup> Abnormalities in any of these steps of programmed cell death lead to a similar epidermal response with epidermal hyperplasia, formation of excess stratum corneum, abnormal desquamation and scales on the skin surface.<sup>4</sup> Defective formation of the cornified lipid envelope results in impaired barrier function, potentially leading to microbial colonization as well as infections.<sup>5,6</sup>

A systematic review of the relationship between ichthyoses and surgical site infections is currently lacking. In this report, we described the case of one such post-cesarean patient and summarized the possible mechanisms responsible for the susceptibility to surgical site infection on the basis of ichthyosis vulgaris.

**Correspondence:** Merve CELLEK

Kırıkkale Yüksek İhtisas Hospital, Clinic of Obstetrics and Gynecology, Kırıkkale, Türkiye

**E-mail:** merve.erel@hotmail.com

Peer review under responsibility of Türkiye Klinikleri Journal of Case Reports.

**Received:** 09 Nov 2023

**Accepted:** 27 Mar 2024

**Available online:** 05 Apr 2024

2147-9291 / Copyright © 2024 by Türkiye Klinikleri. This is an open access article under the CC BY-NC-ND license (<http://creativecommons.org/licenses/by-nc-nd/4.0/>).



## CASE REPORT

A 26-year-old primigravid woman admitted to our institution in active labor. In her medical history, the patient had been diagnosed with ichthyosis vulgaris during infancy. Her parents had a consanguineous marriage and she had a younger sister exhibiting similar symptoms. She had been required to take measures to hydrate whole body with lotion or petroleum jelly. She denied other medical problems, and was not on any regular oral medications, her body mass index was normal range before pregnancy (22.8 kg/m<sup>2</sup>).

Dermatologic consultation was obtained for skin-care recommendations. Upon examination, exfoliative changes were observed on her trunk, back, and extremities. Mild palmo-plantar hyperkeratosis was noted. The patient was already paying close attention to the condition of the skin and was especially attentive in using petroleum jelly to heal any sores.

The patient presented with labor pain. Due to arrest of labor, cesarean section was considered as the method of birth. Prior to surgery, abdominal area was surgically scrubbed with 10% povidone iodine solution and the patient was administered 2 g cefazolin at the time of surgery. A healthy female baby, weighing 2.74 kg, was delivered. The baby did not exhibit scaly skin. On the first postoperative day, dressing was removed, and wound was cleansed with povidone iodine.

On postoperative day 3, local swelling, induration and erythema developed at the incision site with serous drainage, prompting the initiation of empiric antibiotic therapy with intravenous ampicillin/sulbactam. Next day, the amount of wound discharge increased and 2 cm wound dehiscence was observed. Blood tests showed a white blood cell (WBC) count of  $9.8 \times 10^3/\mu\text{L}$  (normal range  $4\text{--}10.3 \times 10^3/\mu\text{L}$ ) and C-reactive protein (CRP, nephelometric) of 329 mg/L (normal range 0–8 mg/L). A sample for wound culture was collected.

By the eighth day, the wound drainage became seropurulent and persisted. The skin sutures were taken out, revealing intact fascia. Her laboratory studies revealed WBC count of  $30.72 \times 10^3/\mu\text{L}$  and CRP

of 292 mg/L. *Enterobacter* spp was isolated from wound culture. Isolated pathogen was resistant to ampicillin/sulbactam, leading to a change in antibiotics to intravenous meropenem and continued wound dressing with rifampin.

On the tenth postoperative day, the antibiotic treatment regimen was adjusted, with addition of metronidazole because of fever up to 38°C. In eleventh day, the patient developed a fever up to 39°C, the second culture grew *Enterobacter* spp again. Infectious diseases specialist added teicoplanin to antibiotherapy.

On the seventeenth postoperative day, blood tests were as follows: WBC,  $10 \times 10^3/\mu\text{L}$ ; CRP, 28 mg/L. No microorganism was isolated from the third culture obtained. Excisional wound debridement and secondary suturing was performed at the operating room (Figure 2).

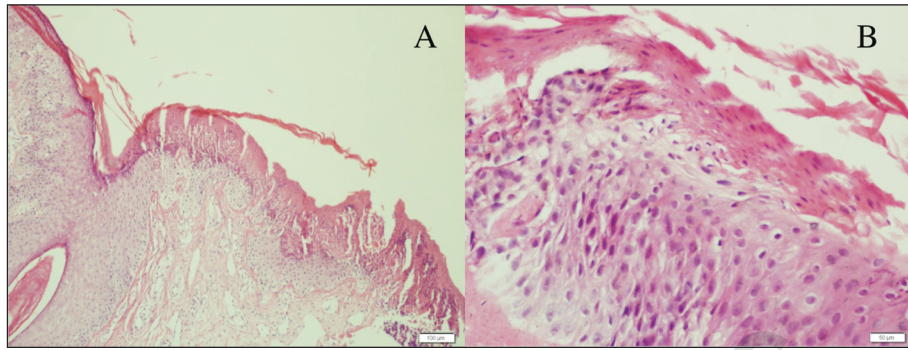
Her skin biopsy showed fragmentation in ulcerated squamous epithelium and hyperkeratosis with normal dermis and focal parakeratosis (Figure 3).

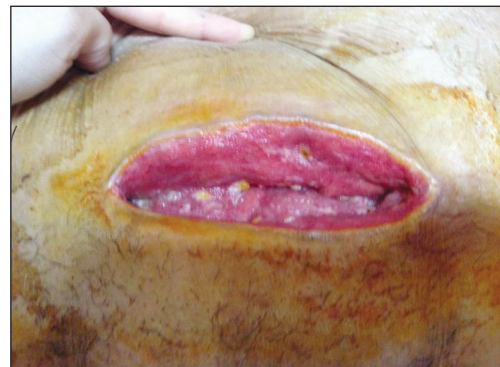

FIGURE 1: Photograph of surgical incision after sutures are removed.

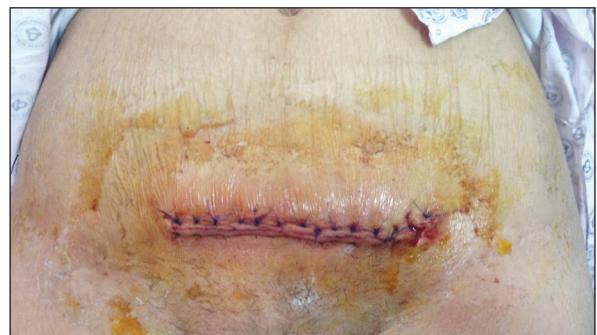

FIGURE 2: Photograph of surgical incision after second suturing. Note the dry, striated appearance on the trunk.



**FIGURE 3:** Skin biopsy of incision before seconder suturation (Hematoxylen-Eosin stain). Scale bar represents 100  $\mu\text{m}$  (A) and 50  $\mu\text{m}$  (B).

The day after secondary suturing, the patient was discharged from hospital. Later, after 10 days post-discharge, the sutures were removed.

Informed consent form was obtained from the patient.

## DISCUSSION

Ichthyosis vulgaris is caused by loss of function mutations in the filaggrin gene and is inherited in an autosomal semidominant fashion with incomplete penetrance. Our patient's diagnosis has been made clinically and supported by biopsy. Although there is a consensus agreement that diagnosis of ichthyosis vulgaris can be made through clinical-based classification, genetic testing for *FLG* gene may be useful in differential diagnosis.<sup>1</sup> Filaggrin, a multi-functional structural protein, crucially aids in keratin aggregation, reinforcing the mechanical resilience of the stratum corneum cytoskeleton.<sup>2,7</sup> Ultimately, filaggrin undergoes breakdown into water-retaining amino acids which are natural moisturizing factors that hydrate the skin, and its acidic substances that maintain acidic pH, photosensitivity, skin elasticity, and restrict microbial overgrowth.<sup>3,5,7,8</sup> Altered filaggrin expression increases the fragility and permeability of the stratum corneum. This deterioration results in excessive transepidermal water loss and weakening of the immune defense against allergens and microorganisms despite thick stratum corneum.<sup>2,3</sup>

Filaggrin breakdown products urocanic acid and pyrrolidone carboxylic acid are shown to reduce growth of *Staphylococcus aureus* by acidifying the

skin and also decreasing bacterial protein expression for colonization and immune evasion. So, mutations of the filaggrin gene in ichthyosis, reduce levels of these products, leading to increased bacterial colonization.<sup>9</sup> Yet, studies clinically supporting this in-vitro findings are still lacking for ichthyosis vulgaris, except some new animal studies.<sup>10</sup>

Filaggrin variations also constitute a significant risk factor for developing atopic dermatitis. Both ichthyoses and atopic dermatitis, that result from defective formation of the surface barrier, are characterized by skin microbiome dysbiosis.<sup>11</sup> Atopic dermatitis is considered one of the risk factors for surgical site infection characterized by *Staphylococcus aureus* colonization.<sup>12</sup> A similar mechanism may be applicable in ichthyosis as well. The correlation between atopy and chronic fungal infection is also acknowledged, particularly in relation to T-helper 1 and T-helper 2 imbalances. Similarly, patients with ichthyoses appear to be at an elevated risk of developing cutaneous fungal infections.<sup>13</sup> Consequently, compromised barrier function may cause complications like bacterial, viral and fungal colonization and infections in the skin.

A surgical site infection refers to an infection in the incision or organ/space at the operation site, occurring within 30 days following surgery. Risk factors for surgical site infection encompass factors indicating the level of microbial contamination, surgical procedure characteristics, and host susceptibility markers. Some of the patient susceptibility factors for cesarean section include obesity, perioperative

hyperglycemia, smoking, nutritional status, emergency cesarean delivery, increased depth of subcutaneous tissue, coexistent infection at a remote body site, vagina colonization with pathogenic microorganisms.<sup>14</sup> However, compromised skin barrier diseases such as ichthyoses are among the patient characteristics that are not adequately paid attention to in these lists and studies. We suggest that, as supported by other cases, patients with ichthyoses undergoing surgery may be at higher risk of infection with possible mechanisms as discussed above.<sup>2,6,13</sup>

The treatment of postoperative patients with such diseases should prioritize wound healing, improving skin barrier function, and prevention of infection.<sup>4</sup> Women with ichthyoses necessitate specialized care during childbirth and surgical procedures, particularly cesarean sections. Besides the standard preventive measures in hospitals, these patients require additional care for managing their skin disorder. Utilizing chlorhexidine-alcohol for preoperative skin cleansing appears to be preferable choice over povidone-iodine, as it has demonstrated superior protection against incisional infections.<sup>15</sup> Furthermore, the use of iodine-based disinfectants may lead to excessively dry skin, skin irritation, and even burns.<sup>16</sup> The standard antiseptic skin preparation in our hospital involves 10% povidone-iodine solution.

However, povidone-iodine may have exacerbated xerosis and potentially induced a disease flare-up.

Further studies are needed to establish whether patients with ichthyoses are indeed more susceptible to infections, particularly following surgical procedures.

### Source of Finance

*During this study, no financial or spiritual support was received neither from any pharmaceutical company that has a direct connection with the research subject, nor from a company that provides or produces medical instruments and materials which may negatively affect the evaluation process of this study.*

### Conflict of Interest

*No conflicts of interest between the authors and / or family members of the scientific and medical committee members or members of the potential conflicts of interest, counseling, expertise, working conditions, share holding and similar situations in any firm.*

### Authorship Contributions

**Idea/Concept:** Merve Cellek, Özlem Moraloğlu; **Design:** Merve Cellek; **Control/Supervision:** Merve Cellek, Özlem Moraloğlu; **Data Collection and/or Processing:** Merve Cellek, Özlem Moraloğlu, Muzaffer Çaydere; **Analysis and/or Interpretation:** Merve Cellek, Muzaffer Çaydere; **Literature Review:** Merve Cellek; **Writing the Article:** Merve Cellek; **Critical Review:** Merve Cellek, Özlem Moraloğlu; **References and Fundings:** Özlem Moraloğlu; **Materials:** Merve Cellek, Özlem Moraloğlu, Muzaffer Çaydere.

## REFERENCES

- Oji V, Tadini G, Akiyama M, Blanchet Bardon C, Bodemer C, Bourrat E, et al. Revised nomenclature and classification of inherited ichthyoses: results of the First Ichthyosis Consensus Conference in Sorèze 2009. *J Am Acad Dermatol*. 2010;63(4):607-41. PMID: 20643494.
- Jaffar H, Shakir Z, Kumar G, Ali IF. Ichthyosis vulgaris: An updated review. *Skin Health Dis*. 2022;3(1):e187. PMID: 36751330; PMCID: PMC9892433.
- Vahlquist A, Törmä H. Ichthyosis: a road model for skin research. *Acta Derm Venereol*. 2020;100(7):adv00097. PMID: 32147743; PMCID: PMC9128938.
- Joosten MDW, Clabbers JMK, Jonca N, Mazereeuw-Hautier J, Gostyrski AH. New developments in the molecular treatment of ichthyosis: review of the literature. *Orphanet J Rare Dis*. 2022;17(1):269. PMID: 35840979; PMCID: PMC9287901.
- Jonca N, Simon M. The cornified envelope: a versatile contributor to the epidermal barrier. *J Invest Dermatol*. 2023;143(8):1335-7. PMID: 37149811.
- Bernasek TL, Rommel EA. Complex total hip replacement in a patient with epidermolytic hyperkeratosis. A case report. *J Bone Joint Surg Am*. 2005;87(12):2775-9. PMID: 16322630.
- Hoover JK, Eggink LL. The discovery and function of filaggrin. *Int J Mol Sci*. 2022;23(3):1455. PMID: 35163390; PMCID: PMC8835998.
- Hansmann B, Schröder JM, Gerstel U. Skin-derived c-terminal filaggrin-2 fragments are pseudomonas aeruginosa-directed antimicrobials targeting bacterial replication. *PLoS Pathog*. 2015;11(9):e1005159. PMID: 26371476; PMCID: PMC4570713.
- Li R, Rodrigues M, Li L, Winget J, Wang Y, Wang C, et al. Association between skin acid mantle, natural moisturizing factors, and antibacterial activity against *S. aureus* in the stratum corneum. *Clin Cosmet Investig Dermatol*. 2023;16:1595-606. PMID: 37378303; PMCID: PMC10292209.
- Gonzalez JR, Celli A, Weckel A, Dhariwala MO, Merana GR, Ojewumi OT, et al. FLG Deficiency in Mice Alters the Early-Life CD4+ T-Cell Response to Skin Commensal Bacteria. *J Invest Dermatol*. 2023;143(5):790-800.e12. PMID: 36496196.
- Niehues H, Rikken G, Kersten FFJ, Eeftens JM, van Vlijmen-Willems IMJJ, Rodijk-Olthuis D, et al. CYSRT1: An antimicrobial epidermal protein that can interact with late cornified envelope proteins. *J Invest Dermatol*. 2023;143(8):1498-508.e7. PMID: 36804407.



- 
12. Yokoe T, Tajima T, Yamaguchi N, Morita Y, Chosa E. Surgical Wound Complications after Knee Cruciate Ligament Reconstruction in Patients with Atopic Dermatitis. *J Knee Surg.* 2021;34(11):1237-42. PMID: 32074657.
  13. Miao H, Dong R, Zhang S, Yang L, Liu Y, Wang T. Inherited ichthyosis and fungal infection: an update on pathogenesis and treatment strategies. *J Dtsch Dermatol Ges.* 2021;19(3):341-50. PMID: 33448147.
  14. Shea SK, Soper DE. Prevention of cesarean delivery surgical site infections. *Obstet Gynecol Surv.* 2019;74(2):99-110. PMID: 30756124.
  15. Darouiche RO, Wall MJ Jr, Itani KM, Otterson MF, Webb AL, Carrick MM, et al. Chlorhexidine-alcohol versus povidone-iodine for surgical-site antisepsis. *N Engl J Med.* 2010;362(1):18-26. PMID: 20054046.
  16. Lowe DO, Knowles SR, Weber EA, Railton CJ, Shear NH. Povidone-iodine-induced burn: case report and review of the literature. *Pharmacotherapy.* 2006;26(11):1641-5. PMID: 17064209.

ARTICLE IN PRESS