

Iliopsoas Abscess with Septic Arthritis of the Hip Following Trauma: Case Report

Travmayı Takiben Kalça Septik Artritinin Eşlik Ettiği İliopsoas Apsesi

Deniz AYGÜN,^a
Şule BEKTAŞ,^b
Haluk ÇOKUĞRAŞ,^a
Yıldız CAMCIOĞLU^a

Departments of
^aPediatric Infectious Diseases
Clinical Immunology and Allergy,
^bPediatrics,
İstanbul University
Cerrahpaşa Faculty of Medicine,
İstanbul

Geliş Tarihi/Received: 13.02.2017
Kabul Tarihi/Accepted: 19.04.2017

Yazışma Adresi/Correspondence:
Deniz AYGÜN
İstanbul University
Cerrahpaşa Faculty of Medicine,
Department of Pediatric Infectious
Diseases
Clinical Immunology and Allergy, İstanbul,
TURKEY/TÜRKİYE
fdenizaygun@gmail.com

ABSTRACT Iliopsoas abscess is a relatively uncommon but potentially life-threatening infection of extraperitoneal compartment. Iliopsoas abscess may be classified as primary or secondary. Primary abscess results from hematogenous spread of an infectious process from an occult source in the body. Trauma resulting in intramuscular hematoma formation can predispose to primary iliopsoas abscess formation. Iliopsoas abscess should be considered in patients presenting with lower back or hip pain and fever associated with trauma. Here, we describe two adolescent cases with iliopsoas abscess complicated by septic arthritis following trauma.

Keywords: Injuries; psoas abscess; arthritis, infectious

ÖZET İliopsoas apsesi nadir görülen fakat hayatı tehdit edici enfeksiyonlara neden olabilen ekstraperitoneal bir enfeksiyondur. Primer veya sekonder olabilir. Primer enfeksiyonlar genellikle vücuttaki gizli bir odaktan hematogen yayılım sonucu gelişir. Kas içi hematoma neden olan travmalar da primer enfeksiyonun sebebi olabilir. İliopsoas apseleri travmayı takiben gelişen ateşin eşlik ettiği sırt ve kalça ağrılarında akla gelmelidir. Bu yazıda, travma sonrası kalça septik artriti ile komplike olan iliopsoas apsesi gelişen iki adolesan hasta sunulmaktadır.

Anahtar Kelimeler: Yaralanmalar; psoas absesi; artrit, enfeksiyöz

Iliopsoas abscesses (IPA) are suppurative collections within the fascia surrounding the psoas and iliacus muscles. Although the incidence of iliopsoas abscesses seems to increase in recent years due to improvements in diagnostic imaging, the new studies still regard it as a rare disease. IPA is a serious condition with a high mortality rate if left untreated.¹ Unfortunately, it is often misdiagnosed because of nonspecific symptoms. The classic signs of the disease including fever, flank or back pain, lumbar tenderness, limitation of hip movement and limping are present in only 30% of patients.¹ Iliopsoas abscess was firstly reported by Mynter in 1881 as a complication of tuberculosis of spine and iliopsoas muscle.² At the present time, *Staphylococcus aureus* is the most common bacterial cause of iliopsoas abscess.³ Trauma resulting with intramuscular hematoma formation can predispose to iliopsoas abscess formation. Here, we report two adolescent cases diagnosed with iliopsoas abscess complicated by septic arthritis of hip following trauma. Methicillin sensitive *Staphylococcus aureus* was isolated from the abscess samples of both patients.

CASE REPORT

CASE 1

A 17 year-old obese boy presented with complaints of fever, malaise and left-side hip pain lasting for 1 week. He was unable to walk due to severe pain in his hip. On physical examination, he was febrile, he had redness, swelling, and increased warmth on the left gluteal region. Blood examination revealed leukocytosis ($29,600/\text{mm}^3$) with 90% neutrophils, erythrocyte sedimentation rate (ESR) level of 116 mm/hour, C-reactive protein (CRP) level of 387 mg/L. Magnetic resonance imaging (MRI) demonstrated a septated and multiloculated mass at the left iliopsoas muscle extending to left gluteal region indicating, hematoma, iliopsoas abscess and effusion of the hip joint with septic arthritis of the left hip (Figure 1).

CASE 2

The second patient, a 16 year-old male, was referred with a ten day history of left hip pain and fever. On physical examination only pain was noted in the hip joint on extension. Laboratory studies showed leukocytosis ($10,900/\text{mm}^3$) with 76% neutrophils, CRP level of 68 mg/L, and ESR of 127 mm/h. MRI revealed hematoma, abscess in the left psoas muscle and septic arthritis of the left hip joint (Figure 2).

In both the cases; they were previously healthy. They had fallen and hurt their back during a physical exercise. The viral serology including Epstein-Barr virus and Parvovirus, *Brucella*,

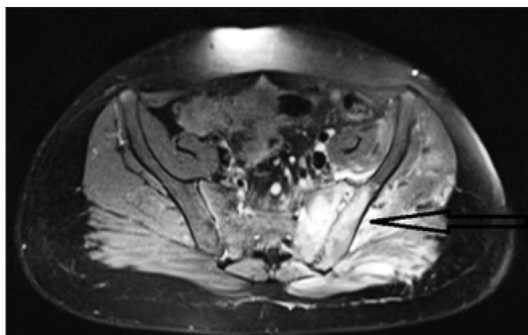


FIGURE 1: Iliopsoas abscess and effusion of the hip joint with septic arthritis of the left hip (arrow).

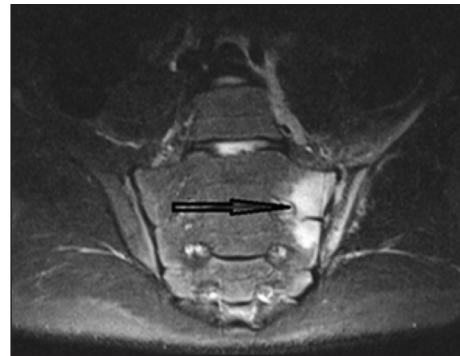


FIGURE 2: Abscess in the left psoas muscle and septic arthritis of the left hip joint (arrow).

Salmonella, leptospirosis and *Mycobacterium tuberculosis* analysis were all negative. Computed tomography (CT)-guided percutaneous abscess drainage was performed for both. In the first case, Gram staining showed Gram-positive cocci in clusters, methicillin sensitive *S. aureus* was isolated from the abscess and blood. In second one, *S. aureus* was isolated only from abscess.

They completed a total of 20 days of intravenous ampicillin and clindamycin treatment, with well clinical improvement and followed by a three-week course of oral amoxicillin. At the time being, they are walking without limping.

DISCUSSION

Pyogenic abscess of psoas muscles may be classified as primary or secondary. Primary abscess, is more common in children and results from hematogenous spread of an infectious process from an occult source in the body. Secondary abscess occurs due to the direct spread of adjacent infectious or inflammatory process into the psoas muscle. Primary abscess is responsible nearly 30% of all cases, occurs most commonly in patients with diabetes mellitus, alcoholism, malnutrition, injection drug use, human immunodeficiency virus infection and other immunosuppressive diseases. Secondary IPA is mostly associated with complications of other conditions, such as urinary tract infections, appendicitis, tuberculosis or inflammatory bowel disease.^{1,4-6}

Trauma to the iliopsoas muscle, resulting hematoma formation is also a significant risk factor

for IPA.⁷ Levin et al. demonstrated pyomyositis development in injured muscle after administration of intravenous *S. aureus*.⁸ However, iliopsoas hematoma following trauma is very uncommon. In most of cases, hematomas result as an extension of hemorrhage from other retroperitoneal structures or as a complication of anticoagulant treatment or bleeding disorders. Post-traumatic cases are usually secondary to sports injury and reported in young patients aged between 12 and 24 years. Our cases are rare in this aspect.

S. aureus is the most common etiologic agent of IPA. Lai et al. reported *S. aureus* as the most frequently isolated organism in their large case series.⁹ *S. aureus* as a member of normal flora of the skin and gastrointestinal tract, spreads often hematogenously. This can lead to an abscess development in the iliopsoas muscles, which have an abundant blood supply. Trauma and hematoma formation facilitates the process.

IPA complicated with septic arthritis of the hip is not very common. Infection of the psoas could extend into the hip joint by the iliopsoas bursa which communicates with the hip in 15% of patients. Also, hematogenous spread from an occult source may result in psoas abscess and septic arthritis.¹⁰ However, the exact source of infection in this combination is not known.

IPA has a high mortality rate if left untreated. The major cause of its poor prognosis is delayed diagnosis and treatment, because of variable clinical

symptoms. MRI and CT are considered to be “gold standard” imaging techniques for demonstrating IPA.¹¹ We preferred MRI because, MRI is superior to CT in displaying soft tissues, and also does not require intravenous contrast material.

The traditional treatment of psoas abscess was surgical drainage and antibiotic therapy. With recent improvements in interventional radiology, percutaneous catheter drainage (PCD) of abscess became a treatment of choice in IPA with favorable results.¹² In our cases, we preferred combination of PCD and antimicrobial therapy. Abscess improved gradually and they were able to walk without pain 2 weeks later.

In conclusion, iliopsoas abscess is extremely rare and difficult to diagnose because of nonspecific symptoms. Physicians should consider iliopsoas abscess in patients presenting with complaints of lower back or hip pain and fever associated with trauma. MRI or CT scan could demonstrate the diagnosis of the psoas abscess. Percutaneous catheter drainage with appropriate antibiotic therapy can be effectively used in management.

Conflict of Interest

Authors declared no conflict of interest or financial support.

Authorship Contributions

Design and Writing of the Case with Literature Review: Deniz Aygün; **Literature Review and Revision of Manuscript:** Şule Bektaş; **Revision of the Manuscript:** Haluk Çokuğraş; **Revision of the Manuscript:** Yıldız Camcıoğlu.

REFERENCES

- Shields D, Robinson P, Crowley TP. Iliopsoas abscess--a review and update on the literature. *Int J Surg* 2012;10(9):466-9.
- Mynter H. Acute pyomyositis. *Buffalo Med Surg J* 1881;21(1):202-10.
- Navarro López V, Ramos JM, Meseguer V, Pérez Arellano JL, Serrano R, García Ordóñez MA, et al. Microbiology and outcome of iliopsoas abscess in 124 patients. *Medicine (Baltimore)* 2009;88(2):120-30.
- Atalar H, Köktener A, Yavuz OY, Uraş İ, Bozer M. [An iliopsoas abscess spreading through an unusual location: case report]. *Türkiye Klinikleri J Med Sci* 2007;27(2):290-3.
- Turunç T, Turunç T, Demiroğlu YZ, Çolakoğlu Ş. [Retrospective evaluation of 15 cases with psoas abscesses]. *Mikrobiyol Bul* 2009;43:121-5.
- Dietrich A, Vaccarezza H, Vaccaro CA. Iliopsoas abscess: presentation, management, and outcomes. *Surg Laparosc Endosc Percutan Tech* 2013;23(1):45-8.
- Whitehouse K, Horne S, Gay D. Psoas abscess secondary to haematoma after a fall causing multiple osteoporotic fractures. *BMJ Case Rep* 2012;2012:2012006846.
- Levin MJ, Gardner P, Waldvogel FA. An unusual infection due to staphylococcus aureus. *N Engl J Med* 1971;284(4):196-8.
- Lai YC, Lin PC, Wang WS, Lai JI. An update on psoas muscle abscess: an 8-year experience and review of literature. *Int J Gerontol* 2011;5(2):75-9.
- Su CN, Hsieh DS, Sun GH, Yu DS, Fong CJ. Primary retroperitoneal abscess complicated with septic arthritis of the hip. *J Chin Med Assoc* 2006;69(1):51-3.
- Takada T, Terada K, Kajiwara H, Ohira Y. Limitations of using imaging diagnosis for psoas abscess in its early stage. *Intern Med* 2015;54(20):2589-93.
- Dinc H, Ahmetoğlu A, Baykal S, Sari A, Sayil O, Gümele HR. Image guided percutaneous of tuberculous iliopsoas and spondylodiskitic abscesses: midterm results. *Radiology* 2002;225(2):353-8.