

Tumor to Tumor Metastasis: Lobular Carcinoma of the Breast Metastatic to Renal Cell Carcinoma and Lipoleiomyoma: Case Report

Tümörün Tümöre Metastazı: Renal Hücreli Karsinoma ve Lipoleiomyoma Metastaz Yapan Memenin Lobüler Karsinomu

Ayşegül SARI, MD,^a
Murat ERMETE, MD,^a
Canan SADULLAHOĞLU, MD,^a
Aylin ÇALLI, MD,^a
Uğur BALCI, MD,^b
Mahmoud MUSTAFA, MD^b

Departments of

^aPathology,

^b1st Urology Department,
İzmir Atatürk Training and
Research Hospital, İzmir

Geliş Tarihi/Received: 22.01.2010
Kabul Tarihi/Accepted: 26.06.2011

Yazışma Adresi/Correspondence:
Canan SADULLAHOĞLU, MD
İzmir Atatürk Training and
Research Hospital,
Departments of Pathology, İzmir,
TÜRKİYE/TURKEY
canan-rana@hotmail.com

ABSTRACT Tumor to tumor metastasis is a well-known but a rare event. Lung carcinoma, being as a donor and renal cell carcinoma (RCC) serving as a recipient tumor are the most commonly observed tumor to tumor metastasis. Renal cell carcinoma serving as recipient of metastatic breast carcinoma is very rare, and to our knowledge only four cases including three autopsy cases have been reported to date. Herein, we report a case of a 69-year-old woman with invasive lobular carcinoma of the breast that metastasized to RCC and internal genital organs including right ovary, uterus and as well as to a benign tumor, lipoleiomyoma.

Key Words: Carcinoma, lobular; neoplasm metastasis; carcinoma, renal cell; breast; uterus

ÖZET Tümörden tümöre metastaz oldukça iyi bilinmekle birlikte nadir bir durumdur. Tümörden tümöre metastaz olgularında akciğer karsinomu en sık verici tümör olarak rol alan, renal hücreli karsinom (RHK) ise en sık metastaz kabul eden tümör olarak izlenmektedir. RHK'un meme karsinom metastazının alıcısı olması çok nadir olup bilgilerimize göre günümüze kadar literatürde rapor edilen üçü otopsi olgusu olmak üzere sadece dört olgu bildirilmiştir. Bu makalede, 69 yaşındaki kadın hastada, RHK yanısıra sağ over ve uterus da dahil internal genital organlara ve aynı zamanda benign bir tümör olan lipoleiomyoma metastaz yapmış memenin invaziv lobüler karsinom olgusunu literatürler eşliğinde sunduk.

Anahtar Kelimeler: Karsinom, lobüler; tümör metastazı; karsinom, böbrek hücreli; meme; uterus

Türkiye Klinikleri J Med Sci 2011;31(6):1602-6

Metastasis of one cancer to another one is an unusual event. Renal cell carcinoma (RCC) is the most common malignant recipient tumor where lung carcinoma is the most frequent donor site. Renal cell carcinoma serving as recipient of metastatic breast carcinoma is very rare with only four cases being reported to date.¹ On the other hand, metastasis to the uterus is not also common and comprises less than 10% of all cases of metastasis to female genital tract.² Herein, we report a case of an invasive lobular carcinoma (ILC) of the breast metastatic to RCC, female genital organs and to a benign tumor, lipoleiomyoma.

CASE REPORT

A 69-year-old woman presented with a 3.5 cm mass in her left breast to another medical center. Biopsy of the mass was performed and she then un-

derwent left radical mastectomy with the diagnosis of invasive lobular carcinoma (ILC). Six out of nine axillary lymph nodes were metastatic. We confirmed the histopathological diagnosis of ILC both in biopsy and mastectomy specimens in our department. ILC was of classical type and had moderate nuclear pleomorphism.

Ultrasonography obtained one month after the operation showed a mass in her right kidney and she was referred to our hospital. Computed tomography scan (CT) of the abdomen revealed a 9.5 cm mass in the right kidney and a 3 cm mass in the right ovary.

In order to differentiate between breast carcinoma metastasis and a primary renal tumor, a tru-cut biopsy of the kidney was performed and histopathological diagnosis of renal cell carcinoma was made. Subsequently right radical nephrectomy with total abdominal hysterectomy was performed. Macroscopic examination of the right nephrectomy revealed a 9.5 cm yellowish tumor mass with smooth borders. The uterus measured 14 cm longitudinally, 10 cm transversely and 8 cm anteroposteriorly. On cut sections, the endometrial thickness was 1-2 mm, and on serial sections of myometrium, a well circumscribed, yellow colored 9 x 6 cm nodule was seen. The right and left ovaries measured 3 x 1.5 x 1 cm and 4 x 2 x 1.5 cm, respectively. Cut surface of both ovaries revealed no specific findings.

On microscopic examination, the renal tumor showed a solid growth pattern consisting of cells with abundant clear cytoplasm and small hyperchromatic nuclei, which was consistent with clear cell RCC with a low nuclear grade. The tumor was confined to the kidney without any involvement of perirenal fat tissue. Scattered through the RCC, aggregates of discohesive tumor cells with more vesicular nuclei and scanty eosinophilic cytoplasm were noticeable (Figures 1, 2). These tumor cells which represented the metastatic carcinoma cells stained positive for cytokeratin 7, e-cadherin and estrogen while RCC cells were negative for these markers (Figures 3, 4a). High molecular weight cytokeratin was positive only in metastatic carcinoma cells while vimentin was positive only in RCC cells (Figure 4b). Epithelial membrane antigen was positive, whereas GCDFP15, and progesterone were negative, in both

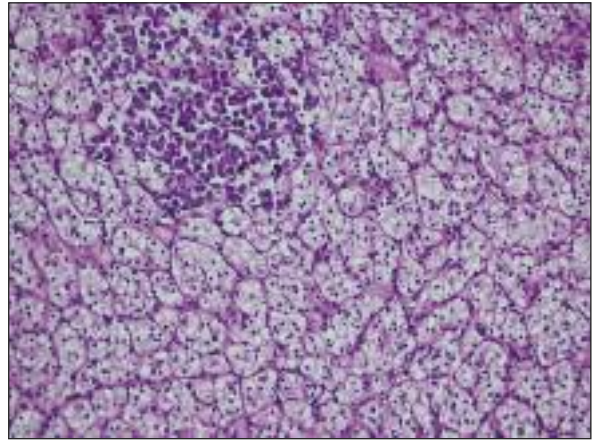


FIGURE 1: Renal cell carcinoma with metastatic foci of breast cancer, (Haematoxylen-Eosin x100).

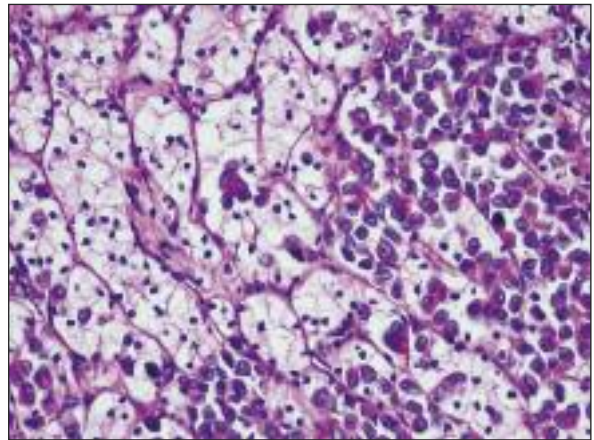


FIGURE 2: Metastatic discohesive cells of invasive lobular carcinoma of the breast with vesicular nuclei and scanty eosinophilic cytoplasm are scattered among renal cell carcinoma, (Hemotoxylen-Eosin, x400).

tumor cells. With the help of immunohistochemical findings, the diagnosis of “invasive lobular carcinoma metastatic to renal cell carcinoma” was made. Histological examination of the total hysterectomy specimen disclosed an atrophic endometrium and ILC infiltration in the myometrium of the uterine corpus, isthmus, cervix and right ovary. The nodule in the myometrium was composed of smooth muscle admixed with mature adipose tissue that is compatible with the diagnosis of lipoleiomyoma. Lipoleiomyoma was also infiltrated by ILC (Figure 5). No other specific findings were detected in hysterectomy specimen including ovaries.

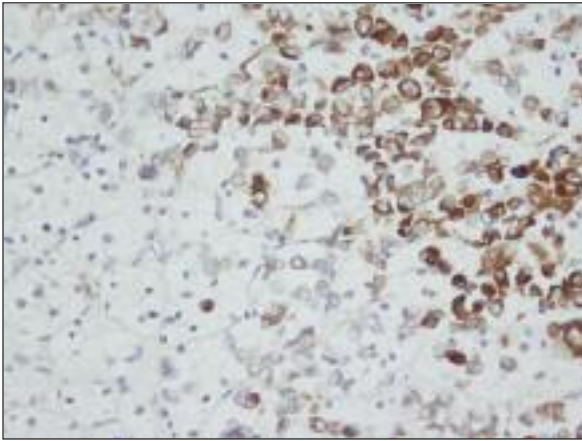


FIGURE 3a: Cytokeratin 7 positivity in metastatic breast carcinoma, (x400).

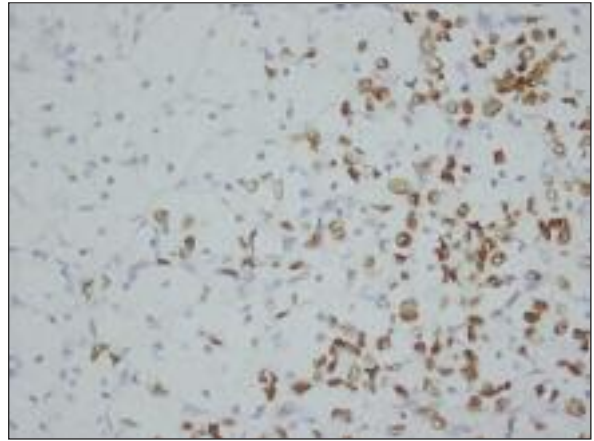


FIGURE 3b: Estrogen positivity in nuclei of metastatic breast carcinoma, (x400).

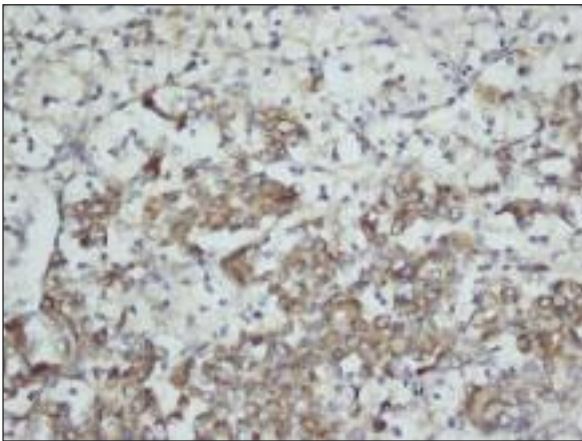


FIGURE 4a: Cytoplasmic E-cadherin positivity in metastatic breast carcinoma, (x400).

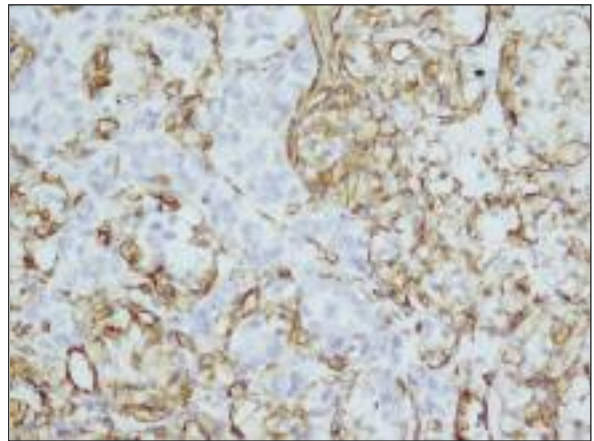


FIGURE 4b: Vimentin is positive in renal cell carcinoma, metastatic tumor cells are negative, (x400).

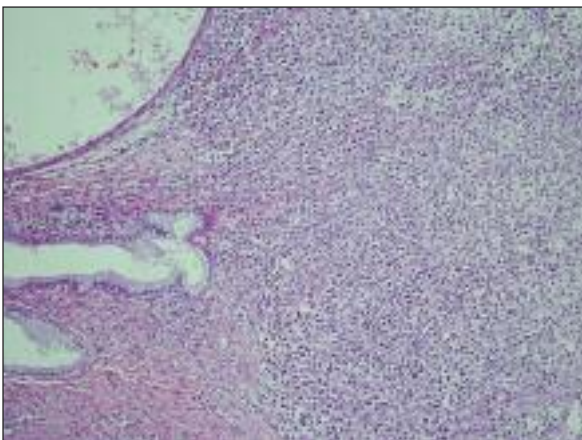


FIGURE 5a: Breast carcinoma metastatic to the cervix, (Hematoxylen-Eosin, x40).

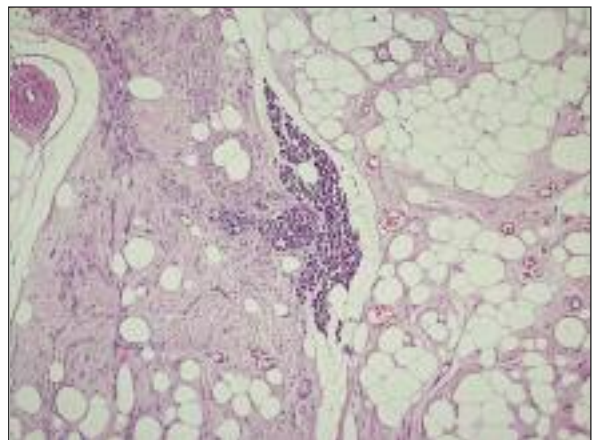


FIGURE 5b: Invasive lobular carcinoma of the breast metastatic to the uterine lipoleiomyoma, (Hematoxylen-Eosin, x 40).

The patient died two weeks after her discharge from the hospital.

DISCUSSION

The coexistence of two primary malignant neoplasms in the same host is not an unusual clinical entity, whereas tumor to tumor metastasis is a rare phenomenon. Since Campell et al. reported the first case of tumor to tumor metastasis in 1968, approximately 150 cases have been reported.^{3,4} Lung carcinoma followed by breast, prostate, and thyroid carcinomas serve as the most frequent donor sites.⁴ Renal cell carcinoma followed by sarcoma is the most common malignant recipient tumors where meningioma is the most common benign recipient tumor of metastasis. Prostate, breast, colon, bladder, and non-Hodgkin lymphomas are the most common malignancies that are associated with RCC.¹ According to Sella and Ro,⁵ when RCC coexists with other malignancies, the incidence of tumor to tumor metastasis is 15%. The reason for RCC being the most frequent recipient is attributed to its rich vascular supply and its glycogen and lipid-rich cells which create a suitable environment for acceptance and growth of donor tumor cells.^{1,4}

As metastases from breast cancer are concerned, intracranial meningiomas are the most frequently reported recipient tumors.⁶ There have been only four reported cases of breast carcinoma metastatic to RCC, three of which being autopsy cases.¹ Although this occurrence is very rare, histopathologic diagnosis of invasive ductal carcinoma metastatic to conventional RCC might not cause differential diagnostic difficulty due to the overt different morphology of the two tumors. In our case, metastatic lobular carcinoma of the breast was scattered all through the renal cell carcinoma, resembling the recipient tumor with more eosinophilic cytoplasm and a higher nuclear grade. Immunohistochemistry helps in diagnosis. In our case, CK 7 was positive in only ILC cells. GCDFP15, a glycoprotein identified in the cyst fluid of cystic breast, which is considered as a marker of apocrine differentiation, is also used as an immunohistochemical marker of breast cancer. Positive GCDFP15 staining was found only in %23 of carcinomas wit-

hout apocrine features.⁷ In our case, GCDFP-15 was negative in both RCC and breast carcinoma. E-cadherin, an epithelium specific molecule involved in cell to cell adhesion is markedly reduced or absent in majority of ILC when compared to IDC.⁷ In our case, E-cadherin showed cytoplasmic positivity without any membranous staining in tumoral cells of ILC where tumoral cells of RCC were all negative. De Leeuw et al.⁸ reported that 84% of ILC had complete negative membranous staining and 56% of these cases had cytoplasmic staining for E-cadherin. Kowalski et al.⁹ also reported that both metastatic foci and primary ILC had accumulation of E-cadherin in the cytoplasm of the neoplastic cells without any membranous staining. They concluded that ILC had different pattern of E-cadherin expression both at the primary tumor and metastatic sites which in turn suggests a different role for this marker in ILC.

Metastasis to female genital tract from extragenital sites are not common although the ovaries are most commonly affected.¹⁰ Breast and gastrointestinal tumors are the most common tumors which metastasize to female genital tract.¹¹ Among breast tumors, lobular carcinoma is the most common type which metastasizes to uterus. Uterine leiomyoma very rarely harbour metastatic tumor and to date 14 surgical and eight autopsy cases of leiomyoma with metastatic breast cancer have been documented.¹⁰ However among these cases, there is only one lipoleiomyoma harbouring breast cancer metastasis which is in the form of an invasive ductal carcinoma.¹²

In conclusion, our case was a very rare and an unique case involving the following conditions; i) ILC metastasis to RCC, ii) the first ILC metastasis to lipoleiomyoma, iii) ILC metastasis to both a malignant and a benign tumor, and iv) ILC metastasis to female genital organs. The possibility of a tumor to tumor metastasis should be considered when a different morphology is encountered in a tumor. In addition, a detailed microscopic examination to detect a possible focus of metastatic tumor in an ordinary RCC should not be neglected since the most common tumor to tumor metastasis recipient tumor is RCC.

REFERENCES

1. Möller MG, Gribbin T, Ebrom S, Padula G, Fitzgerald TL. Breast cancer metastatic to renal cell carcinoma. *Surgery* 2006;139(4):577-9.
2. Scopa CD, Aletra C, Lifschitz-Mercer B, Czernobilsky B. Metastases of breast carcinoma to the uterus. Report of two cases, one harboring a primary endometrioid carcinoma, with review of the literature. *Gynecol Oncol* 2005;96(2):543-7.
3. Campbell LV Jr, Gilbert E, Chamberlain CR Jr, Watne AL. Metastases of cancer to cancer. *Cancer* 1968;22(3):635-43.
4. Petraki C, Vaslamatzis M, Argyrakos T, Petraki K, Strataki M, Alexopoulos C, et al. Tumor to tumor metastasis: report of two cases and review of the literature. *Int J Surg Pathol* 2003;11(2):127-35.
5. Sella A, Ro JY. Renal cell cancer: best recipient of tumor-to-tumor metastasis. *Urology* 1987;30(1):35-8.
6. Watanabe T, Fujisawa H, Hasegawa M, Arakawa Y, Yamashita J, Ueda F, et al. Metastasis of breast cancer to intracranial meningioma: case report. *Am J Clin Oncol* 2002;25(4):414-7.
7. Rosen PP. Apocrine carcinoma. In: Pine JW, McGough J, eds. *Rosen's Breast Pathology*. 3rd ed. Philadelphia: Lippincott Williams&Walkins; 2009. p.536-50.
8. De Leeuw WJ, Bex G, Vos CB, Peterse JL, Van de Vijver MJ, Litvinov S, et al. Simultaneous loss of E-cadherin and catenins in invasive lobular breast cancer and lobular carcinoma in situ. *J Pathol* 1997;183(4):404-11.
9. Kowalski PJ, Rubin MA, Kleer CG. E-cadherin expression in primary carcinomas of the breast and its distant metastases. *Breast Cancer Res* 2003;5(6):R217-22.
10. Kondo NI, Yoshida S, Kajiyama H, Nagasaka T, Uematsu T. Metastasis of breast cancer to a uterine leiomyoma. *Breast Cancer* 2009;16(2):157-61.
11. Perišić D, Jancić S, Kalinović D, Cekerevac M. Metastasis of lobular breast carcinoma to the cervix. *J Obstet Gynaecol Res* 2007;33(4):578-80.
12. Uner A, Tiras MB, Kiliç D, Dursun A, Dilek U. Uterine lipoleiomyoma containing metastatic breast carcinoma: a case with two unusual pathologies. *Eur J Obstet Gynecol Reprod Biol* 2003;106(1):76-8.