

Eczematous Skin Lesions: Delayed-Type Hypersensitivity Reaction to Subcutaneous Enoxaparin: Case Report

Ekzematöz Cilt Lezyonları: Subkutan Enoksaparine Bağlı Gecikmiş Tip Hipersensitivite Reaksiyonu

Kurtuluş AKSU,^a
Emel KURT,^a
Metin KEREN,^a
Evrin ÇİFTÇİ^b

Departments of
^aPulmonology,
Allergic Diseases Centre,
^bPathology,
Eskişehir Osmangazi University
Faculty of Medicine, Eskişehir

Geliş Tarihi/Received: 07.07.2010
Kabul Tarihi/Accepted: 05.01.2011

Yazışma Adresi/Correspondence:
Kurtuluş AKSU
Eskişehir Osmangazi University
Faculty of Medicine,
Department of Pulmonology,
Allergic Diseases Centre, Eskişehir,
TÜRKİYE/TURKEY
kurtulusaksu@yahoo.com

ABSTRACT In the last two decades low molecular weight heparins have been increasingly used for the prophylaxis and treatment of thromboembolic disorders. Unfortunately, like unfractionated heparins adverse effects may limit the continuation of therapy. Heparin-induced skin lesions are commonly encountered of which the two most commonly reported causes are immune-mediated thrombocytopenia and delayed-type hypersensitivity reactions. We present a case with pulmonary embolism who had eczematous skin lesions on the 10th day of subcutaneous enoxaparin treatment due to delayed-type hypersensitivity reaction together with the allergologic work up performed for the differential diagnosis.

Key Words: Heparin, low-molecular-weight; drug hypersensitivity; skin diseases, eczematous

ÖZET Tromboembolik bozuklukların profilaksi ve tedavisinde son iki dekaddır düşük moleküler ağırlıklı heparinlerin kullanımı giderek artmaktadır. Ancak anfraksiyone heparinlerde olduğu gibi yan etkiler tedavinin devamını kısıtlayabilmektedir. İmmün aracılı trombositopeni ve gecikmiş tip hipersensitivite reaksiyonu başta olmak üzere heparine bağlı cilt lezyonları ile sıkça karşılaşılır. Pulmoner emboli tanısı konularak başlanan subkutan enoksaparin tedavisinin onuncu gününde gecikmiş tip hipersensitivite reaksiyonuna bağlı ekzematöz cilt lezyonları gelişen olgu ayrıntı için izlenen allergolojik çalışma ile birlikte sunulmaktadır.

Anahtar Kelimeler: Heparin, düşük moleküler ağırlıklı; ilaç aşırı duyarlılığı; deri hastalıkları, ekzematöz

Türkiye Klinikleri J Cardiovasc Sci 2012;24(3):318-21

Low molecular weight heparins (LMWH) are currently the first choice therapy in the prophylaxis and treatment of venous thromboembolism. Unfortunately, like unfractionated heparins (UFH) adverse effects may limit the continuation of therapy.¹ Heparin-induced skin lesions are commonly encountered of which the two most commonly reported causes are immune-mediated heparin-induced thrombocytopenia (HIT) and delayed-type hypersensitivity (DTH) reactions.² We present a case of DTH reaction to subcutaneous (SC) enoxaparin and the allergological work up performed for the differential diagnosis.

CASE REPORT

Following stomach cancer surgery, a 58-year-old man received enoxaparin 60 mg, twice daily, due to subsegmental pulmonary embolism. Itchy erythema-

tous and eczematous plaques appeared 10 days after initiation of subcutaneously applied enoxaparin. The lesions were located on both arms and on abdominal wall at the sites of injection (Figure 1). Platelet count was within normal limits and it remained so in the following days. He had no history of treatment with UFH or LMWH before. LMWH therapy was halted since we suspected hypersensitivity reaction to enoxaparin. Prick test with 1/1 and intradermal test with 1/10 enoxaparin were negative. SC challenge was performed with therapeutic dosage of enoxaparin and was positive. Informed consent was obtained prior to the tests. Punch biopsy was performed from the skin lesions of left arm and the histological study revealed some vacuolization of the dermal-epidermal junction with few apoptotic epidermal cells and perivascular infiltrate of lymphocytes and eosinophils (Figure 2). These findings together with no histological evidence of occlusion in dermal vessels was consistent with drug eruption. Intravenous (IV) challenge test was planned to determine whether IV heparin treatment is possible, though test was not performed because of unwillingness of the patient. Anticoagulation therapy was continued with oral warfarin sodium since extensive cross-reactivity is well-known among different forms of LMWHs and so as between LMWHs and UFH preparations.

DISCUSSION

Heparin-induced skin lesions are being increasingly reported, although exact incidence is unknown.

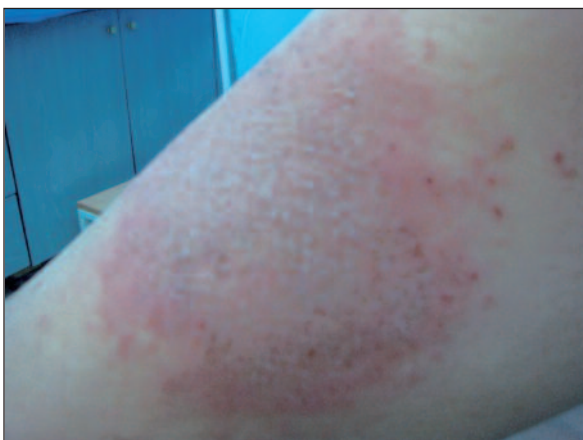

FIGURE 1: Itchy erythematous and eczematous plaques on the left upper arm. (See for colored form <http://cardiovascular.turkiyeklinikleri.com/>)

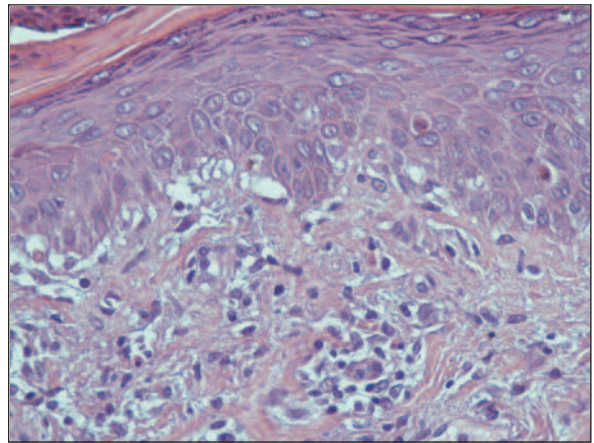


FIGURE 2: Vacuolization of the dermal-epidermal junction with few apoptotic epidermal cells and perivascular infiltrate of lymphocytes and eosinophils (hematoxylin-eosin stain x 40).

(See for colored form <http://cardiovascular.turkiyeklinikleri.com/>)

At least 5 mechanisms are responsible for skin lesions; DTH responses, immune-mediated thrombocytopenia, type I allergic reactions, skin necrosis and pustulosis. DTH reactions with LMWHs is reported as 7.5% in a study.²

DTH to subcutaneously applied heparins present with itchy erythematous or eczematous plaques around injection sites, characteristically during ongoing therapy is at 7 to 10th days. In case of prior sensitization and re-exposure, however, skin lesions appear within 1 to 3 days. In early erythematous lesions, histopathologic examination reveals a dense mononuclear infiltrate of predominantly CD4+ lymphocytes with scattered eosinophils. Eczematous lesions additionally show epidermal spongiosis. These findings are consistent with a DTH reaction of the skin.³ In the present case punch biopsy specimens from the lesions revealed DTH reaction.

DTH reaction of the skin with use of heparin should be distinguished from heparin-induced skin necrosis. Heparin-induced skin necrosis is the cutaneous manifestation of HIT. Painful and mildly infiltrated erythema is followed by a central bullous and necrotic area surrounded by a hemorrhagic rim. Lesions are not always restricted to heparin application sites but may also occur at distant sites, typically at locations with increased subcutaneous fat tissue. Pathologically thrombosis of skin vessels

without signs of vasculitis is detected in skin biopsy specimens. Other than HIT the differential diagnosis of erythematous and eczematous plaques after subcutaneous heparin administration includes hematomas, local infections, and eczema attributable to skin disinfectants.³

In the present case, both the macroscopical appearance of the lesions and their location limited to injection sites was typical for DTH reaction to enoxaparin. The patient had no history of prior heparin treatment, so no prior sensitization was possible and accordingly the lesions appeared after a week of treatment as expected. Platelet count was controlled in order to exclude possibility of HIT and it was within normal limits. Heparin therapy was halted immediately and allergologic algorithm for suspected cases of DTH was planned. First prick and intradermal tests were performed and were both negative, so we applied SC challenge test as next step. SC challenge test is considered as gold standard for the diagnosis of DTH.³⁻⁵

Heparins are anionic polysaccharides extracted from porcine intestinal mucosa; during the processing process, they are fractionated and depolymerized. Therefore, heparin preparations are not pure substances but a composite of heterogeneous molecules varying in size and chemical structure. Potential antigenic determinants of the heparin molecule have not yet been determined, however. Typical for DTH against subcutaneously administered heparins is the extensive cross-reactivity among different heparins is the rule, including all UFH and LMWH preparations of all manufacturers.³

In case of DTH to subcutaneously injected heparin, IV application of this drug theoretically implies the risk for a generalized eczematous reaction.

Data in the literature show that patients with DTH to heparins tolerate IV heparin application, however.^{6,7} In the present case in order to seek for IV heparin tolerance, IV challenge test was planned but because of unwillingness of the patient, test was not performed.

Typical for DTH to subcutaneously administered heparins there is extensive cross-reactivity among different heparins, including all UFH and LMWH preparations. Heparinoids initially seemed as an alternative but they may cross-react with heparin in case of DTH. Although danaparoid indeed shows low cross-reactivity with heparin in terms of heparin-induced antibody binding, cross-reactivity between heparinoids and heparins is quite common.^{3,8} Fondaparinux, which is the best alternative drug in HIT cases, is well-tolerated in patients with delayed-type reactions to heparins and heparinoids. Occasional cases with type IV allergy to fondaparinux on intradermal testing and also after subcutaneous challenge were reported. Nevertheless, fondaparinux still seems to be a valuable alternative in most cases of heparin and hirudin hypersensitivity.⁸ Because of their completely different chemical structure, hirudins are reported as the only safe alternative for subcutaneously applied anticoagulation by some authors.³ In the present case oral warfarin sodium was administered because neither fondaparinux nor hirudins are available in the market in our country.

As a result of increasing use of LMWHs related skin lesions are more frequently encountered. DTH reactions should be considered when eczematous skin lesions occur at injection site. An allergological evaluation may help to choose an alternative drug, especially if prolonged treatment is necessary.

REFERENCES

1. Alban S. From heparins to factor Xa inhibitors and beyond. *Eur J Clin Invest* 2005;35 (Suppl 1):12-20.
2. Schindewolf M, Schwaner S, Wolter M, Kroll H, Recke A, Kaufmann R, et al. Incidence and causes of heparin-induced skin lesions. *CMAJ* 2009;181(8):477-81.
3. Trautmann A, Seitz CS. Heparin allergy: delayed-type non-IgE-mediated allergic hypersensitivity to subcutaneous heparin injection. *Immunol Allergy Clin North Am* 2009;29(3): 469-80.

4. Wütschert R, Piletta P, Bounameaux H. Adverse skin reactions to low molecular weight heparins: frequency, management and prevention. *Drug Saf* 1999;20(6):515-25.
5. Palacios Colom L, Alcántara Villar M, Luis Anguita Carazo J, Ruiz Villaverde R, Quiralte Enríquez J. Delayed-type hypersensitivity to heparins: different patterns of cross-reactivity. *Contact Dermatitis* 2008;59(6):375-7.
6. Gaigl Z, Pfeuffer P, Raith P, Bröcker EB, Trautmann A. Tolerance to intravenous heparin in patients with delayed-type hypersensitivity to heparins: a prospective study. *Br J Haematol* 2005;128(3):389-92.
7. Irion R, Gall H, Peter RU. Delayed-type hypersensitivity to heparin with tolerance of its intravenous administration. *Contact Dermatitis* 2000;43(4):249-50.
8. Jappe U, Juschka U, Kuner N, Hausen BM, Krohn K. Fondaparinux: a suitable alternative in cases of delayed-type allergy to heparins and semisynthetic heparinoids? A study of 7 cases. *Contact Dermatitis* 2004;51(2):67-72.