

Secondary Intraocular Lens Implantation in Spontaneous Crystalline Lens Absorption Following Penetrating Eye Injury: Case Report

Penetran Göz Yaralanması Sonrası Gelişen Spontan Kristalin Lens Absorbsiyonunda Sekonder Göziçi Lens İmplantasyonu

Irmak KARACA,^a
Melis PALAMAR^a

^aDepartment of Ophthalmology,
Ege University Faculty of Medicine,
İzmir

Geliş Tarihi/Received: 30.06.2015
Kabul Tarihi/Accepted: 08.09.2015

Yazışma Adresi/Correspondence:
Melis PALAMAR
Ege University Faculty of Medicine,
Department of Ophthalmology, İzmir,
TÜRKİYE/TURKEY
melispalamar@hotmail.com

This case report was presented at
48th National Congress of the
Turkish Ophthalmological Society,
5-9 November 2014, Antalya, Turkey.

ABSTRACT Trauma or inflammation may be the reason for spontaneous absorption of crystalline lens, especially in young people. The length of time for spontaneous absorption to take place varies. The underlying mechanism for spontaneous lens absorption is not well understood. However, in traumatic cases the injury to the lens capsule, is considered to be responsible for spontaneous lens absorption. Close follow-up is important to timely recognize uveitis or glaucomatous reactions in regard to process. Herein we report secondary intraocular lens implantation in a case with spontaneous absorption of the unencapsulated crystalline lens following penetrating eye injury.

Keywords: Cataract; lens, crystalline; wounds and injuries; eye injuries, penetrating

ÖZET Özellikle gençlerde travma veya inflamasyon kristalin lenste spontan absorbsiyona neden olabilir. Spontan absorbsiyon gelişmesi için geçen süre olgudan olguya değişiklik gösterir. Spontan lens absorbsiyonuna neden olan mekanizma tam olarak anlaşılamamıştır. Fakat travmatik vakalarda lens kapsülünde hasar oluşmasının sorumlu olabileceği düşünülmektedir. Bu olgularda gelişebilecek olan üveitik veya glokomatöz reaksiyonları erken tespit etmek süreç açısından önemlidir. Bu olgu raporunda penetran göz yaralanması sonrası ankapsüle kristalin lensli bir olguda gelişen spontan absorbsiyon sonrası sekonder göziçi lens implantasyonunu sunduk.

Anahtar Kelimeler: Katarakt; lens, kristalin; yaralar ve yaralanmalar; göz yaralanmaları, delici

Ocular trauma, especially penetrating eye injury, is one of the most common reasons for unilateral vision loss. Penetrating eye injuries are mostly seen during childhood or adolescence period, and they compose an important public health problem; since they are preventable and affect the quality of life in the long term.¹ In most traumatic cases, cataractous changes in the crystalline lens are observed. However, spontaneous crystalline lens absorption which was first reported by Warnatz in 1835 is very rare.² Its prevalence was determined as one case in a year by Marlow et al.² Besides trauma, spontaneous crystalline lens absorption is reported to be seen in patients with congenital cataract due to maternal rubella, Down syndrome and phacolytic glaucoma.³⁻⁵ Rathinam et al. compiled spontaneous cataract absorption in patients with leptospiral

uveitis in which the prevalence was reported to be 18.5%.⁶

Herein, we report a case with spontaneous crystalline lens absorption after penetrating eye injury who had undergone secondary intraocular lens (IOL) implantation and we aim to draw attention to this rare situation.

CASE REPORT

An otherwise healthy 26-year-old male presented with penetrating injury to the right eye. On initial examination, visual acuity was hand movements in the affected eye. Slit-lamp biomicroscopic evaluation was remarkable for a horizontal, full-thickness corneal laceration, starting from the temporal limbus, extending to the nasal sclera and involving the central cornea causing corneal edema. The anterior chamber was shallow and the crystalline lens capsule was ruptured. Posterior segment could not be visualised due to the cataractous lens, however ultrasonographic evaluation did not reveal any abnormalities in the globe. Left eye was within normal limits.

The right eye was primarily repaired under general anesthesia. The lens capsule rupture was obviously seen. However, as the cornea was not clear enough the cataract surgery was postponed to another surgical session. Postoperatively, topical moxifloxacin (Vigamox, Alcon, US) and dexamethasone (Maxidex, Alcon, US) 8 times daily

and cyclopentolate hydrochloride (Sikloplejin, Abdi Ibrahim, Turkey) 3 times daily were administered for a week. Topical moxifloxacin was tapered to 4 times daily after a week and stopped by 2 months when the sutures were removed. Topical cyclopentolate hydrochloride was tapered to once a day and topical dexamethasone was tapered to 6 times daily after a week. Until the corneal suture removal the patient was examined in every 2 weeks. During this time period the cornea got clear and the anterior chamber was stabilized with a less swollen cataractous crystalline lens. At the 3rd month of follow-up in which the cataract surgery was planned, the patient was recognized with aphakia, suggesting that the crystalline lens was spontaneously absorbed (Figures 1A, 1B). Following aphakic refractive correction with spectacles, best corrected visual acuity improved to 0.5 on Snellen chart. Fundoscopic examination under full mydriasis was normal except accompanying posterior vitreous detachment. During follow-up, intraocular pressure was within normal limits with no intraocular inflammation. The remaining peripheral intercapsular lenticular material was aspirated and secondary in the bag IOL (AMO, Tecnis Acrylic IOL, USA) implantation was performed under topical anesthesia through a 3.2 mm incision. One month after secondary IOL implantation best corrected visual acuity increased to 0.9 (-3.50X165 D) on Snellen chart (Figure 2).

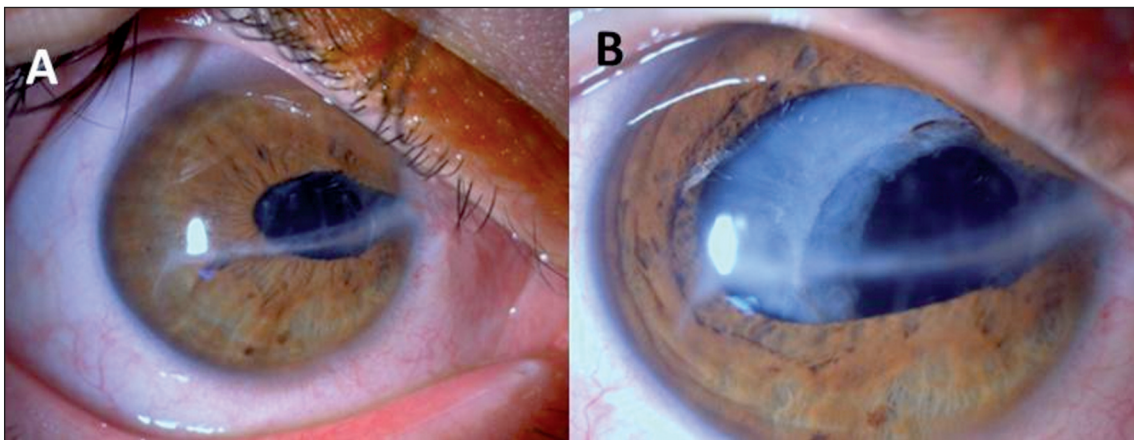


FIGURE 1: Spontaneously absorbed crystalline lens, aphakic appearance. A. Anterior segment picture before (A) and after pupillary dilation (B).

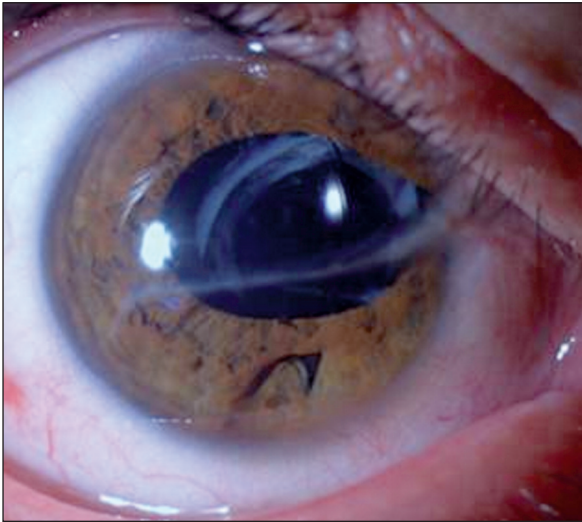


FIGURE 2: The anterior segment appearance following secondary intraocular lens implantation.

DISCUSSION

Spontaneous absorption of crystalline lens is very rare.² Our aim to report this case is to remind this very rare entity even to take place in adult patients. The length of time for spontaneous absorption to take place in the cases reported varies from 2 months to thirteen years.² Herein the crystalline lens absorption occurred in the 3rd month of the injury.

The underlying mechanism for spontaneous lens absorption is not well understood. However, in traumatic cases the injury to the lens capsule, might be responsible for spontaneous lens absorption.² It is also suggested that even in nontraumatic cases there might be unrecognizable capsule tears, as playing a role.² Besides capsular tears, osmotic forces due to chemical changes on either side of the

lens capsule have also been documented as underlying mechanisms.²

The diagnosis of spontaneous crystalline lens absorption must include a careful history and examination including fundoscopy with full mydriasis - in order to detect any possible dislocation or subluxation of the lens. If there is no additional problem secondary IOL implantation in these spontaneous absorbed crystalline lens cases might ease visual recovery. It is likely that the extent of associated anatomic disorganization may be the determining factor in achieving successful in the bag IOL implantation. In the presence of uveitic and glaucomatous reactions the IOL implantation should be delayed until these problems are accomplished with appropriate treatment.

In the bag implantation of an IOL and good visual outcome is possible with modern microsurgical instruments and appropriate surgical technique in spontaneously absorbed crystalline lens cases. However, further studies are needed to establish the etiopathogenesis and prognosis in these patients.

Conflict of Interest

Authors declared no conflict of interest or financial support.

Authorship Contributions

Surgical and Medical Practices: Irmak Karaca, Melis Palamar, **Concept:** Irmak Karaca, Melis Palamar, **Design:** Irmak Karaca, Melis Palamar, **Data Collection or Processing:** Irmak Karaca, Melis Palamar, **Analysis or Interpretation:** Irmak Karaca, Melis Palamar, **Literature Search:** Irmak Karaca, Melis Palamar, **Writing:** Irmak Karaca, Melis Palamar.

REFERENCES

1. Abbott J, Shah P. The epidemiology and etiology of pediatric ocular trauma. *Surv Ophthalmol* 2013;58(5):476-85.
2. Marlow SB. Spontaneous absorption of cataract. *Trans Am Ophthalmol Soc* 1952;50:283-93.
3. Boger WP 3rd, Petersen RA, Robb RM. Spontaneous absorption of the lens in the congenital rubella syndrome. *Arch Ophthalmol* 1981;99(3):433-4.
4. Mohan M, Bartholomew RS. Spontaneous absorption of a cataractous lens. *Acta Ophthalmol Scand* 1999;77(4):476-7.
5. Blaise P, Duchesne B, Guillaume S, Galand A. Spontaneous recovery in phacolytic glaucoma. *J Cataract Refract Surg* 2005;31(9):1829-30.
6. Rathinam SR, Namperumalsamy P, Cunningham ET Jr. Spontaneous cataract absorption in patients with leptospiral uveitis. *Br J Ophthalmol* 2000;84(10):1135-41.