








Malignant Mixed Müllerian Tumor of the Fallopian Tube: Rare Case Report

-  Ghanim KHATIB,^a
 Cenk SOYSAL,^a
 Ümran KÜÇÜKGÖZ GÜLEÇ,^a
 Ahmet Barış GÜZEL,^a
 Mehmet Ali VARDAR,^a
 Emine BAĞIR,^b
 Semra PAYDAŞ^b

Departments of

^aObstetrics and Gynecology,

^bPathology,

Çukurova University Faculty of Medicine,
Adana

Received: 26.05.2016

Received in revised form: 24.07.2016

Accepted: 24.08.2016

Available online: 04.06.2018

Correspondence:

Ghanim KHATIB

Çukurova University Faculty of Medicine,
Department of Obstetrics and Gynecology,
Adana, TURKEY
ghanim.khatib@gmail.com

ABSTRACT Primary malignant mixed Müllerian tumors of the fallopian tube are quite infrequent malignancies. Herein we present a case of malignant mixed Müllerian tumor of the right fallopian tube. A 55-years old postmenopausal, para 2, Turkish woman was referred to our clinic with pelvic pain. Patient had a history of breast cancer and she was operated 7 years ago. Examinations revealed a solid mass in size of 5 cm on the right adnexa. Upon exploration, right tube was observed to be swollen and it was in the form of a completely infiltrated mass. Full staging surgery was performed and pathology result was reported as stage 1c carcinosarcoma of the tube. In conclusion, data about the optimal treatment strategies for carcinosarcomas of the fallopian tube are limited. However, maximal cytoreduction followed by platinum based chemotherapy seems to be an appropriate option.

Keywords: Mixed tumor, malignant; carcinosarcoma; fallopian tubes

Fallopian tube cancers are the least common among the gynecological malignancies.¹ Carcinosarcoma or malignant mixed Müllerian tumor (MMMT) is an infrequent histology of the gynecological cancers and endometrium is the most common site of these tumors. Carcinosarcoma of the fallopian tube are so rare that it has been recommended that each case be reported.^{2,3} Only 82 cases of carcinosarcoma of the fallopian tube had been reported in the world literature.⁴ Hence, data about the optimal management of these cases is limited. Here we present a case of primary carcinosarcoma of the right fallopian tube in a Turkish woman after an informed consent was obtained.

CASE REPORT

A 55-years old postmenopausal, para 2, Turkish woman was referred to our clinic with pelvic pain. Patient had a history of breast cancer and she was operated 7 years ago. Adjuvant radiotherapy and chemotherapy were also given. No significant familial history was noted. A solid mass in size of 5cm on the right adnexa was determined by the transvaginal ultrasonography. Abdominopelvic magnetic resonance imaging (MRI) was administered and no further findings were reported. While CA125 was 79 U/mL, CEA, CA19-9 and CA 15-3 were normal. Physical examination, mammography and ultrasonography of the contralateral breast were normal. Colonoscopy and gastroendoscopy were reported as normal, also. Upon these findings, laparotomy was performed. Upon exploration, right tube was observed to be

swollen and it was in the form of a completely infiltrated mass. Uterus, bilateral ovaries, left tube, peritoneal surfaces, omentum and upper abdomen were normal. Total abdominal hysterectomy, bilateral salpingo-oophorectomy, bilateral pelvic para-aortic lymphadenectomy and omentectomy were performed. Frozen section and final pathology result were reported as carcinosarcoma of the tube, stage 1c (spontaneous rupture of the infiltrated tube was observed) (Figures 1 a,b). Six cycle of paclitaxel-carboplatin chemotherapy was administered to the patient. Patient is tumor-free after one year of the operation.

DISCUSSION

MMMTs are rare malignancies which composed from a mixture of malignant epithelial and stromal components. Whereas, endometrium is reported as the most usual site for these tumors, fallopian tube is accepted as the least common primary place for them.⁵ To our knowledge, 82 cases of MMT of the fallopian tube were reported in the world literature, previously.⁴ Given its rarity and location, the definitive diagnosis is difficult and generally remains uncertain until the intra- or postoperative histological examinations. Ovarian tumor is the ordinarily preoperative diagnosis.^{1,6} Carcinosarcomas of the fallopian tube usually occur in the postmenopausal patients. Mean age of the reported cases was 59.7 years.^{2,4} This average of age was younger than cases of MMT of the endometrium

and older than cases of adenocarcinoma of the fallopian tube.⁶ Our patient was 55 years old. In general, patients admit with atypical vaginal bleeding, abdominal or pelvic pain, distension and mass, while patients with advanced disease may have various symptoms due to the metastatic lesions.⁴

Similar to the ovarian carcinoma, cytoreductive surgery and platinum-based chemotherapy are the nowadays-recommended approach for the carcinosarcomas of the fallopian tube.⁴ Pelvic radiotherapy is also an adjuvant treatment option, solely or in a combination with chemotherapy.^{1,3} The surgical procedure should include a thorough exploration of all peritoneal surfaces, collection of washings and/or ascites, hysterectomy, bilateral salpingo-oophorectomy, omentectomy, pelvic paraaortic lymph node sampling or dissection and peritoneal biopsies as necessary. As in the fallopian tube and ovarian carcinomas, maximal cytoreduction should be emphasized.^{5,7}

Various adjuvant chemotherapies have been reported and the combination of cyclophosphamide, doxorubicin, and cisplatin regimen was the most frequently used.⁵ Overall survival of patients with MMT of the fallopian tube was found to be 16.1 months, in one review, and this survival time was similar to that estimated for the malignant mixed Müllerian tumors of the ovary.^{6,8} Consequently, carcinosarcomas are highly aggressive tumors and despite all these therapies, their prognosis are still fairly poor. Hence, it was deemed necessary

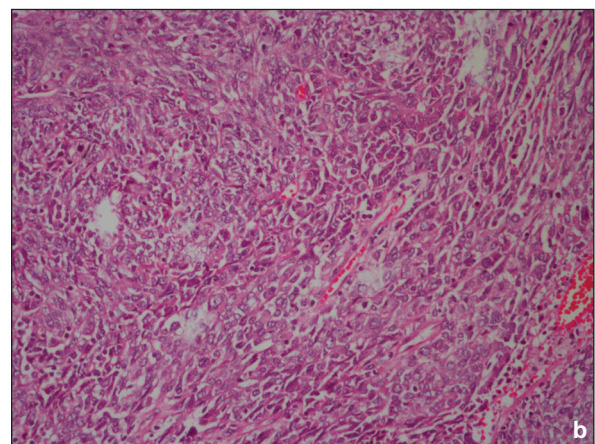
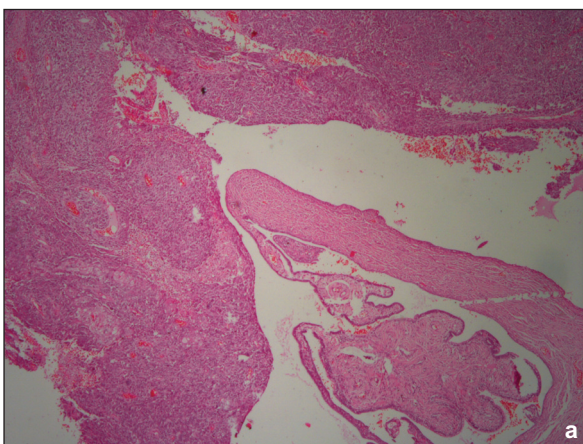


FIGURE 1 a,b: The fallopian tube was completely filled with mesenchymal and epithelial components of malignant mixed Müllerian tumor a) (HE, x40) b) (HE, x400).

to practice new treatment regimens to improve the survival time. Tsai et al. reported a case of stage III malignant mixed Müllerian tumor of the fallopian tube with 5-year survival after optimal debulking and adjuvant chemotherapy with paclitaxel plus carboplatin.⁵ Kawaguchi and co-workers noted that three courses of paclitaxel and carboplatin therapy achieved 60% shrink of a measurable tumor in a patient with FIGO stage IIIc MMMT of the fallopian tube, and the patient was alive/free of disease 28 months after the debulking surgery.⁹ Our patient was also treated with 6 cycle adjuvant paclitaxel plus carboplatin after surgery, and she was tumor-free after one year of the operation.

In conclusion, due to rarity of the carcinosarcomas of the fallopian tube, information about the best treatment strategies are limited. However, maximal cytoreduction followed by platinum based adjuvant chemotherapy with or without radiotherapy seems to be an appropriate treatment option. Furthermore, a promising adjuvant chemotherapeutic combination of paclitaxel and carboplatin may improve the survival time of these cases.

Source of Finance

During this study, no financial or spiritual support was received neither from any pharmaceutical company that has a direct connection with the research subject, nor from a company that provides or produces medical instruments and materials which may negatively affect the evaluation process of this study.

Conflict of Interest

No conflicts of interest between the authors and / or family members of the scientific and medical committee members or members of the potential conflicts of interest, counseling, expertise, working conditions, share holding and similar situations in any firm.

Authorship Contributions

Idea/Concept: Ganim Khatib, Mehmet Ali Vardar, Semra Paydaş; **Design:** Ganim Khatib, Cenk Soysal; **Control/Supervision:** Ahmet Barış Güzel, Ümran Küçüköz Güleç, Mehmet Ali Vardar, Semra Paydaş; **Data Collection and/or Processing:** Ganim Khatib, Cenk Soysal, Emine Bağır; **Analysis and/or Interpretation:** Ganim Khatib, Ahmet Barış Güzel, Ümran Küçüköz Güleç, Emine Bağır; **Literature Review:** Ganim Khatib, Cenk Soysal; **Writing the Article:** Ganim Khatib; **Critical Review:** Ganim Khatib, Mehmet Ali Vardar; **References and Fundings:** Ganim Khatib, Ümran Küçüköz Güleç; **Materials:** Ganim Khatib, Cenk Soysal.

REFERENCES

- Shen YM, Xie YP, Xu L, Yang KX, Yu N, Yu Y, et al. Malignant mixed müllerian tumor of the fallopian tube: report of two cases and review of literature. *Arch Gynecol Obstet* 2010; 281(6):1023-8.
- Gupta R, Jenison EL. A rare case of carcinosarcoma of the fallopian tube presenting with torsion, rupture and hemoperitoneum. *Gynecol Oncol Case Rep* 2011;2(1):4-5.
- Carlson JA Jr, Ackerman BL, Wheeler JE. Malignant mixed müllerian tumor of the fallopian tube. *Cancer* 1993;71(1):187-92.
- Ji J, Zuo P, Li L, Wang Y. Primary malignant mixed Müllerian tumor of the fallopian tube after subtotal hysterectomy: a case report and literature review. *Arch Gynecol Obstet* 2015;291(5):1187-90.
- Tsai CP, Ho ES, Ke YM, Hsu ST, Wang RC, Lu CH. Stage III malignant mixed Müllerian tumor of the fallopian tube: a case of 5-year survival after optimal debulking and adjuvant chemotherapy with paclitaxel plus carboplatin. *Taiwan J Obstet Gynecol* 2012;51(2):294-6.
- Imachi M, Tsukamoto N, Shigematsu T, Watanabe T, Uehira K, Amada S, et al. Malignant mixed Müllerian tumor of the fallopian tube: report of two cases and review of literature. *Gynecol Oncol* 1992;47(1):114-24.
- Schink JC, Lurain JR. Rare gynecologic malignancies. *Curr Opin Obstet Gynecol* 1991; 3(1):78-90.
- Mok JE, Kim YM, Jung MH, Kim KR, Kim DY, Kim JH, et al. Malignant mixed müllerian tumors of the ovary: experience with cytoreductive surgery and platinum-based combination chemotherapy. *Int J Gynecol Cancer* 2006;16(1):101-5.
- Kawaguchi W, Itamochi H, Kigawa J, Kanamori Y, Oishi T, Shimada M, et al. Chemotherapy consisting of paclitaxel and carboplatin benefits a patient with malignant mixed müllerian tumor of the fallopian tube. *Int J Clin Oncol* 2008;13(5):461-3.