

Orf Infection with Multiple Lesions in the Burn Area

Yanık Bölgesinde Çoklu Lezyonlarla Seyreden Orf Enfeksiyonu

^{1b} Selami ARSLAN^a, ^{1b} Nihal ALTUNIŞIK^a, ^{1b} Dursun TÜRKMEN^a, ^{1b} Serpil ŞENER^a,
^{1b} Mücahit MARSAK^a, ^{1b} Suat SEZER^b, ^{1b} Serhat TOPRAK^c

^aDepartment of Dermatology, İnönü University Faculty of Medicine, Malatya, Türkiye

^bClinic of Dermatology, Batman Training and Research Hospital, Batman, Türkiye

^cDepartment of Medical Pathology, İnönü University Faculty of Medicine, Malatya, Türkiye

ABSTRACT Orf, a viral zoonotic disease, is transmitted to humans from small ruminants such as sheep or goats. It usually progresses with one or more nodular lesions appearing on the dorsal surface of the fingers. Orf disease may sometimes present differently from its typical location and clinical presentation. Here, we present 2 orf cases that occurred after burns. Both patients' family members had a history of contact with sheep and goats. The diagnosis of orf was based on clinical findings, a history of animal contact, and exclusion of differential diagnoses. In both cases, the lesions healed with mild hyperpigmentation.

ÖZET Viral zoonotik bir hastalık olan orf, insanlara koyun veya keçi gibi küçükbaş hayvanlardan bulaşır. Genellikle parmakların dorsal yüzünde ortaya çıkan bir veya birden fazla nodüler lezyonla seyreder. Orf hastalığı bazen tipik yerleşim yerinden ve klinik görünümünden farklı şekilde karşımıza çıkabilir. Burada, yanık sonrasında oluşan 2 orf olgusu sizlere sunulmaktadır. Her iki hastanın da küçükbaş hayvan teması öyküsü vardı. Klinik bulgular, hayvan teması öyküsünün olması ve ayırıcı tanılarının dışlanması ile orf tanısı koyuldu. Her iki olguda da lezyonlar hafif hiperpigmentasyonla iyileşti.

Keywords: Orf virus; burns; child

Anahtar Kelimeler: Orf virüsü; yanıklar; çocuk

Orf, a viral zoonotic disease, is caused by the orf virus, an epitheliotropic DNA virus from the parapoxvirus group.¹ It is caused by direct or indirect contact of decontaminated skin with infected animals. The incubation period is 3-15 days, and it usually progresses with one or more nodular lesions that appear on the dorsal surface of the fingers. The disease usually heals spontaneously after a course of 4-8 weeks.²⁻⁵ Here, we present two pediatric patients with orf, unlike the classical localization, occurred in the burn area and progressed with multiple lesions.

CASE REPORTS

CASE 1

A two-year-old male patient had a second degree burn due to hot water on the right side of his scalp,

face and neck 10 days ago. In his dermatological examination, numerous red papules, plaques and vegetative masses were found on an erythematous and intensely edematous surface in the area extending from the right frontal region of the scalp to the occipital region (Figure 1A). Herpes simplex virus (HSV), Varicella-Zoster virus (VZV) polymerase chain reaction (PCR) and skin punch biopsy were taken from the lesions of the patient whose family was engaged in ovine breeding. Since eczema herpeticum was in the differential diagnosis and some of the lesions had a secondary infected appearance, acyclovir and ampicillin sulbactam treatments were started. As the HSV and VZV PCR results were negative, acyclovir treatment was discontinued, but ampicillin sulbactam treatment was continued for one week. Histopathological examination of the case re-

Correspondence: Nihal ALTUNIŞIK

Department of Dermatology, İnönü University Faculty of Medicine, Malatya, Türkiye

E-mail: ngold2001@yahoo.com

Peer review under responsibility of Türkiye Klinikleri Journal of Dermatology.

Received: 05 Jan 2022

Received in revised form: 06 May 2022

Accepted: 06 May 2022

Available online: 12 May 2022

2146-9016 / Copyright © 2022 by Türkiye Klinikleri. This is an open access article under the CC BY-NC-ND license (<http://creativecommons.org/licenses/by-nc-nd/4.0/>).



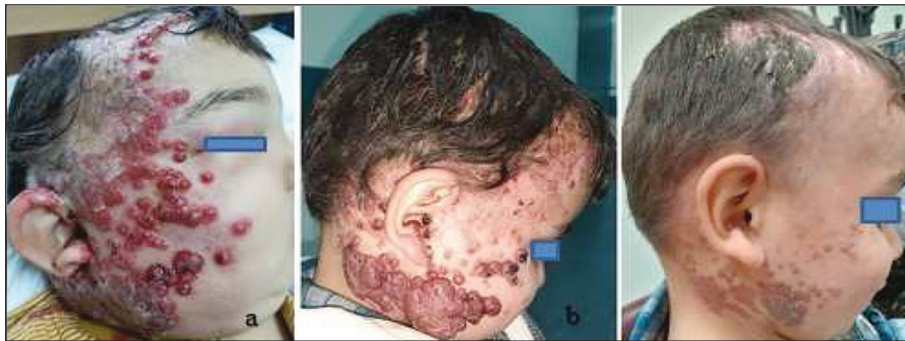

FIGURE 1: Image of Case 1 at presentation; **A)** Multiple red papules, plaques and vegetative masses on an erythematous and edematous surface in the area extending from the right frontal region of the scalp to the occipital region; **B)** The patient's appearance after ten days; **C)** The patient's appearance after three weeks.

vealed pseudoepithelial hyperplasia in the epidermis, edema in the dermis, edema in the keratinocytes, and cytoplasmic eosinophilic inclusions in some cells (Figure 2). There was edema in the right eye of the patient at the time of admission. In the following days, edema around the right eye increased and the left eye was closed due to edema. Systemic steroid therapy was started for this severe edema. After three days of systemic prednisolone treatment, edema regressed significantly. At the end of one week, the patient was discharged. Orf infection was considered clinically and histopathologically. By the end of three weeks, the lesions were almost completely healed (Figure 1B, Figure 1C).

CASE 2

A two-year-old female patient was admitted to the burn unit due to hot water burn and was consulted to us because of lesions in the burn area in the third week of her hospitalization. In her dermatological examination, she had second degree burns and multiple red papulonodular lesions varying between 1-2 cm in diameter at the burn sites (Figure 3). There was no additional disease in the history of the patient whose family was engaged in animal husbandry. Laboratory values were normal. Skin punch biopsy was taken from the lesions and follow-up with antibiotic cream was recommended. Histopathological examination revealed ulcers, parakeratosis, spongiosis and rare apoptotic keratinocytes in the epidermis; in the dermis, edema and moderate lymphoplasmocytic infiltration were observed in the upper parts. Although there were no typical findings in favor of orf in the

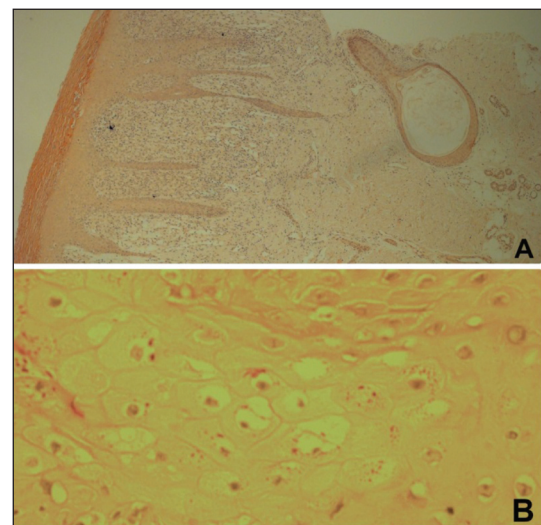


FIGURE 2: Histopathology of Case 1; **A)** Pseudoepitheliomatous hyperplasia of the epidermis, edema of the dermis (H&E, x4); **B)** Edema in keratinocytes, cytoplasmic eosinophilic inclusions in some cells (H&E, x40).

histopathological examination, it was reported that orf disease could be included among the differential diagnosis according to the clinical correlation. The patient, whose lesions healed in eight weeks, was diagnosed as orf clinically and histopathologically.

Informed consent form was obtained from their parents.

DISCUSSION

A detailed anamnesis and clinical examination are usually sufficient for the diagnosis, but viral cell culture, PCR, serological tests or histopathological examinations may be useful in atypical cases.⁶ In orf cases after burns, intact skin without burns is pre-

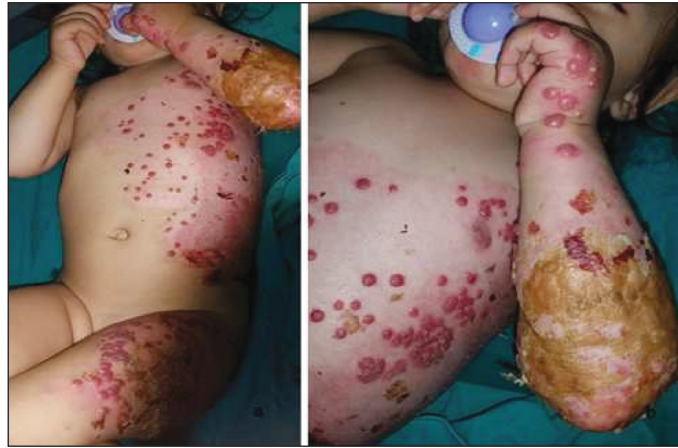

FIGURE 3: The clinical appearance of Case 2 at presentation; **A)** Multiple red papulonodular lesions varying between 1-2 cm on the burn scar on the trunk and extremities; **B)** Close view of lesions.

served, and wounds begin to epithelialize in areas of not very deep burns. Lesions begin to form in the second or third weeks. Parapoxvirus infections are usually self-limited; however, burn patients are at a unique risk for complicated orf virus infections due to the breakdown of the epidermal barrier. The recently defined concept of the “Immunocompromised cutaneous district” is vulnerable sites for the development of neoplasms, infections, and dysimmune reactions. Similar to herpetic infection, ionizing or ultraviolet radiation, chronic lymph stasis, vaccination, tattooing, neural disease, the affected skin area becomes immunocompromised cutaneous district site after burns.⁷ However, lesions can also be observed in graft donor areas in burn patients.^{8,9} While lesions in the graft donor area were detected in more isolated numbers, lesions were detected in the burn area equally and widely.⁹ This explains the more widespread orf infection in the burn area and the suppression of local immunity in the burn area. Vascular endothelial growth factor (VEGF) plays an important role in the pathogenesis of orf by providing capillary proliferation and epidermal regeneration. By providing both viral replication and crust formation, it causes transmission through these crusts.¹⁰ Upregulation of VEGF at the burn site may be another reason why lesions are more extensive and severe.

Burn patients are at high risk for orf, and transmission can occur through direct contact or fomites. In both of our cases, it was understood that the patients had direct contact with animals. Sometimes

there may be no history of contact. Fomites have been proven to cause transmission among patients in an intensive care unit.⁸ In this respect, it is extremely important that healthcare personnel pay attention to disinfection and sterilization conditions in burn patients who are at significant risk.

Histopathological examination reveals a marked edema in the dermis, vascular proliferation, pseudoepitheliomatous hyperplasia in the epidermis, acanthosis, ballooning of cells in the stratum spinosum at high magnification, intracytoplasmic and intranuclear inclusion bodies.^{4,11} Proinflammatory cytokines such as tumor necrosis factor-alpha, interferon- γ , interleukin (IL)-6, and IL-10 play a role.¹¹ Treatment is symptomatic and directed towards complications. It usually heals within 6-8 weeks with post-inflammatory pigmentation changes.

Cases of orf developed after burns have been reported in the literature.^{8,9,11-13} In these cases, similar to our cases, red-colored, vascular-appearing papulonodules and vegetative masses were detected in the burn sites. In the histories of these cases, it was stated that there was transmission through direct animal contact or fomites. In both of our cases, the patients had a history of direct contact with animals. In the literature, it has been reported in cases confirmed by PCR as well as histopathological findings. Since PCR was not available in our cases, it could not be studied and this was the missing aspect of our cases. However, clinical appearance similar

to the cases in the literature, a history of animal contact, and supportive histopathological features were also features supporting orf infection, which is rare after burns.

Orf disease with multiple, atypical lesions occurring after burns is a rare clinical picture, and if it is not considered by physicians, it may lead to unnecessary and aggressive treatment and investigations. For diagnosis, animal contact should be questioned in the history, but not every patient may have a history of animal contact. If the correct diagnosis is made, the patients and their relatives should be told that the lesions will regress and heal completely, as in our case. Orf disease should be considered in burn patients in clinical situations with red-colored papules, nodules, plaques and vegetative masses accompanied by significant edema and oozing in the burn area where intact skin is preserved. Health workers should be warned about this, as it may cause outbreaks in burn units.

Source of Finance

During this study, no financial or spiritual support was received neither from any pharmaceutical company that has a direct connection with the research subject, nor from a company that provides or produces medical instruments and materials which may negatively affect the evaluation process of this study.

Conflict of Interest

No conflicts of interest between the authors and / or family members of the scientific and medical committee members or members of the potential conflicts of interest, counseling, expertise, working conditions, share holding and similar situations in any firm.

Authorship Contributions

Idea/Concept: Selami Arslan, Nihan Altunışık; **Design:** Dursun Türkmen; **Control/Supervision:** Dursun Türkmen, Serpil Şener; **Data Collection and/or Processing:** Selami Arslan, Mücahit Marsak, Suat Sezer, Serhat Toprak; **Analysis and/or Interpretation:** Selami Arslan, Nihal Altunışık; **Literature Review:** Selami Arslan; **Writing the Article:** Selami Arslan; **Critical Review:** Nihal Altunışık; **References and Fundings:** Selami Arslan; **Materials:** Selami Arslan.

REFERENCES

- Büttner M, Rziha HJ. Parapoxviruses: from the lesion to the viral genome. *J Vet Med B Infect Dis Vet Public Health.* 2002;49(1):7-16. [[Crossref](#)] [[PubMed](#)]
- Bayindir Y, Bayraktar M, Karadağ N, Özcan H, Kayabas U, Otu B, et al. Investigation and analysis of a human orf outbreak among people living on the same farm. *New Microbiol.* 2011;34(1):37-43. [[PubMed](#)]
- Uzel M, Sasmaz S, Bakaris S, Cetinus E, Bilgic E, Karaoguz A, et al. A viral infection of the hand commonly seen after the feast of sacrifice: human orf (orf of the hand). *Epidemiol Infect.* 2005;133(4):653-7. [[Crossref](#)] [[PubMed](#)] [[PMC](#)]
- Turan E, Yurt N, Turgut Erdemir A, Gürel MS. Fasiyal orf [Facial orf]. *Turk J Dermatol.* 2012;6:58-60. [[Crossref](#)]
- Turkmen D. A zoonotic lesion which grows with contact; orf. *J Turgut Ozal Med Cent.* 2018;25(1):159-60. [[Crossref](#)]
- Bayhan Gİ, Tanır G, Gürkan A. Bir çocuk olguda orf hastalığı [Orf disease in a child]. *Turkish Journal of Pediatric Disease.* 2015;4:271-4. [[Link](#)]
- Caccavale S, Kannangara AP, Ruocco E. Categorization of and comments on isomorphic and isotopic skin reactions. *Clin Dermatol.* 2017;35(1):105-10. [[Crossref](#)] [[PubMed](#)]
- Midilli K, Erkiş A, Kuşkuç M, Anay H, Erkiş S, Benzonana N, et al. Nosocomial outbreak of disseminated orf infection in a burn unit, Gaziantep, Turkey, October to December 2012. *Euro Surveill.* 2013;18(11):20425. Erratum in: *Euro Surveill.* 2013;18(14):20442. [[Crossref](#)] [[PubMed](#)]
- Hsu CH, Rokni GR, Aghazadeh N, Brinster N, Li Y, Muehlenbachs A, et al. Unique presentation of orf virus infection in a thermal-burn patient after receiving an autologous skin graft. *J Infect Dis.* 2016;214(8):1171-4. [[Crossref](#)] [[PubMed](#)] [[PMC](#)]
- Baj J, Korona-Głowniak I, Buszewicz G, Forma A, Sitarz M, Teresiński G. Viral infections in burn patients: a state-of-the-art review. *Viruses.* 2020;12(11):1315. [[Crossref](#)] [[PubMed](#)] [[PMC](#)]
- Aşiran Serdar Z, Yaşar Ş, Demirkesen C, Aktaş Karabay E. Poxvirus-induced vascular angiogenesis mimicking pyogenic granuloma. *Am J Dermatopathol.* 2018;40(9):e126-e9. [[Crossref](#)] [[PubMed](#)]
- Alinejad F, Momeni M, Keyvani H, Faramarzi S, Mahboubi O, Rahbar H. Introduction to a case of orf disease in a burn wound at Motahari Hospital. *Ann Burns Fire Disasters.* 2018;31(3):243-5. [[PubMed](#)] [[PMC](#)]
- Biyik Ozkaya D, Taskin B, Tas B, Asiran Serdar Z, Demirkesen C, Su O, et al. Poxvirus-induced angiogenesis after a thermal burn. *J Dermatol.* 2014;41(9):830-3. [[Crossref](#)] [[PubMed](#)]